

Oral medicine

أ.م.د احسان عبد الله كميل

Pigmented lesions of the Oral cavity

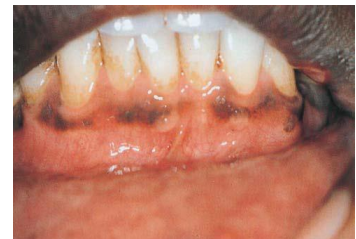Pigmented oral lesions are a large group of disorders in which the dark or brown color is the essential clinical characteristic. Usually, the dark color of the lesions is due to melanin production by either melanocytes or nevus cells. In addition, exogenous deposits and pigment-producing bacteria can also produce pigmented lesions. Benign disorders, deposits, benign and malignant neoplasms, and systemic diseases are included in the group of pigmented lesions.

- O Normal pigmentation
- O Amalgam tattoo
- O Heavy-metal deposition
- O Drug-induced pigmentation
- O Smoker's melanosis
- O Black hairy tongue
- O Ephelis
- O Lentigo
- O Lentigo maligna
- O Pigmented nevi
- O Melanoma
- O Addison disease
- O Peutz–Jeghers syndrome

Normal Pigmentation (Racial)

Definition and etiology Increased melanin production and deposition in the oral mucosa may often be a physiological finding, particularly in dark-skinned individuals.

Clinical features This type of pigmentation is persistent and symmetrical, and clinically presents as asymptomatic black or brown areas of varying size. The gingiva are most commonly affected, followed by the buccal mucosa, palate, and lips. The



pigmentation is more prominent in areas of pressure or friction, and usually becomes more intense with increasing age.

Laboratory tests Histopathological examination.

Treatment No treatment is required.

Amalgam Tattoo

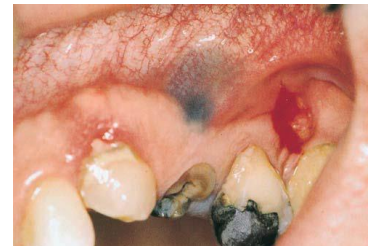Definition Amalgam deposition (tattoo) is a common oral disorder.

Etiology Implantation of dental amalgam into the oral mucosa.

Clinical features The condition presents as a well-defined irregular or diffuse flat area, with a bluish-black discoloration of varying size. The most common sites of involvement are the gingiva, alveolar mucosa, and buccal mucosa. The diagnosis is usually made at the clinical level.

Laboratory tests Histopathological examination and radiographs.

Treatment No treatment is required.

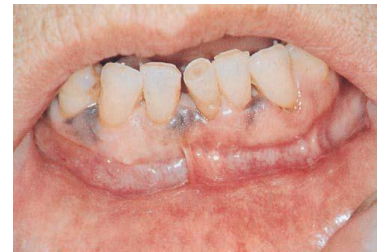

Heavy-Metal Deposition

Definition and etiology Heavy-metal deposition is a rare oral condition caused by ingestion or exposure to bismuth, lead, silver, mercury, and other heavy metals.

Clinical features Clinically, the most common pattern (bismuth, lead) is a bluish line along the marginal gingiva, or similar spots within the gingival papillae. Rarely, diffuse bluish-black discoloration may be seen (silver). The diagnosis is based on the history and the clinical features.

Treatment No treatment is required for oral lesions.



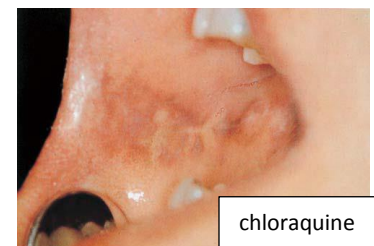Drug-Induced Pigmentation

Definition Drug-induced oral pigmentation is a relatively common condition, caused by increased melanin production or drug metabolite deposition.

Etiology Antimalarials, tranquilizers, minocycline, azidothymidine, ketoconazole, phenolphthalein, and others are the most common drugs that induce pigmentation.

Clinical features The clinical picture varies, and the condition may appear as irregular brown or black macules or plaques, or diffuse melanosis. The buccal mucosa, tongue, palate, and gingiva are the most commonly affected sites. The diagnosis is made on the basis of the history and clinical criteria.

Treatment No treatment is required.

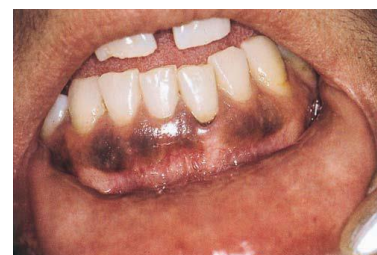

Smoker's Melanosis

Definition Smoker's melanosis, or smoking-associated melanosis, is a benign abnormal melanin pigmentation of the oral mucosa.

Etiology Tobacco smoke that stimulates melanocytes.

Clinical features Clinically, it appears as multiple brown pigmented areas, usually located on the anterior labial gingiva of the mandible. Pigmentation of the buccal mucosa and palate has

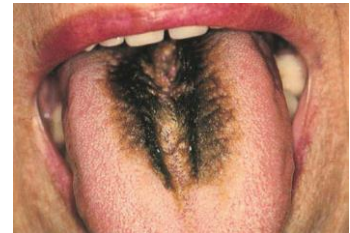

been associated with pipe smoking. The intensity of pigmentation is related to time and dose. Women are more commonly affected.

Treatment No treatment is required. Cessation of smoking is usually associated with a return of normal mucosal pigmentation.

Black Hairy Tongue

Hairy tongue may occasionally appear black as a result of the growth of pigment-producing bacteria that colonize the elongated filiform papillae. In addition, the black color may also be due to staining from food and tobacco. The diagnosis is made on the basis of clinical criteria.



Ephelis

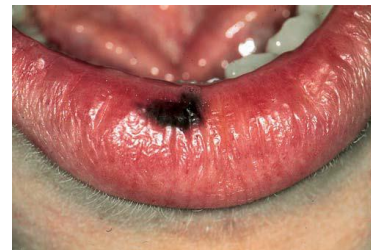Definition Ephelides, or freckles, are discrete brown macules, commonly seen on sun-exposed skin and rarely in the mouth.

Etiology Unknown. They are due to increased melanin production.

Clinical features Clinically, the lesions appear as solitary and well demarcated asymptomatic round brown macules, less than 5 mm in diameter. The vermillion border of the lower lip is the most common site of development.

Laboratory tests Histopathological examination.

Treatment No treatment is required, except for aesthetic or diagnostic considerations.



Lentigo

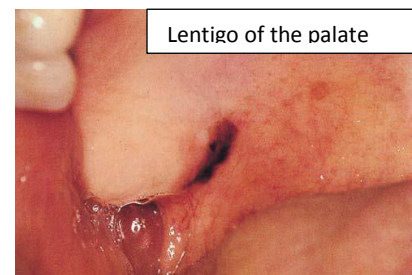
Definition Lentigo is a rare oral disorder of pigmentation.

Etiology Increased number of epidermal melanocytes.

Clinical features The condition presents as small round flat spots, brown or dark brown in color, usually less than 0.5 cm in diameter. It is a rare lesion intraorally.

Laboratory tests Histopathological examination.

Treatment No treatment is required.



Lentigo Maligna

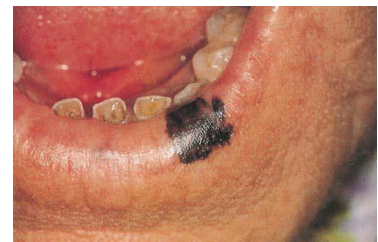Definition Lentigo maligna, or Hutchinson's freckle, is a premalignant lesion of melanocytes that probably represents in-situ melanoma.

Etiology Unknown.

Clinical features Lentigo maligna is very rare intraorally. Clinically, it appears as a slowly expanding black or brown plaque, with irregular borders. In 5–15 years, it ultimately progresses into invasive melanoma. The lips, buccal mucosa, palate, and floor of the mouth are the common sites affected.

Laboratory tests Histopathological examination.

Treatment Surgical excision, radiotherapy.

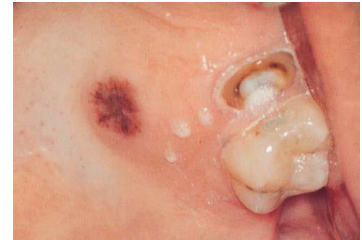

Pigmented Nevi

Definition Pigmented cellular nevi are benign malformations of melanocytes and “nevus cells,” common in the skin and rare in the oral mucosa.

Etiology Developmental. Melanocytes and nevus cells of neural crest origin.

Clinical features Based on histological criteria, oral pigmented nevi are classified into four types: intramucosal, junctional, compound, and blue. Clinically, the lesion appears as an asymptomatic, well-demarcated, flat or slightly elevated, brown, black, or blue spot or plaque. The lesion is usually solitary, with a diameter of less than 1 cm. The palate, gingiva, buccal mucosa, and lips are the sites of predilection.



Laboratory tests Histopathological examination.

Treatment Usually, no treatment is required. Conservative surgical excision is carried out in some cases.

Melanoma

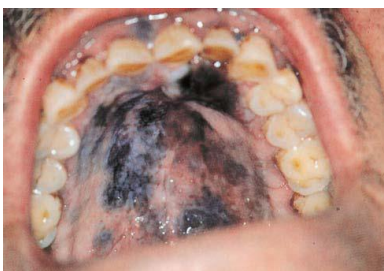Definition Melanoma is a malignant neoplasm originating either de novo from melanocytes, or from a benign melanocytic lesion.

Etiology Unknown. Ultraviolet radiation is an important causative factor for skin melanoma.

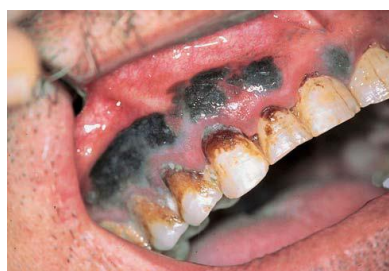Clinical features Primary oral melanoma is uncommon, representing 0.5–1.5% of melanomas. Clinically, it presents as a black or brown macule, plaque, or nodule that may be ulcerated. The lesions are usually characterized by an irregular margin and a tendency to spread. Based on clinical and histopathological criteria, oral melanoma is classified into three forms: lentigo maligna melanoma (best prognosis), superficial spreading melanoma (good prognosis), and nodular melanoma (poor prognosis). The palate, upper gingiva, and alveolar mucosa are most commonly affected.

Laboratory tests Histopathological examination

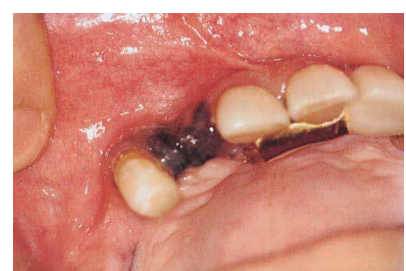Treatment Surgical excision with 3 centimeters margin to avoid recurrence, radiotherapy, chemotherapy.



Extensive melanoma of the palate



nodular melanoma of maxilla
(alveolar mucosa)



early nodular melanoma of
alveolar mucosa

Addison Disease

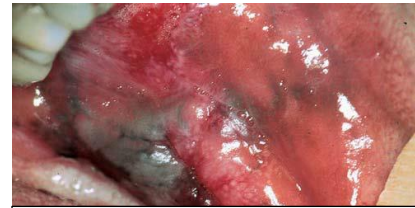Definition Addison disease is a relatively uncommon insufficiency of adrenal corticosteroid hormones.

Etiology Adrenal cortex destruction, usually caused by autoimmunity, infections, tumors, amyloidosis.

Clinical features The oral manifestations are common and early, and present as diffuse or patchy dark brown pigmentation, due to melanin production. The buccal mucosa, palate, lips, and gingiva are the most common sites of involvement.

Laboratory tests Measurement of plasma adrenocorticotrophic hormone (ACTH) and serum cortisol levels.

Treatment Steroid replacement.



Addison disease: diffuse pigmentation of the buccal mucosa

Peutz-Jeghers Syndrome

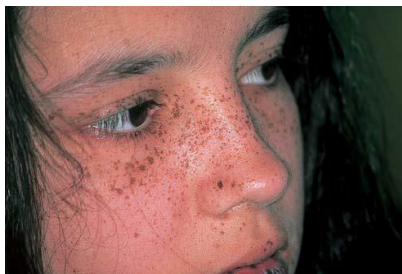Definition Peutz-Jeghers syndrome is a rare genetically transmitted disorder, characterized by mucocutaneous pigmentation and intestinal polyposis.

Etiology Inherited as an autosomal dominant trait.

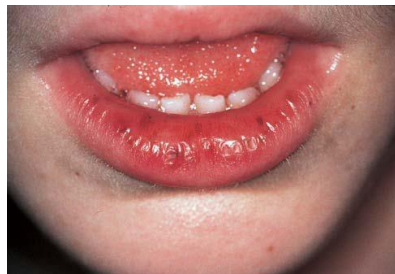Clinical features The oral manifestations are the most important diagnostic findings, and consist of oval or round, brown or black macules or spots, 1–10 mm in diameter. The perioral skin, lips, buccal mucosa, and tongue are the most common sites affected. The skin lesions consist of numerous, usually perioral, dark spots. Intestinal polyps (hamartomas) are constant findings, usually in the jejunum and ileum.

Laboratory tests Histopathological examination, radiography of the gastrointestinal tract.

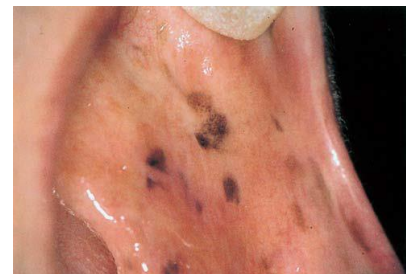Treatment Supportive; surgical intervention in some cases.



Multiple pigmented spots on the skin



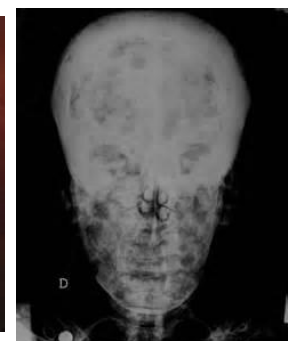
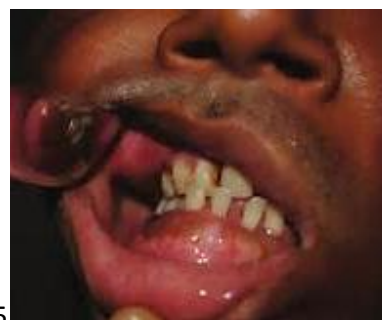multiple round spots on the lower lip



multiple spots on the buccal mucosa

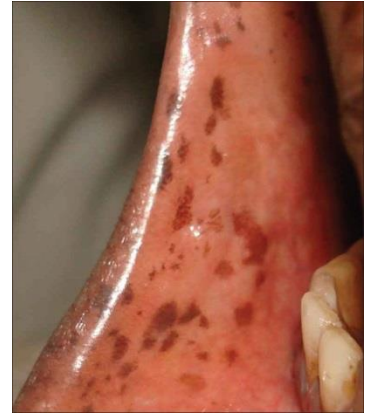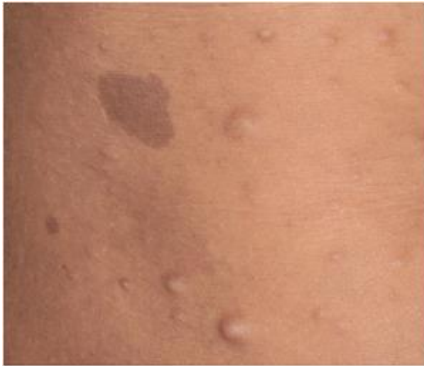Albright syndrome

Fibrous changes in bone marrow results in distortion of bone architecture. X ray shows areas of radiolucency and radioopacity (ground glass or cotton wool), characterized by Precocious puberty (females) and increased melanin pigmentation of buccal and labial mucosa



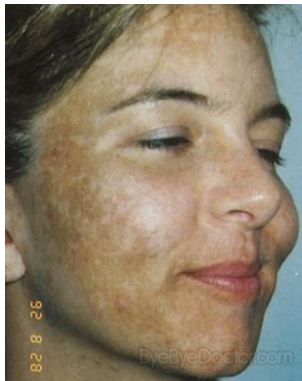Neurofibromatosis

Inherited syndrome consists of Areas of pigmentation on skin (café au lait) and oral mucosa. Sessile or pedunculated tumors of skin and mucous membrane. Tumors of nerves and malignant changes in to neurofibrosarcoma



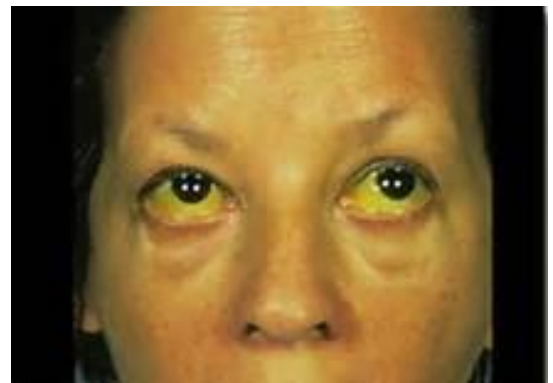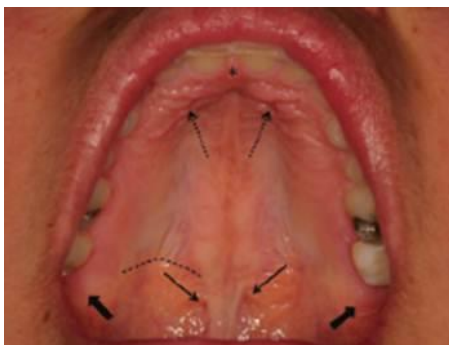Chloasma

Hyper pigmentation of skin around the mouth, on the face and nipples occurs in the 3rd trimester of pregnancy



Bilirubin

Jaundice: yellow pigmentation of skin and oral mucosa due to increased level of bilirubin in blood. The most common site is the junction of hard and soft palate.



Iron

Hemochromatosis: increased iron deposition leads to fibrosis and functional impairment of organs involved (liver disease, DM, heart failure. Pigmentation of oral mucosa could be increased melanin or blue gray color.

