

## Orthodontics

**Orthodontics:** Is that branch of dentistry concerned with facial growth; development of the dentitions and occlusion; diagnosis; interception and treatment of occlusal anomalies. Orthodontics" is derived from the Greek orthos ("correct", "straight") and -odon-(tooth).

According to British society of orthodontics (1922) "Orthodontics includes the study of growth & development of the jaws & face particularly, & the body generally as influencing the position of the teeth; the study of action & reaction of internal & external influences on the development & the prevention & correction of arrested & perverted development.

According to American Board of orthodontics "Orthodontics is that specific area of dental practice that has as its responsibility the study and supervision of the growth and the development of the dentition and its related anatomical structures from birth to dental maturity, including all preventive and corrective procedures of dental irregularities requiring the repositioning of teeth by functional or mechanical means to establish normal occlusion and pleasing facial contours".

In 1911 Noyes defined orthodontics as "The study of the relation of the teeth to the development of the face and correction of arrested and perverted development ".

In 1907 Angle stated that the objective of the science of orthodontics is "The correction of malocclusion of the teeth".

**Aims & objectives of orthodontic treatment:** Aims & objectives of orthodontic treatment have been summarized by Jackson as the Jackson's Triad.

1. Functional Efficiency.
2. Structural Balance.

### 3. Esthetic Harmony.

1. Functional Efficiency Many malocclusions affect normal functioning of the stomatognathic system. The orthodontic treatment should thus aim at improving the functioning of the orofacial apparatus.

2. Structural Balance The oro-facial region consists of the dentoalveolar system, the skeletal tissue and the soft tissue including musculature. Stable orthodontic treatment is best achieved by maintaining a balance between these three tissue systems.

3. Esthetic Harmony By far the most common reason for seeking orthodontic care is to improve the appearance of the teeth & face. Many malocclusions are associated with unsightly appearance of teeth & can thus affect the individual's self-image, wellbeing & success in society. Thus, the orthodontic treatment should aim at improving the esthetics of the individual.

#### ***Orthodontics can improve the following:***

##### 1- Dental health:

*a- Dental caries:* Mal-alignment of the teeth may reduce the potential for natural teeth –cleansing and increase the risk of decay.

*b- Periodontal disease:* Irregular teeth reduce effective brushing, in addition to that, crowding may force one or more teeth to be squeezed buccally or lingually out of their investing bone reducing periodontal support and finally traumatic occlusion may lead to increase loss of periodontal support (e.g.: anterior crossbite).

*c- Trauma to anterior teeth:* Researches have shown that overjet more than 3 mm had more than double the risk of traumatic injury.

*d- Impacted teeth:* Impacted (unerupted) tooth may affect normal position and health of adjacent teeth in addition to the loss of function of the impacted tooth itself.

##### 2- Function:

*a- Masticatory function:* Patients with open bites; markedly increased

overjet (Class II) or reversed overjet (Class III) often complain difficulties with eating, particularly incising food.

*b- Speech:* Crowding may have little effect on normal speech.

*c- Temporo-mandibular joint:* There is no clear association between malocclusion and the TMJ.

3- Psychosocial -wellbeing: Unattractive dento-facial appearance does have a negative effect on expectations of teachers and employers.

***Scope of orthodontic treatment:***

1. Alteration in tooth position.
2. Alteration in skeletal pattern.
3. Alteration in soft tissue pattern.

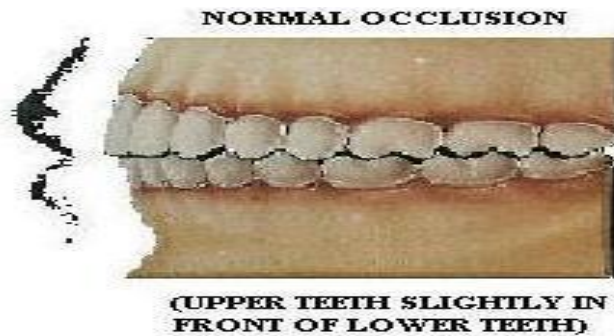***Occlusion:*** Any position or relationship in which the upper and the lower teeth come together.

***Ideal Occlusion:*** A theoretical concept of an ideal arrangement of the teeth within the dental arches, combined with an ideal inter-arch relationship, which concentrates optimal esthetic, function, and stability of the dentition and supporting structures. But it is almost never found in nature.

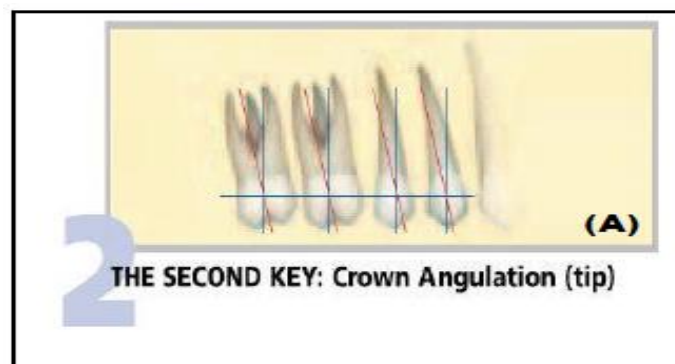
***Normal occlusion:*** That occlusion which satisfies the requirements of function and esthetic but in which there are minor irregularities of individual teeth.

***6 keys of normal occlusion: The Andrews' Six Keys Of Normal Occlusion***

***1:Molar relation:*** The distal surface of the distobuccal cusps of the upper first permanent molar made contact and occluded with the mesial surface of the mesiobuccal cusps of the lower second molar , the mesiobuccal cusp of the upper first permanent molar fell within the groove between the mesial and middle cusps of the lower first permanent molar. (The canines and premolars enjoyed a cusp- embrasure relationship ).



2: *Crown angulation* "The mesiodistal tip" The term angulation refers to angulation (or tip) of the long axis of the crown not to angulation of the long axis of the entire tooth. The gingival portion of the long axis of each crown was distal to the incisal portion varying with the individual tooth type, the long axis of the crown for all teeth except molars is identified to be the mid developmental of ridge which is the most prominent part and center most vertical portion of the labial or buccal surface of the crown. The long axis of the molar crown is identified by the dominant vertical groove on the buccal surface of the crown.



3: *Crown inclination* (Labiolingual or buccolingual inclination):

Crown inclination refers to the labiolingual or buccolingual inclination of the long axis of the crown not to the inclination of the long axis of entire tooth. The inclination of all the crowns has a consistent scheme:-

**a- Anterior teeth** (Central and lateral incisors)

The labial inclination of upper and lower anterior crown is sufficient to resist over eruption of anterior teeth and sufficient also to allow proper distal positioning of the contact points of the upper teeth in their relationship to the lower teeth, permitting proper occlusion of the posterior teeth.

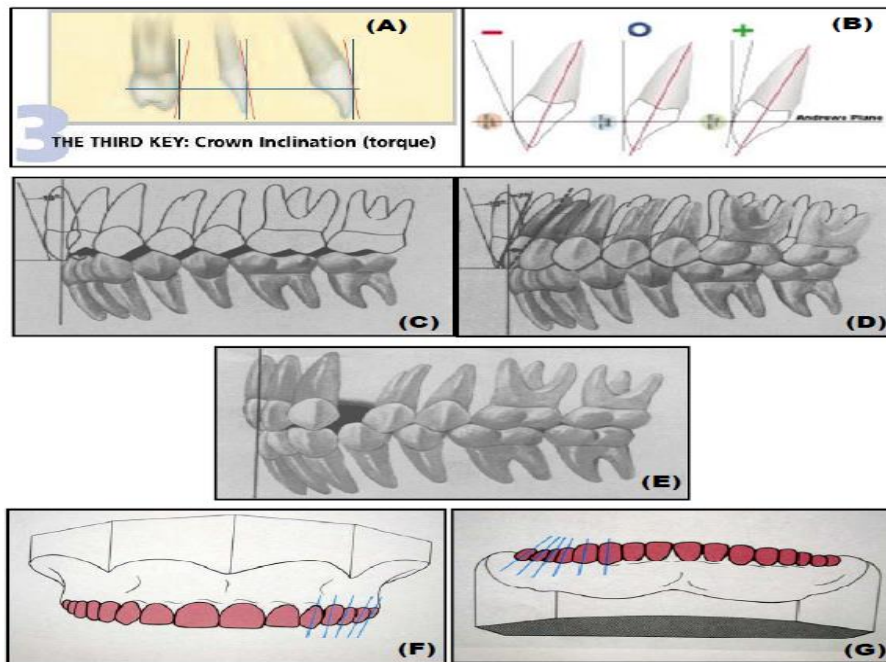
**b-Upper posterior teeth** (Canines through molars)



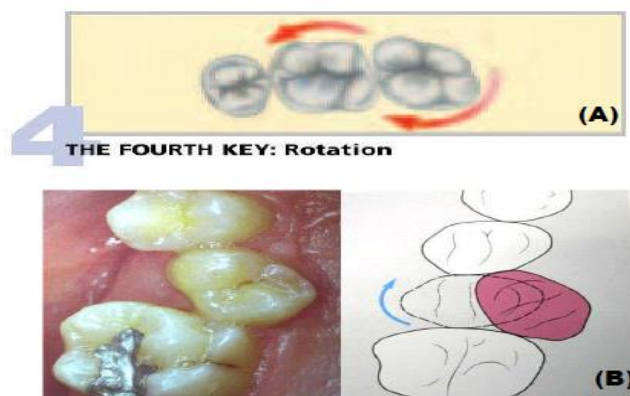
A lingual crown inclination existed in the upper posterior crown was a constant and similar from the canines through the second premolar and was slightly more pronounced in the molars.

**c-Lower posterior teeth** (Canines through molars)

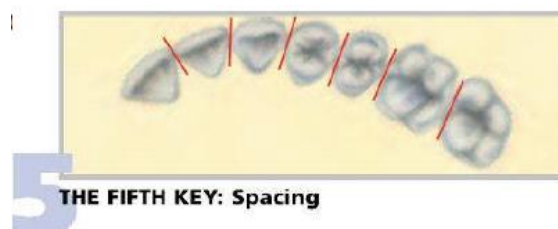
The lingual crown inclination in the lower posterior teeth progressively increases from the canine through the second molar.



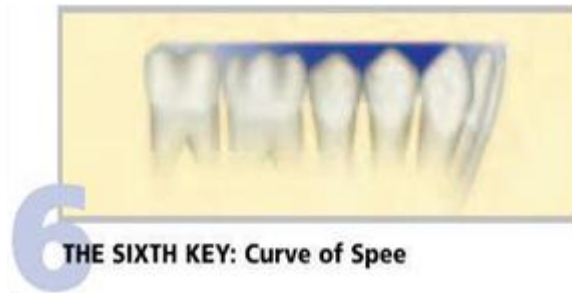
4: *Rotation*: There are no undesirable rotations. Rotated molar and bicuspid occupy more space than normal while rotated incisors occupies



5: *Spaces*: there were no spaces with tight contact point.



6: *Occlusal planes*: the plane of occlusion varied from generally flat to a slight curve of spee (which measured from most prominent cusp of lower second molar to the lower central incisor), no curve deeper than 1.5 mm is accepted from a stand point of occlusal stability.



Recently the authors believe that the correct crown diameter represents the seventh key to normal occlusion this key (the seventh key) had to be present in Andrews non orthodontic normal study models.

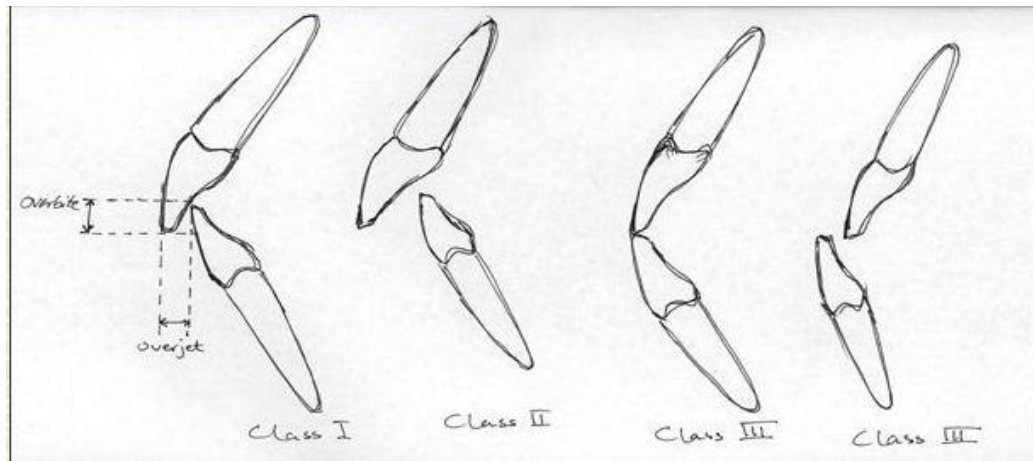
**Malocclusion:-** Defined as any deviation from the normal or ideal occlusion.

***Risks of orthodontic treatments:***

- 1- Root resorption: During 2- years of fixed orthodontic treatment it is inevitable to find 1 mm of root resorption, however the use of excessive orthodontic force may lead to un-accepted amount of root resorption and hence devitalization of affected tooth or teeth.
- 2- Loss of periodontal support: Caused by poor oral hygiene during orthodontic treatment.
- 3- Demineralisation: May occur during fixed orthodontic treatment specially, as a result of plaque accumulations in case of uncooperative patient (poor oral hygiene).
- 4- Soft tissue damage: Traumatic ulceration may occur specially in fixed orthodontic treatment.
- 5- Pulpal injury: Excessive orthodontic force may lead to pulp injury and death especially for the teeth with a history of trauma.

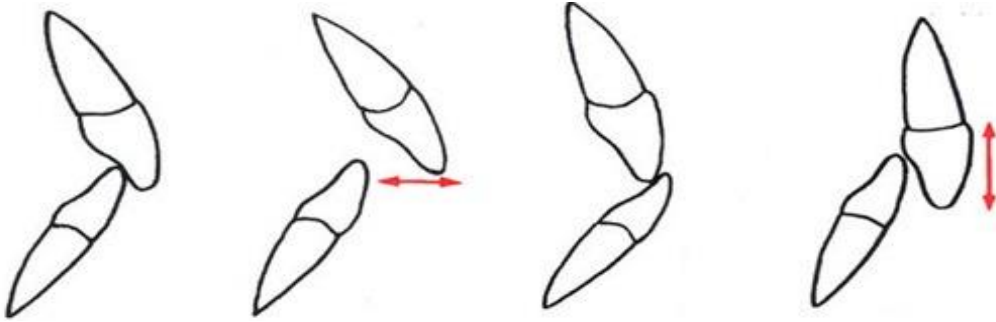
**Orthodontic definitions:**

**Incisal overjet:** The overjet is the horizontal distance between the upper and lower incisors in occlusion, measured at the tip of the upper incisor. It is dependent on the inclination of the incisor teeth and the antero-posterior relationship of the dental arches. In most people there is a positive overjet, i.e. the upper incisor is in front of the lower incisor in occlusion (normally 2-4 mm), but the overjet may be reversed (in case of Class III), or edge-to-edge.



Incisal overjet: (a) The ideal overjet relationship, (b) increased overjet (c) Edge to edge incisal position, (d) Reversed overjet.

**Incisal overbite:** The overbite is the vertical distance between the tips of the upper and lower incisors in occlusion. It is governed by the degree of vertical development of the anterior dento-alveolar segments. Ideally, the lower incisors contact the middle third of the palatal surface of the upper incisors in occlusion (2-4 mm), but there may be excessive overbite (deepbite), or there may be no incisal contact, in which case the overbite is described as *incomplete* when the lower incisors are above the level of the upper incisal edges, or *anterior open bite*, when the lower incisors are below the level of the upper incisal edges in occlusion.

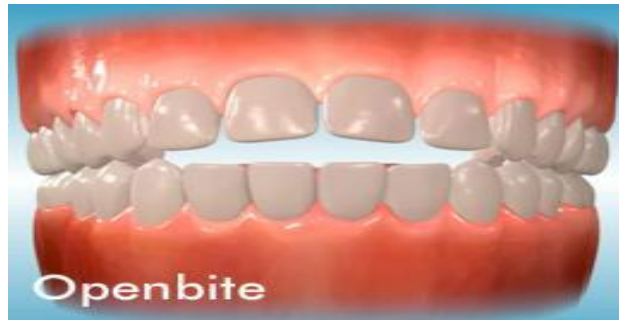

Incisal overbite: (a) The ideal overbite relationship, (b) decreased overbite (c) deep bite.

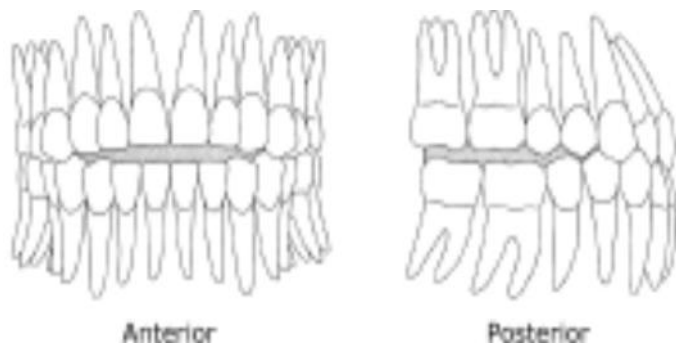
*My great wishes for my lovely students for success. Thanks*

## Orthodontics

**Open bite (Negative overbite):-** Inherited, developmental or acquired malocclusion whereby no vertical overlap exists between maxillary and mandibular anterior teeth (anterior open bite), or no vertical contact is exhibited between maxillary and mandibular posterior teeth (posterior open bite). Subdivided to:

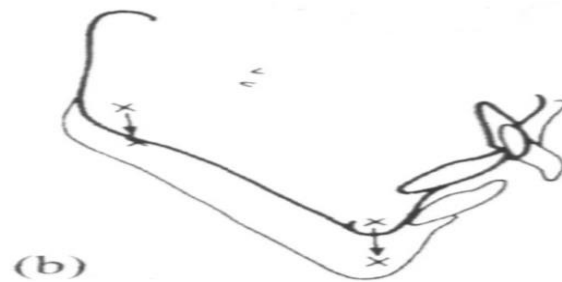

1- Dental open bite: A localized openbite that involves only a few teeth due to a digit-sucking habit or other local factors.



Anterior and posterior dental openbite

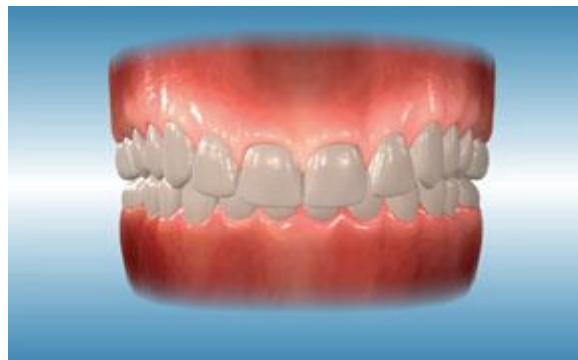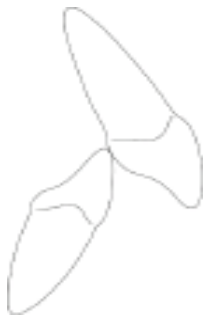2- Skeletal open bite: Caused by divergence of the skeletal mandibular or / and maxillary planes leading to increased facial height as in case of posterior rotational growth of the mandible.



Posterior rotational growth of the mandible

**Deep bite (Excessive overbite):** Type of malocclusion in which the vertical overlap of the anterior teeth is increased beyond the ideal relationship {more than the normal range which is 2-4 mm}; it is frequently associated with decreased vertical facial dimensions, subdivided into;

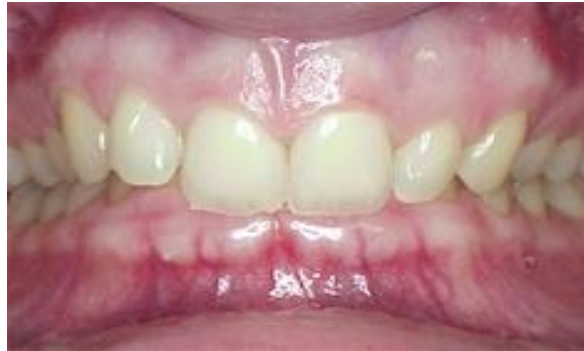1- None traumatic deepbite : In which the deepbite still associated with teeth -teeth relation.



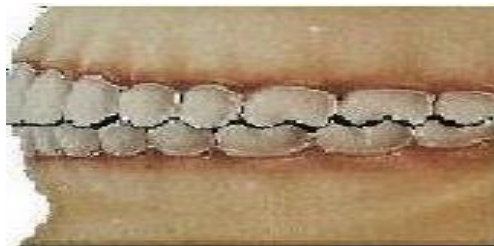
2-Traumatic deepbite: in which the deepbite associated with the Impingement of the mandibular incisors in the mucosa palatal to the maxillary incisors commonly is seen in malocclusions with extremely deep bite as in sever Class II malocclusion.

3-Bi-traumatic deepbite: usually seen in some Class II, Division 2 malocclusions with minimal overjet, the retroclined maxillary incisors may impinge in the keratinized tissue labial to the mandibular incisors,

causing gingival recession at the same time there is a trauma to palatal mucosa caused by lower incisors.



***Buccal overjet:*** The distance between the buccal surfaces of the maxillary posterior teeth and the buccal surfaces of their mandibular antagonists. An unofficial term sometimes used to indicate whether or not there is a tendency for a posterior crossbite.



***Crossbite:-*** An abnormal relationship of one or more teeth to one or more teeth of the opposing arch, in the buccolingual or labiolingual direction. A crossbite can be dental or skeletal in etiology. The appropriate type of crossbite can be specified by identifying the teeth or jaws that deviate the most from their ideal position (e.g. when a cross bite is mainly due to a narrow maxillary arch the correct term is "maxillary posterior lingual crossbite" as opposed to "mandibular posterior buccal crossbite" which indicates wider mandibular arch).

### ***Classification of crossbite:***

Based on Location

#### **1. ANTERIOR CROSS BITE:**



- According to no. of teeth involved:

A. Single tooth Cross bite.      B. Segmental Cross bite.

## 2. POSTERIOR CROSS BITE:

- According to no. of teeth involved:

A. Single tooth Cross bite.      B. Segmental Cross bite.

- According to side involved:

A. Unilateral.      B. Bilateral.

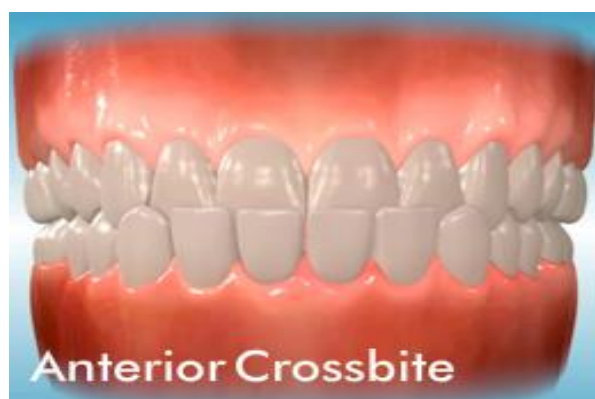
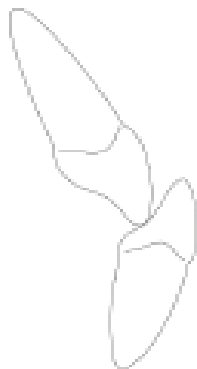- According to extent:

A. Single posture Cross bite.      B. Buccal Non-occlusion (Scissor bite).  
C. Lingual Non-occlusion (Buccal crossbite).

Based on the Etiologic Factor

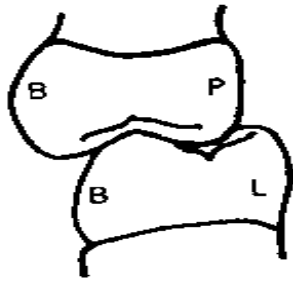
1. Skeletal crossbite.
2. Dental crossbite.
3. Functional crossbite.

**Anterior crossbite:** If the one or more of the lower incisors are in front of the upper incisors, the condition is called reverse overjet or anterior crossbite.

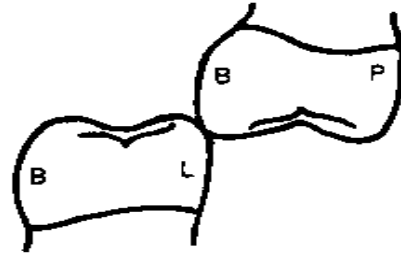




**Buccal crossbite** : A cross bite due to buccal displacement of the affected posterior tooth (or group of teeth) from its (their) ideal position relative to to its (their) antagonist(s). Subdivided into:



Normal



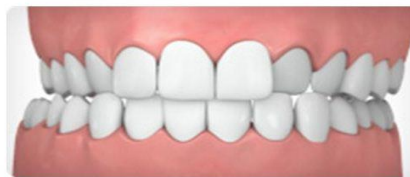
posterior crossbite

1- Unilateral posterior: Affect only one side of the dental arch, and can be either:

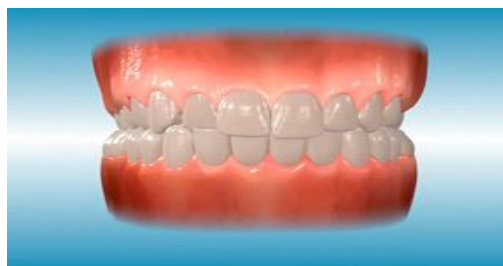a- True unilateral posterior crossbite: Caused by the asymmetry present in the dental arch and usually does not associated with deviation of the mandible.

b- False unilateral posterior crossbite: caused by narrowing of the maxilla or widening of the mandible leading to cusp -cusp relation then the patient try to get maximum intercuspation by deviation of the mandible to one side leading to unilateral crossbite.

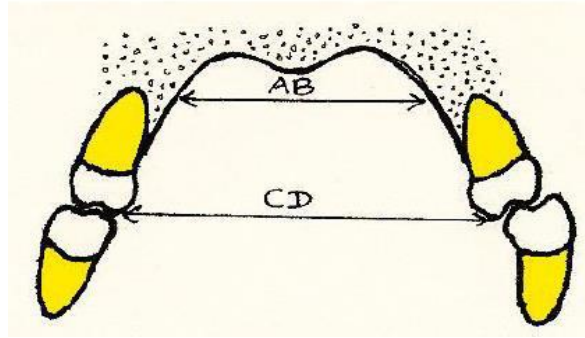
Unilateral Posterior Crossbite - only on one side.



2- Bilateral posterior crossbite: Caused by sever maxillary collapse or/ and mandibular widening, there is no mandibular deviation during closure.

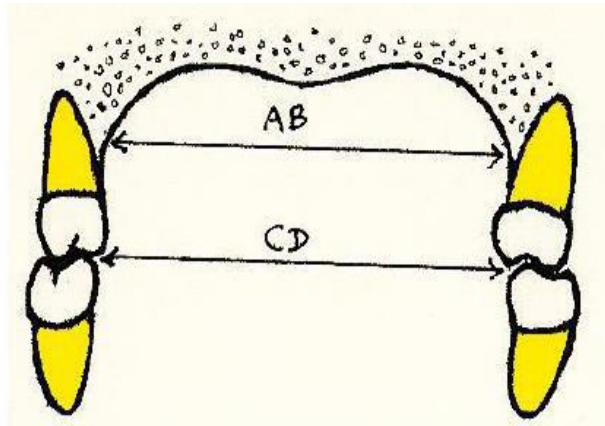


**Skeletal crossbite:** It is a crossbite with a skeletal basis (constricted maxilla and/or wide mandible).



*Palatal arch width (AB) is inadequate and quite less than dental arch width (CD)*

**Dental crossbite:** It is caused by distortion of the dental arch where the jaws are of normal proportions.

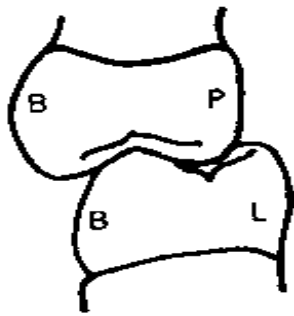


Palatal arch width (AB) is adequate and nearly equal to dental arch width (CD)

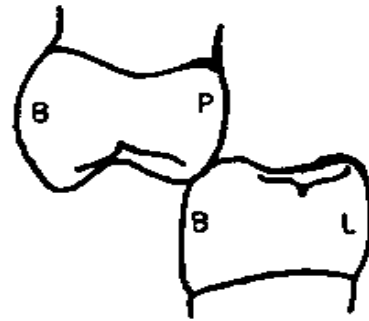
**Functional crossbite (False):** It is a crossbite due to a functional shift of the mandible, it should be treated early if recognized, because if uncorrected, true crossbite may result by modification of growth.

**Scissors-bite:** Situation in which several adjacent posterior teeth overlap vertically in habitual occlusion with their antagonists, without contact of their occlusal surfaces. The deviation of the affected teeth from their ideal position could occur either in maxillary buccal or mandibular lingual

direction, where mandibular dentition are completely contained within the maxillary dentition in habitual occlusion.



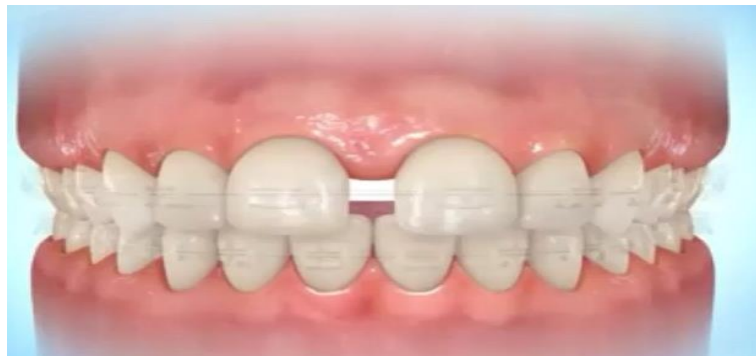Normal



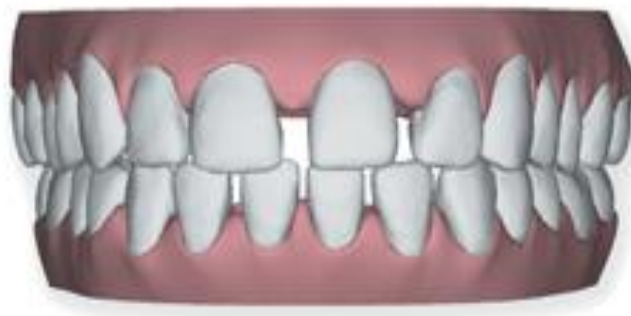scissors-bite

**Spacing of the dentition:** A dental arch with spacing of more than accepted range ( 2 mm or more), it is either:

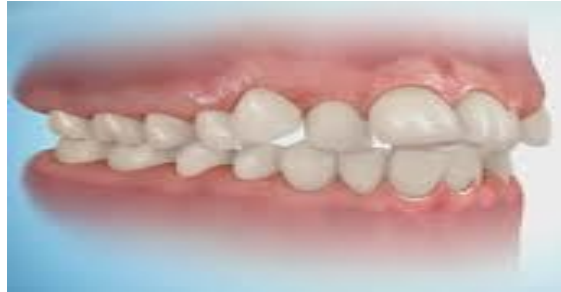a- Localized: Localized in one position like median Diasthema that caused by abnormal frenal attachment.



b- Generalized :Affect the whole dental arch mostly caused by abnormal soft tissue function tongue thrust.



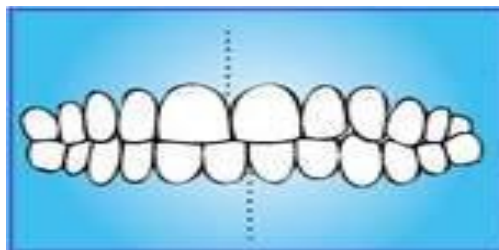
***Crowding of the dentition:*** A dental arch with crowding of more than accepted range (2 mm or more), either caused by local factor like early extraction of deciduous teeth or general factor like collapsed maxillary arch that lead to crowding of the whole arch.



***Imbrication:*** The overlapping of incisors and canines in the same arch, usually due to crowding.

***Midline shift(deviation):-*** occur when the upper and lower dental midline are not coincide and subdivided into:

- 1- Associated with mandibular deviation during closure as in case of premature occlusal contact.
- 2- Not associated with mandibular deviation during closure as in caes of unilateral missing of the teeth or crowding.

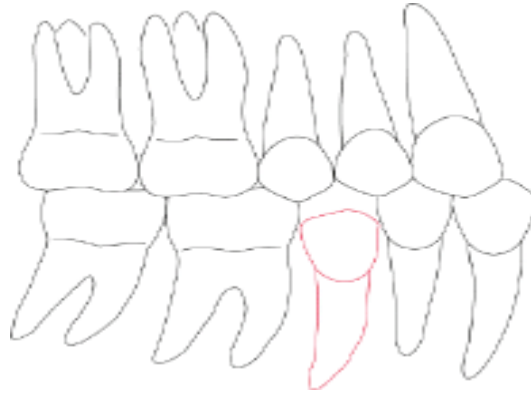

Midline shift may be due to shift of upper or lower teeth or some time may both of them and it is very important to determine that during diagnosis and treatment planning specially to choose a tooth or teeth to be extracted, in addition to that it is important to differentiate between midline shift of the dentition and the face because we may see one of them or some time both of them.

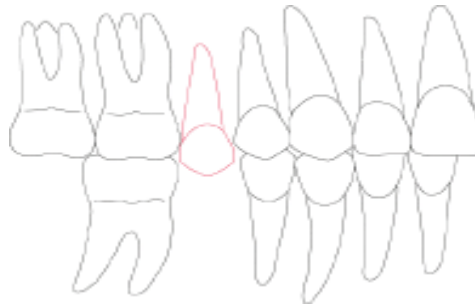Midline shift of the face mostly caused by abnormal skeletal factor (like unilateral hyperplasia of the mandible) or deviation of the nose.

Midline shift of the dentition mostly associated with unilateral extraction or congenital missing or impaction of a tooth.

***Infra position (Infraocclusion):*** A situation in which a tooth or group of teeth is positioned below the occlusal plane; commonly due to a deleterious habit or to ankylosis.



***Overeruption (Supraeruption, Supraposition, Supraocclusio):*** The situation whereby an unopposed or non-occluding tooth extends beyond the occlusal plane.



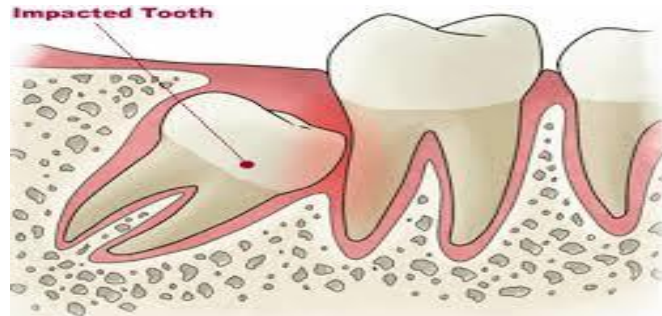***Dental retrusion:*** posterior position of a tooth or group of teeth but keeping their long axis with normal inclination.

***Dental retroclination:*** posterior positioning of a tooth or group of teeth but their long axis are tipped labio-lingually .(Note: A tooth can be retrusive without being retroclined, if it is positioned too far posteriorly but has a normal inclination.)

***Dental protrusion:*** anterior positioning of a tooth or group of teeth but keeping their long axis with normal inclination.

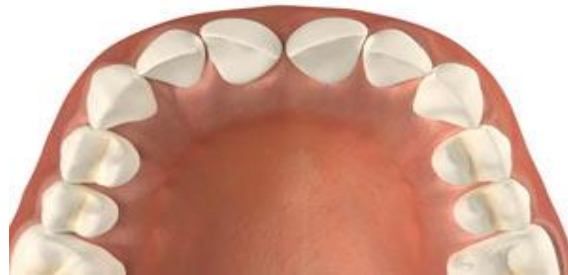***Dental proclination:*** anterior positioning of a tooth or group of teeth but their long axis are tipped labially.

***Impaction of teeth***: occurs when eruption is completely blocked by other teeth due to crowding, it tends to affect the last teeth to erupt in each segment (as in case of canine).



***Rotation of teeth***: a type of malocclusion in which there is a rotation of a tooth about its long axis, most evident when viewing the tooth from an occlusal perspective mostly, caused by crowding and sub divided into:

- 1- Mild (less than 90°): Can be treated easily by removable orthodontic appliance using couple force system.
- 2- Sever (more than 90°): Must be treated by Fixed orthodontic appliance only.



***Displacement of tooth***: abnormal position of the tooth (crown and root) in the dental arch.

***Overlapping of teeth***: abnormal position of the crown of the tooth in the dental arch while there is normal position of root in the jaw.

***My great wishes for my lovely students for success. Thanks***

# Orthodontics

## *Classification of malocclusion*

### Angle classification

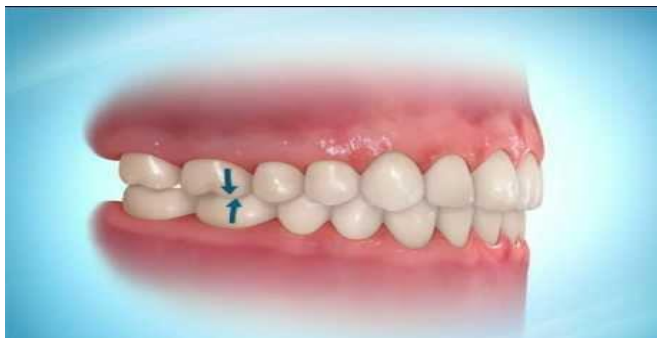A classification of malocclusion introduced by **E. H. Angle**, based on the anteroposterior relationship of the maxillary and mandibular first permanent molars. Angle's assumption when formulating this classification was that the maxillary first permanent molar always is in the physiologically correct position and the variability comes from the mandible.

Angle's classification, which is still widely popular, only can serve as a framework, as it does not take into account many other important relationships in the anteroposterior (e.g. overjet, canine relationship), transverse (e.g. buccolingual crossbites), or vertical (e.g. overbite) planes of space. It also does not identify intra-arch problems, such as crowding, spacing, rotations, missing or impacted teeth.

Angle's classification subdivided into:

#### **• Class I malocclusion (Neutroclusion)**

A malocclusion in which the buccal groove of the mandibular first permanent molar occludes with the mesiobuccal cusp of the maxillary first permanent molar. The term "Class I" is sometimes used incorrectly as a synonym for normal occlusion, although in reality, it only signifies a normal relationship of maxillary. and mandibular first molars in the sagittal plane.



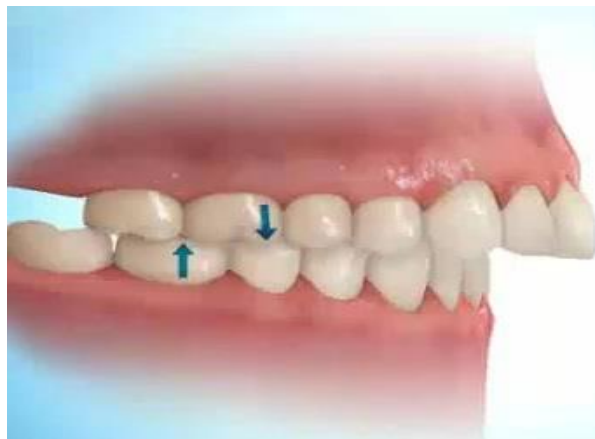

## **Class II malocclusion (Distocclusion, Postnormal occlusion):**

A malocclusion in which the buccal groove of the mandibular first permanent molar occludes posterior (distal by at least half cusp) to the mesiobuccal cusp of the maxillary first permanent molar. The severity of the deviation from the Class I molar relationship usually is indicated in fractions (or multiples) of the mesiodistal width of a premolar crown ("cusp" or "unit"):-

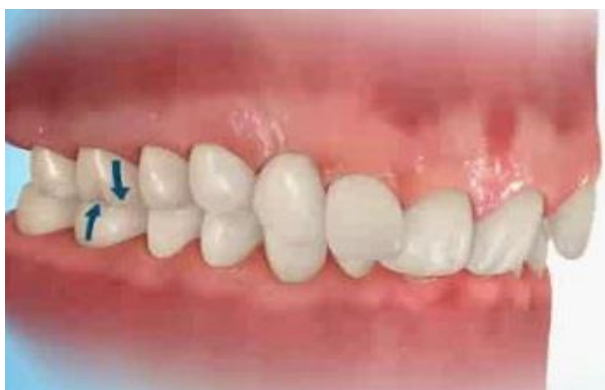### **- Class II malocclusion, Division 1:**

A Class II malocclusion with proclined maxillary incisors, resulting in an increased overjet.



### **- Class II malocclusion, Division 2:**

A Class II malocclusion typically with the maxillary central incisors tipped palatally, a short anterior lower face height, an excessive overbite and decreasing overjet. Three types of Class II Division 2 malocclusion can be distinguished, based on differences in the spatial conditions in the maxillary dental arch:

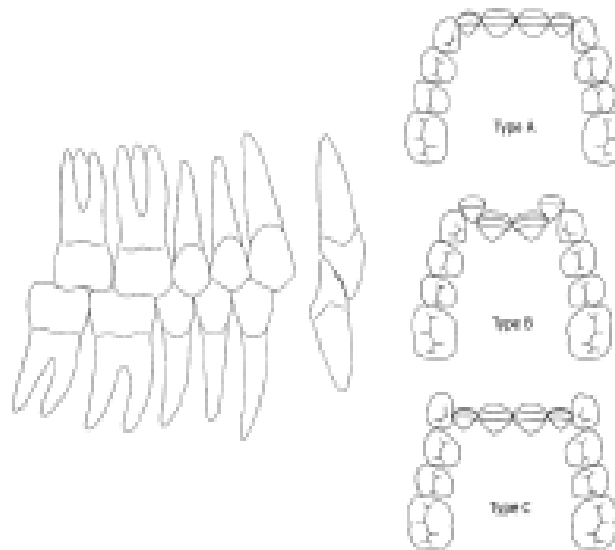




**Type A:** The four maxillary permanent Incisors are tipped palatally, without the occurrence of crowding.

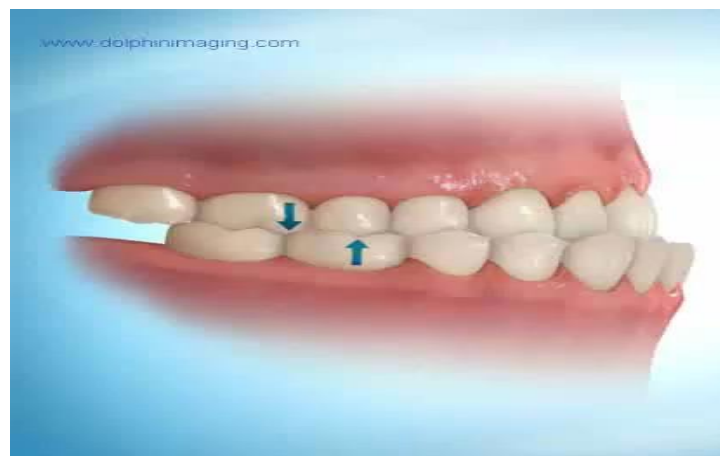**Type B:** The maxillary central incisors are tipped palatally and the maxillary laterals are tipped labially.

**Type C:** The four maxillary permanent incisors are tipped palatally, with the canines labially positioned.



**• Class III malocclusion (Mesioclusion, Prenormal occlusion):**

A malocclusion in which the buccal groove of the mandibular first permanent molar occludes anterior (mesial by at least half cusp) to the mesiobuccal cusp of the maxillary first permanent molar. The same conventions as described above are used to indicate the severity of deviation from a Class I molar relationship.



### **Important notes:**

1-Usually when we talk about angles classification we talk about first permanent molar relation (and some time we notice that this relation not symmetrical in both side).

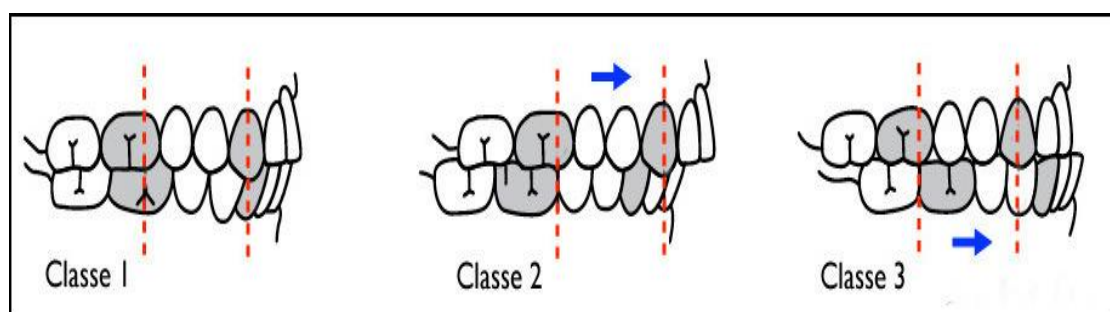
2- When there is missing of the first permanent molar or there is drifting as a result of an early loss of deciduous molars so we shift to another classification which is canine classification .and if there is no canine or impacted canine or severely malposed canine so we shift to another classification which is incisor classification.

### **Canine classification:**

**Class I:** It is a normal canine relation, when the tip of the upper canines located in the embrasure area between lower canine and first premolar (or the mesial slope of the upper canine coincide with the distal slop of lower canine) in occlusion.

**Class II:** Abnormal canine relation in which the lower canine will be more backward from normal canine relation in occlusion.

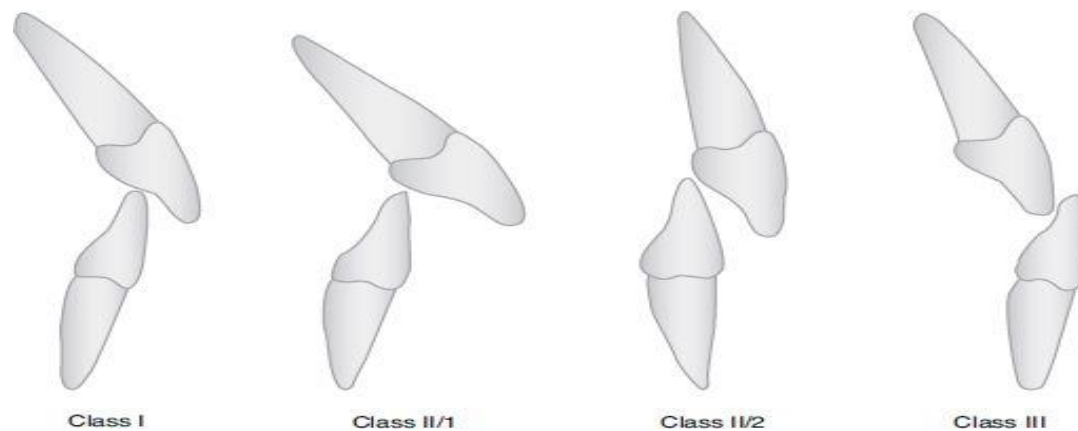
**Class III:** Abnormal canine relation, when the lower canine will be more forward than from normal canine relation.



### **Incisor classification**

The incisor relationship does not always match the buccal segment relationship. Since much of orthodontic treatment is focused on the correction of incisor malrelationships, it is helpful to have a classification of incisor relationships. The terms used are the same but this is not

Angle's classification, although it is a derivation .In clinical practice the incisor classification is usually found to be more useful than Angle's classification.



**Class I.** The lower incisor edges occlude with or lie immediately below the cingulum plateau (middle part of the palatal surface) of the upper central incisors.

**Class II.** The lower incisor edges lie posterior to the cingulum plateau of the upper incisors.

There are two divisions to Class II malocclusion:

**Division 1.** The upper central incisors are proclined or of average inclination, with an increased overjet .

**Division 2.** The upper central incisors are retroclined (less than  $105^{\circ}$  to the maxillary plane). The overjet is usually of an average size but may be increased.

**Class III.** The lower incisor edges lie anterior to the cingulum plateau of the upper incisors . The overjet may be either reduced or reversed.

### **Classification of deciduous teeth:**

Depend on the relation between terminal plane present in the maxillary and mandibular deciduous posterior teeth.

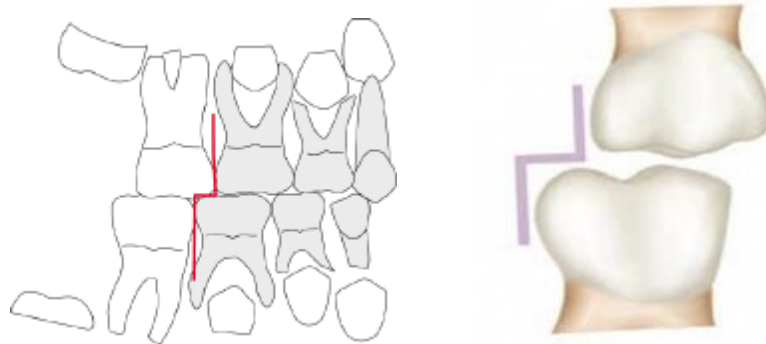
### **Terminal plane:**

The distal proximal surface of the maxillary and mandibular second

deciduous molars (being the distal terminal plane of the deciduous dentition). The relationship between the maxillary and mandibular terminal planes in the early mixed dentition is thought to determine, to a degree, the eventual relationship between the (at the time still unerupted) maxillary and mandibular first permanent molars.

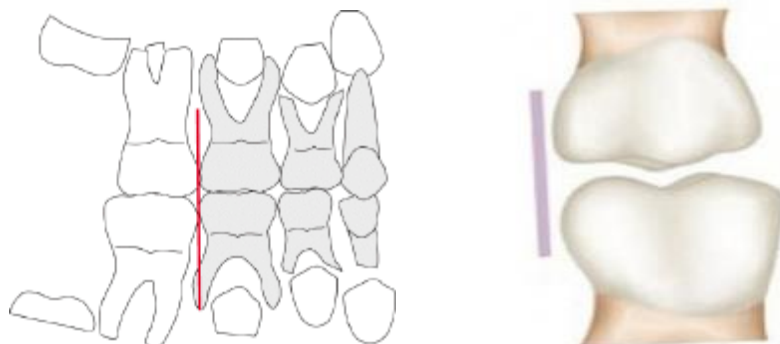
**Distal step:**

A situation in which the terminal plane of the mandibular second deciduous molar is situated posteriorly to that of the maxillary second deciduous molar. This situation is thought to be predisposing to, but not necessarily predictive of, a Class II relationship of the (at the time, still unerupted) first permanent molars .



**Flush terminal plane**

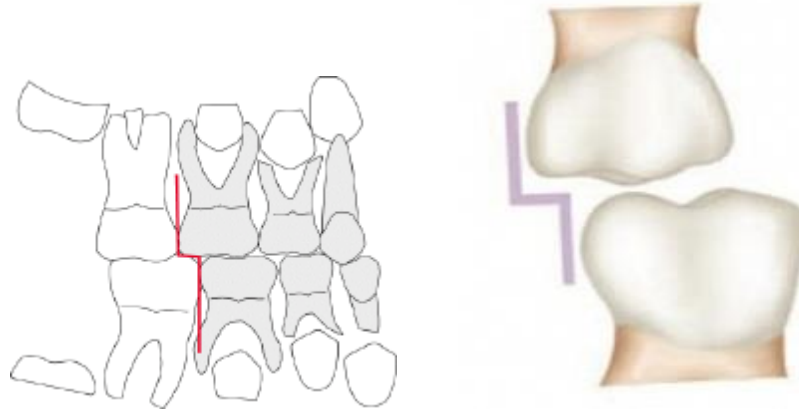
An end-to-end relationship between the distal proximal surfaces of the maxillary and mandibular second deciduous molars, usually leading to a Class I or Class II relationship between the (at the time, still unerupted) maxillary and mandibular first permanent molars.



**Mesial step:**

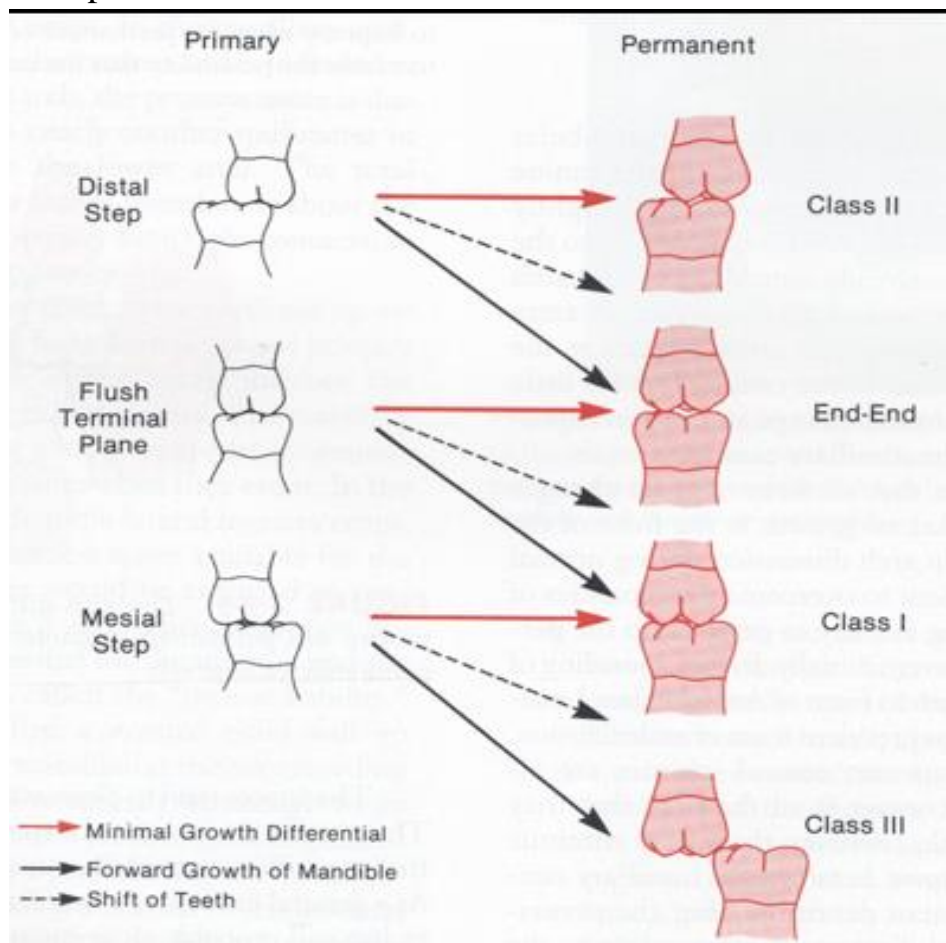
A situation in which the terminal plane of the mandibular second deciduous molar is situated anteriorly to that of the maxillary second

deciduous molar. Depending on the severity of the mesial step, this relationship is thought to predispose to (but is, strictly speaking, not predictive of) either a Class I or a Class III relationship of the (at the time, still unerupted) maxillary and mandibular first permanent molars.



**Clinical implications and variations:**

The first permanent molars may erupt into one of the following occlusal relationships



*My great wishes for my lovely students for success. Thanks*

## Orthodontics

### *Growth and development*

Growth can be defined as an increase in size while development is the increase in complexity.

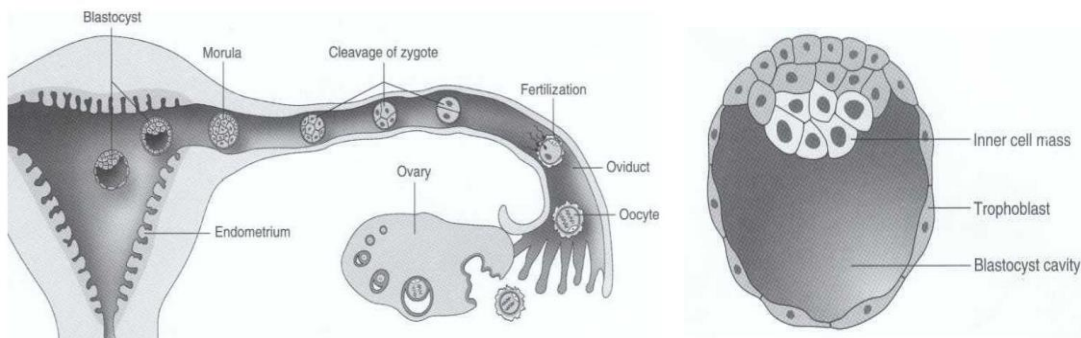
The knowledge about growth and development is very important for orthodontist since during this period any disturbances may give rise to certain congenital malformations, malocclusion and facial deformities ...etc. although the etiology of malocclusion is mainly based on genetic factors.

This category can be divided into two periods: prenatal and postnatal.

*The prenatal (neonatal) period:*

It can be divided into three periods:

**1- period of ovum:** from the time of fertilization to the end of 2<sup>nd</sup> week: in this period human development begins when a sperum fertilize the ocyte resulting in the formation of a zygote. Fertilization occurs in the ampulla of the utrine tube ( oviduct ). The zygote undergo a series of mitotic divisions as it moves along the utrine tube toward the uterus. The cells resulting from this division are called blastomers they adhere to one another and form a ball of cells called a morula, which enters the uterus about three days after fertilization.



A fluid-filled space called the blastocyte cavity develops, within the morula, and the entire structure is called the blastocyst.

Six days after fertilization, two distinct cell types comprise the blastocyst

\*The trophoblast form a single layer of cells covering the outside of the blastocyst.

\*the inner cell mass which is a cluster of cells located inside the



trophoblast

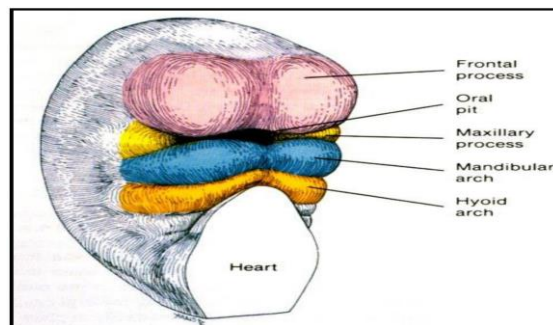
The inner cell mass develops into embryo whereas the trophoblast forms the embryonic part of the placenta and other peripheral structures associated with the embryo.

**2- period of embryo:** from the 2<sup>nd</sup> week to the 8<sup>th</sup> week : in this period most organs and organ systems are formed, it is the period of differentiation and most congenital malformations developed during this period. At the end of this period the developing individual has a recognizable human appearance.

**3- period of fetus:** from the 8<sup>th</sup> week to the 40<sup>th</sup> week

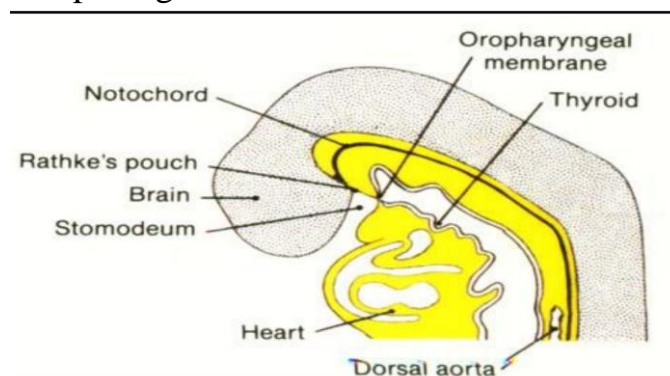
Most of the cranio facial structures are formed in the first trimester of pregnancy.

In the 3<sup>rd</sup> week the head is composed mainly of the pros-encephalon (frontal prominence) which represents the most caudal portion of the pros-encephalon, overhangs the developing oral groove. This oral groove is bounded on its lateral sides by the rudimentary maxillary processes, the mandibular arch is below the groove while the frontal process is above.

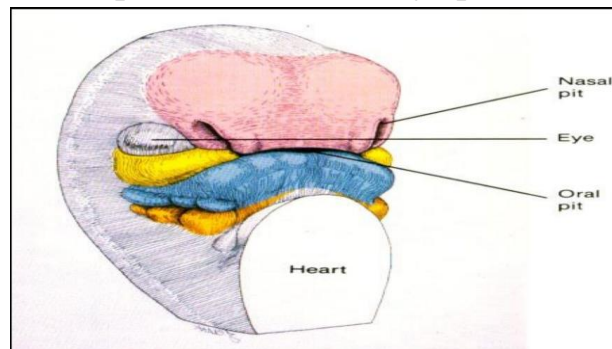


The frontal prominence, mandibular arch and the maxillary processes are called together the stomodeum.

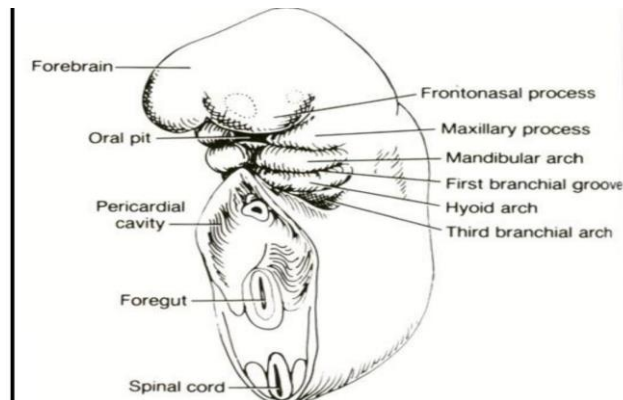
During the following few weeks the oral groove deepens and the oral plate ( bucco pharyngeal membrane ) which consists of an ectodermal floor of the stomodeum and endodermal lining of the foregut, ruptures to establish the oral opening.



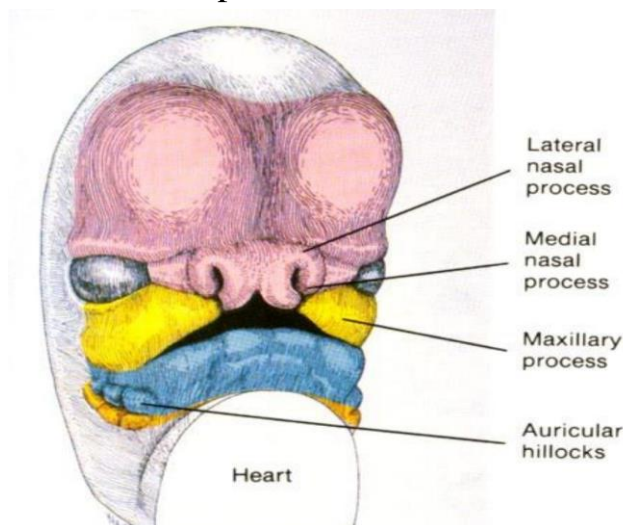
In the 4<sup>th</sup> week we can notice two ectodermal proliferations on either side of the frontal process. These later on will give rise to the nasal placodes, which develop to nasal pits and the olfactory epithelium.



At this time we can also see the brachial arches, which are distinguished as four arches with a fifth transitory brachial arch. The first arch is called the mandibular arch while the second is called the hyoid arch.



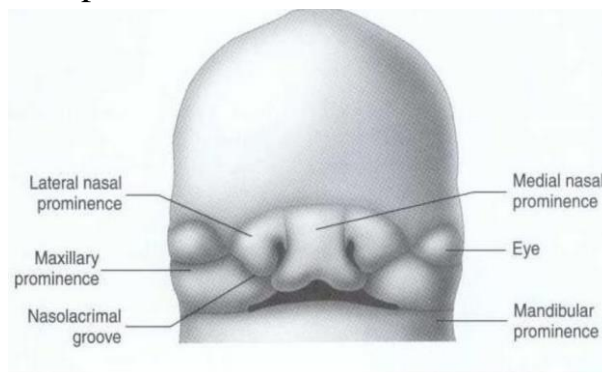
On the 5<sup>th</sup> week the nasal pits widen and the medial and lateral walls of the nasal pits start to proliferate and grows downward giving rise to the medial nasal and lateral nasal processes.





The maxillary processes on either side start to proliferate toward the medial nasal processes and the union between the medial nasal and the maxillary processes give rise to the maxilla, palate, upper lip and the lower central part of the nose.

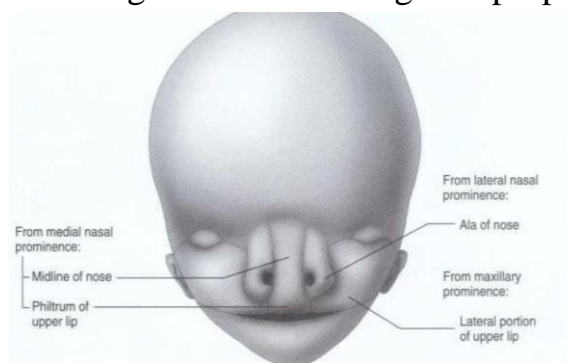
The line of fusion of the the two medial nasal processes is represented by a depression on the upper lip called the philtrum, the fusion of the medial nasal processes and the maxillary processes completes during the 7th week. Cleft lip develops if failure of fusion of these two processes takes place. This cleft may be a unilateral or a bilateral, it is also can be a complete or an incomplete one.



By the 8th week, the facial structures are apparent, the nose is more prominent and the nasal septum elongates and become more narrowed, the eyes migrate toward the midline and the ears begin to develop, the nostrils are formed by an opening in the nasal pit area which communicates with the upper part of the oral cavity.

The nasal septum is forming from the cells of the medial nasal process and of the frontal prominence, the demarcation between the lateral nasal process and the maxillary process creates a furrow, which is converted into the naso-lacrimal duct when it closes over.

By the 12th week the eyelids and nostrils have formed and subsequent intra-uterine changes lead to little further differentiation, these intrauterine changes involve increasing in size and changes in proportions.



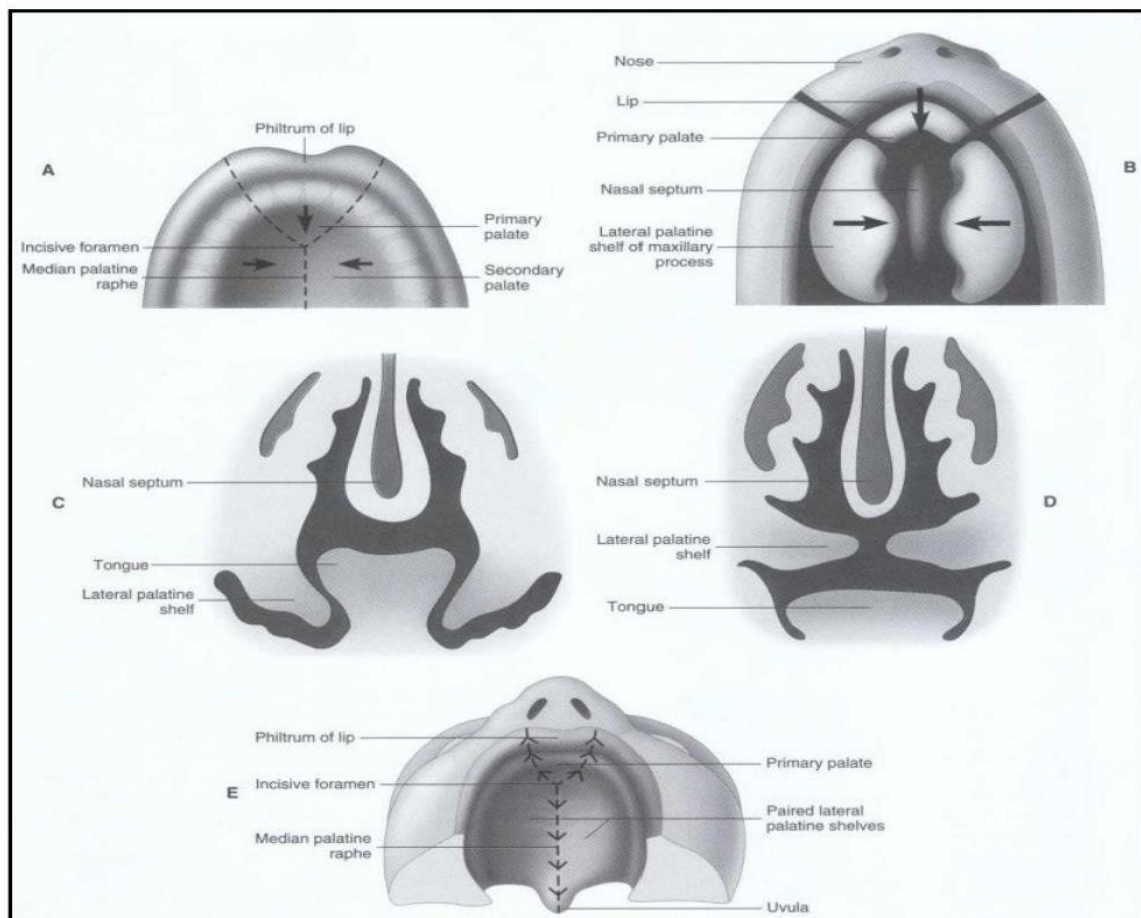
## Development of palate

The palate begins to develop early in the 6th week, but the process is not completed until 12th week. The most critical period during palatal development is the end of the 6th week to the beginning of the 9th week.

The entire palate develops from:

1- the primary palate (premaxilla): is the triangular-shaped part of the palate anterior to the incisive foramen. Its origin is the deep portion of the intermaxillary segment, which arises from the fusion of the two medial nasal prominences.

2- the secondary palate : give rises to the hard and soft palate posterior to the incisive foramen. It arises from paired lateral palatine shelves of the maxilla. These shelves are oriented in a superior-inferior plane with the tongue interposed. Later they become elongated and the tongue becomes smaller and moves inferiorly. This allows the shelves to orient horizontally, to approach one another, and to fuse in to midline. Later on these lateral palatal shelves fuse with the primary palate and nasal septum. Cleft palate results if the lateral palatal shelves failed to fuse with each other, with the nasal septum, or with the primary palate.



## Development of the tongue

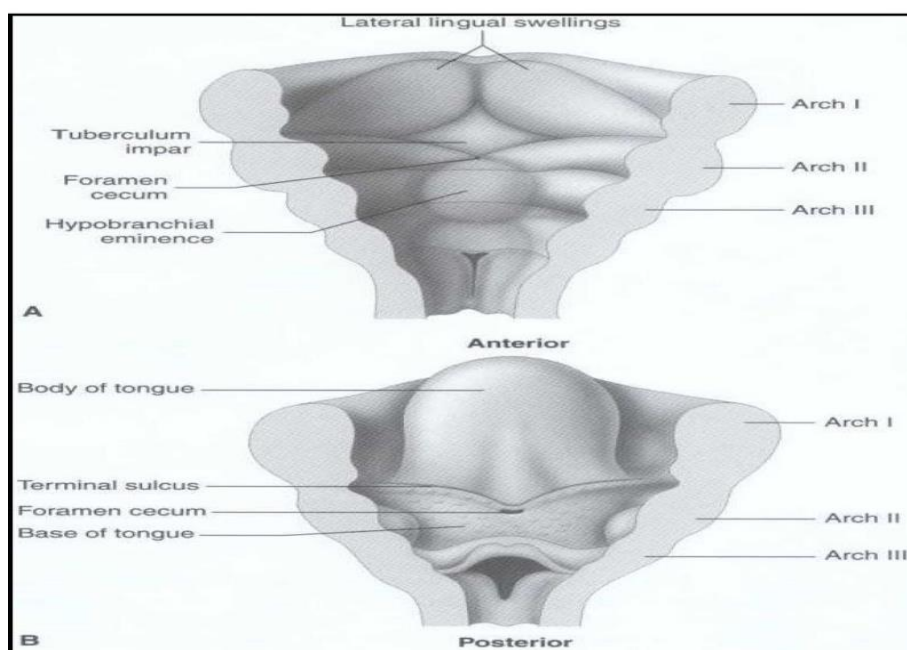
The tongue develops from several different sources. The body of the tongue or anterior two thirds develops from the first pharyngeal arch, Whereas the base of the tongue or posterior one third develops from the third arch.

The tongue begins its development near the end of the fourth week as a midline enlargement in the floor of the primitive pharynx cranial to the foramen cecum .

The enlargement is called the tuberculum impar. Two lateral lingual swellings form adjacent to the tuberculum impar. All three structures form as a result of proliferation of first arch mesenchyme. The lateral lingual swellings rapidly enlarge, fuse with one another, and overgrow the tuberculum impar. These three structures give rise to the body of the tongue.

The posterior third, or base, of the tongue develops from the hypobranchial eminence, which is a midline swelling caudal to the foramen cecum. The hypobranchial eminence is composed primarily from third arch.

The *copula* is a midline enlargement derived from second arch. The hypobranchial eminence overgrows the copula and fuses with the tuberculum impar and lateral lingual swellings. The copula disappears without contributing to the formation of the tongue. Thus the base of the tongue is derived from the third pharyngeal arch. The line of the demarcation between the body and the base is called *terminal sulcus*, and the foramen cecum is found in the midline of this structure.



## Development of the skull

The skull forms from mesenchymal connective tissue around the developing brain. The development of the skull is considered in:

1st The development of the *neurocranium*, which is the calvaria and base of the skull and 2nd the development of the *viscerocranium* which includes the skeleton of the face and associated structures.

Each component has some structures that form by endochondral ossification ( cartilaginous component ) and other structures that form by intramembranous ossification ( membranous component ).

(calvaria and base of the skull) ***Neurocranium***

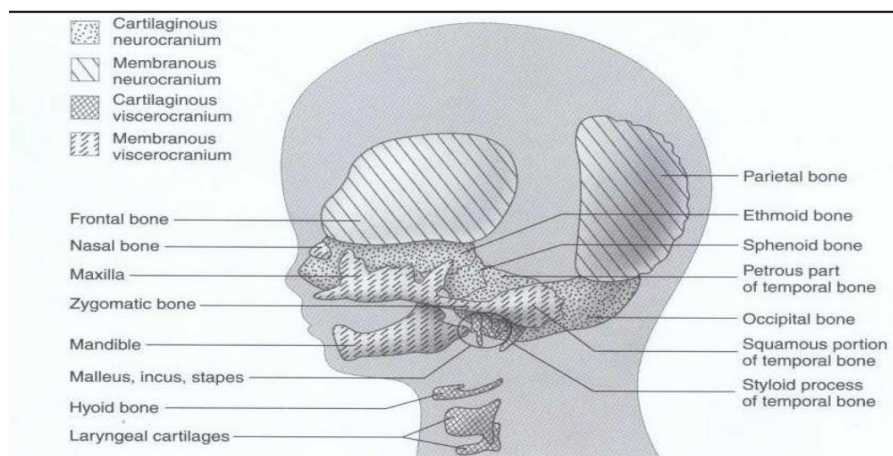
\*The cartilaginous neurocranium ( chondrocranium ) consist several cartilages that fuse and undergo endochondral ossification to give rise to the base of the skull. The cartilage junctions between two bones are called synchondroses. The occipital bone is formed first, followed by the body of the sphenoid bone and then the ethmoid bone. Also the vomer bone of the nasal septum and the petrous and mastoid parts of the temporal bone are formed by the cartilaginous neurocranium.

\*The membranous neurocranium, give rise to the flat bones of the calvaria, including the superior portion of the frontal, parietal, and occipital bones.

sociated structures)(the skeleton of the face and as ***Viscerocranium***

It arises from the pharyngeal arches. \*The cartilaginous viscerocranium includes the middle ear ossicles, the styloid process of the temporal bone, the hyoid bone, and the laryngeal cartilage.

\*The membranous viscerocranium includes the maxilla, zygomatic bones, the squamous temporal bones, and the mandible. These bones form by intramembranous ossification except for the mandibular condyle and the midline of the chin.

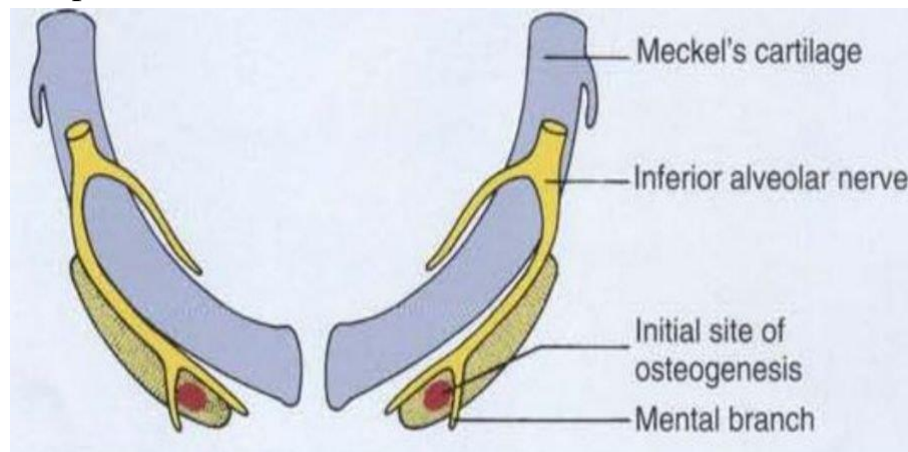


### **The development of the mandible**

In the mandibular brachial arch ( first brachial arch ) there is a cartilage called Meckels cartilage, which is during the 2nd month of intra-utrine life serve as a precursor of the mandibular mesenchyme, which forms around it and is responsible for mandibular growth activity. Bone begins to develop lateral to the Meckels cartilage during the 7th week and continues till the posterior aspect, which is covered with bone.

The part of the Meckels cartilage that has been encapsulated, serving its purpose as a splint for the intramembranous ossification, then it will be largely deteriorates.

The activity of the condylar cartilage does not appear until the 4th or 5th month of postnatal life and continues until the age of 20 years so it has no role in the prenatal life.



### **The skulls and jaws at birth**

At birth the skull is far from merely a small version of the adult skull. There are difference in shape, in proportion of the face and the cranium and in the degree of development and fusion of the individual bones. Some bones, which in adult are single bones, are still in separate constituent parts at birth. Other bones, which in the adult are closely joined to their neighbours at sutures, are at birth, widely separated from neighbouring bones.

Bones which have developed from cartilage, mainly those at the base of skull, still have cartilaginous element activity growing. Bones which have developed from membrane, mainly those of calvarium and face, still have wide membranous areas at their margins actively forming bone. The main features of skull at birth can be summarized as follows:



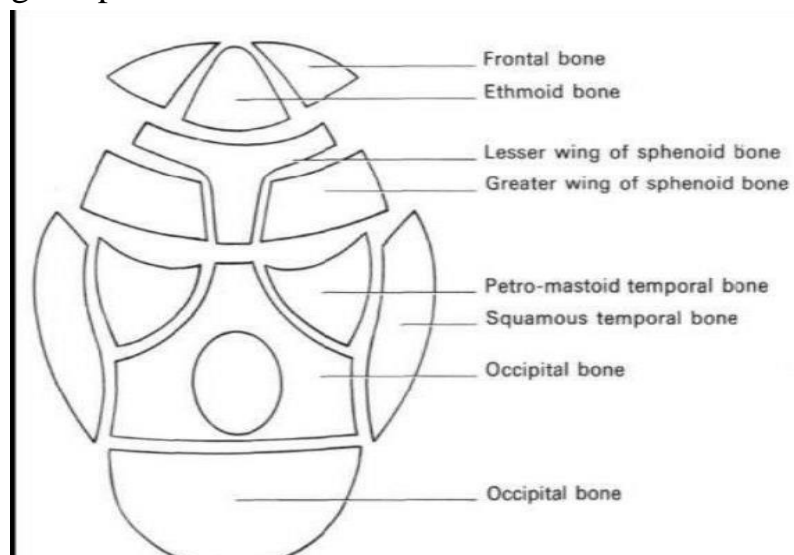
### **1-Bones in separate component parts**

**A-** At the base of the skull the sphenoid bone is in three parts, the central body with its two lesser wings, and on each side the greater wing and its attached pterygoid process.

**B-** The occipital bone is in two parts, the condylar part which carries the occipital condyles, and the squamous part, much of which has developed from membrane and forms part of the calvarium.

**C-** The temporal bone on each side is in two parts, the petromastoid component which has developed from the cartilaginous neurocranium, and the squamous component which has developed from the membranous viscerocranium

**D-** The frontal bone and the mandibule, which will eventually become single bones, are each in two parts at birth, the parts being separated in the mid-sagittal plane.



### **2- bones widely separated from neighbouring bones**

Sutures and fontanelles are present during fetal and early neonatal life.

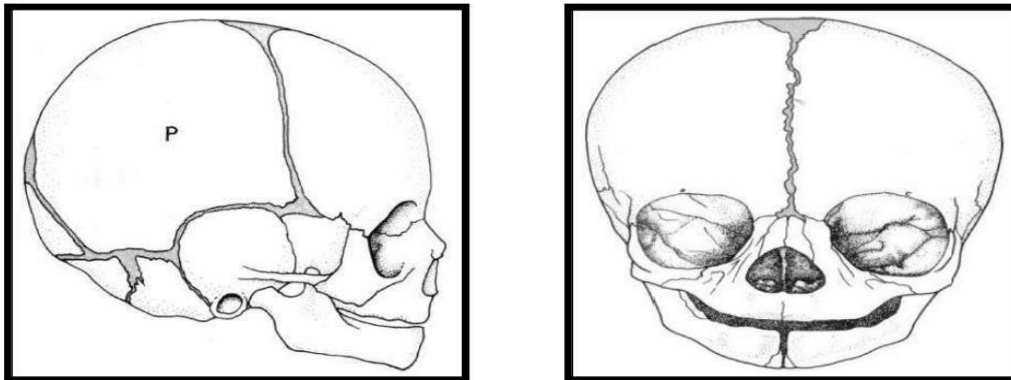
Sutures also called synchondroses, are fibrous joints comprised of sheets of dense connective tissue that separate the bones of the calvaria and help to change the shape during birth, a process called modeling.

Fontanelles are regions of dense connective tissue where sutures come together. Sutures and fontanelles ossify at variable times after birth.

This separation is particularly noticeable at the four corners of the parietal bone, which are the anterior and posterior fontanelles in the midsagittal plane where the parietal bones meet the frontal bone anteriorly and

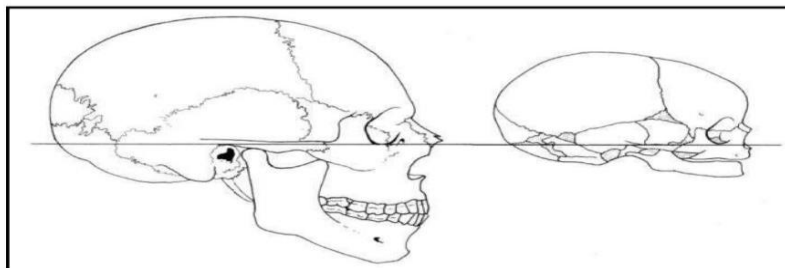
occipital bone posteriorly, and the antero-lateral and postero-lateral fontanelles on each side, at the junction of parietal, sphenoid and frontal bones anteriorly and parietal, temporal and occipital bones posteriorly.

At birth the sphenoid and occipital bones are still separated by a cartilaginous area, the spheno-occipital synchondroses, and eventually become fused at the base of skull.



### **3- relative size of the face and the cranium**

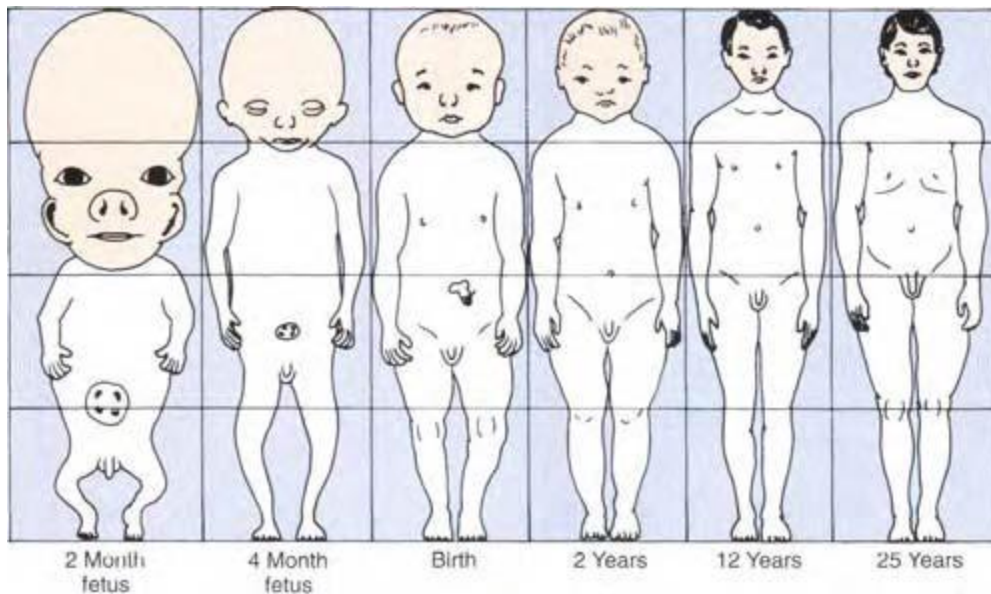
The relationship in size between the face and the cranium is noticeably different at birth from that in the adult. The cranium has grown rapidly in the pre-natal period, accommodating the rapidly developing brain. The face has developed less towards its adult size than has the cranium, with the result that at birth the face appears small in the vertical dimension in relation to the total size of the head when compared with the situation in the adult. The main reasons for this are the maxilla and the mandible, which form the main contribution to the vertical dimension of the face, are relatively small at birth. The maxillary antrum is little more than a flat space, compared with its much greater vertical depth in the adult. The mandible is relatively straight, with a more obtuse angle than in the adult. In both bones there are no erupted teeth and consequently little vertical development of alveolar bone.



### ***Rates of growth from birth to adult***

At birth the head forms about 1/4 of the total height of the body. In the

adult the head forms about 1/8 of the total body height therefore, between birth and maturity the body must grow faster than the head.



In infancy, growth proceeds at a relatively high rate, slowing progressively during childhood to reach a minimum rate in the prepuberal period. There is an increase in growth rate in puberty and finally a marked slowing in growth rate to maturity.

The age at which these phases of growth begin and end varies between individuals.

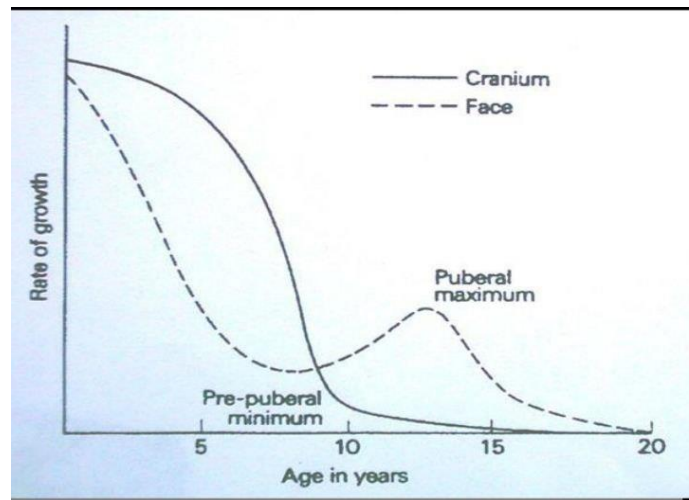
The two main components of the head are the cranium and face, they also differ in their relative proportion at birth and at maturity, and therefore they must grow at differing rates.

### ***Growth rate of the cranium***

The cranium, which has grown rapidly before birth, continues to grow rapidly up to about one year of age, accommodating the brain, which at this stage is developing to provide an enormous increase in physical and mental activity. Thereafter the growth rate decreases, and by about 7 years of age the cranium has reached some 90% of its final volume. Then there is a slow increase in size to maturity.

The growth rate of eyes, and consequently of the eye sockets, follows a similar pattern. Thus the infant appears to have a small face with large eyes, large cranium and retrusive nose if compare with adult.





### ***Growth rate of the face***

The growth rate of the face, which is highest at birth, falls sharply and reaches a pre-puberal minimum level, it is earlier in female than in male, then it increases to a peak at puberty, declining again until growth stops in late teenage.

Facial growth is normally associated with eruption of the primary dentition between 1 and 3 years of age and of the permanent dentition between 6 and 14 years of age, when the erupting teeth and developing alveolar process add to the total size of the jaws.

Roughly the facial growth rate follows the same pattern as the rate of body growth, forward and downward growth of both maxilla and mandible follow this pattern, and the period of maximum puberal growth of the jaws is a few months later than that of body height. Also the mandibular growth continued for about 2 years longer than maxillary growth and this difference in growth between the two jaws may be important in orthodontic treatment planning.

***My great wishes for my lovely students for success. Thanks***

## Orthodontics

### *Mechanisms and areas of growth*

Bone unlike most other tissues, cannot grow simply by interstitial division of its living cells to give increasing size. There are three main mechanisms of bone growth, each of which plays its part in the growth of the skull and jaws:

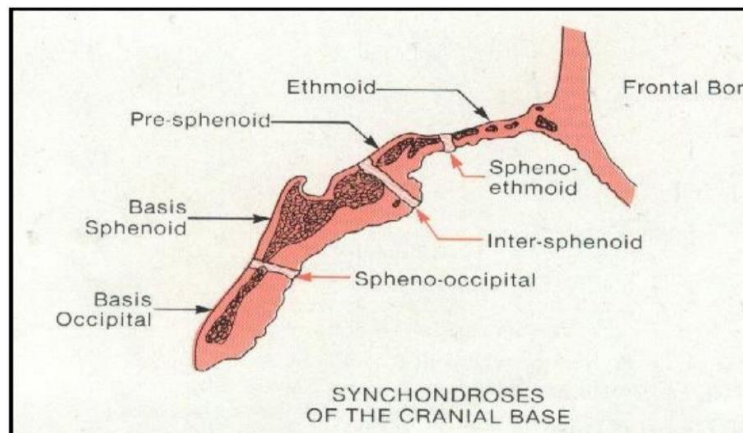
#### **1- Cartilaginous growth:**

The growth of cartilage by cell division with progressive conversion to bone by ossification. This growth occurs mainly in:

A- At the base of the skull (spheno-occipital synchondroses ) would increase the antero-posterior dimension of the skull base.

B- In the area of the nasal septum would bring the nose forward from its original position under the front of the cranium.

C- At the head of the mandibular condyle would increase the total length and height of the mandible.

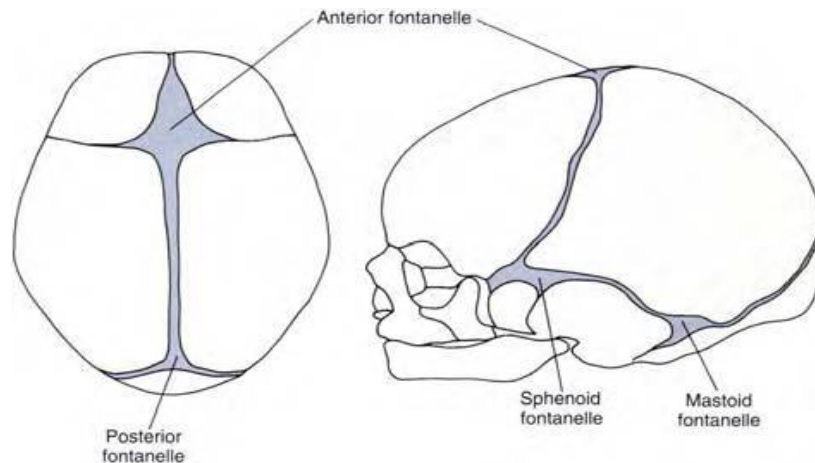


#### **2- Sutural growth**

The bony sutures of the head would be capable of increasing the size of the head in all dimensions. The sutures which separate the face from the cranium are aligned so that growth at these sutures would move the face in a forward and downward direction in relation to the cranium.

In the very early years when the bones of the skull are widely separated from each other, sutural growth is active in bringing the bones into close proximity. Some sutural growth take place at the same time with the enlargement of the bone, therefore sutural growth must be active at the

same time of main enlargement of the cranium that is up to 6 or 7 years of age.



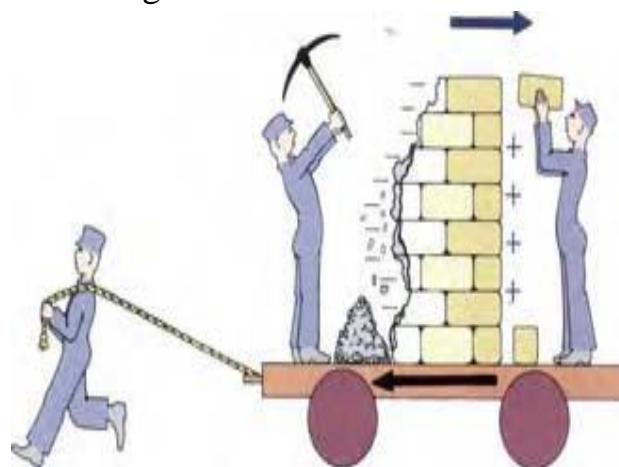
### **3- Periosteal and Endosteal growth**

The apposition of bone on the periosteal surfaces would obviously enlarge the head in all dimensions, but this will increase the thickness of bone therefore concomitant resorption of bone is necessary in order to obtain the appropriate thickness and strength.

However, periosteal growth is not simply a matter of addition of bone to the outer surface and resorption of bone from the inner surface. Extensive remodeling of bones takes place, which involve resorption of bone from the outer surface and apposition of bone on the inner surface.

Endosteal resorption and addition of bone from within the cancellous spaces is also necessary to maintain the appropriate thickness of the cortical layer of bone.

It is generally thought that this method of growth is the most active type of growth in the skull and jaws after the first few years of life, when cartilaginous and sutural growth slows.



### **Moss theory (Functional matrix growth)**

This theory depend on the concept that each part of the skull will grow by the stimulation of tissue matrix that mean the bones will grow to accommodate a growing vital organ, as:

- \* the vault of the cranium will grow by the stimulation of growing brain to accommodate its increase in size.
- \* the orbital cavity, this will grow by stimulation of growing orbit.
- \* the growth of the mandible can also be stimulated by the growth of tongue.
- \* alveolar bone growth can also be stimulated by development and eruption of teeth.

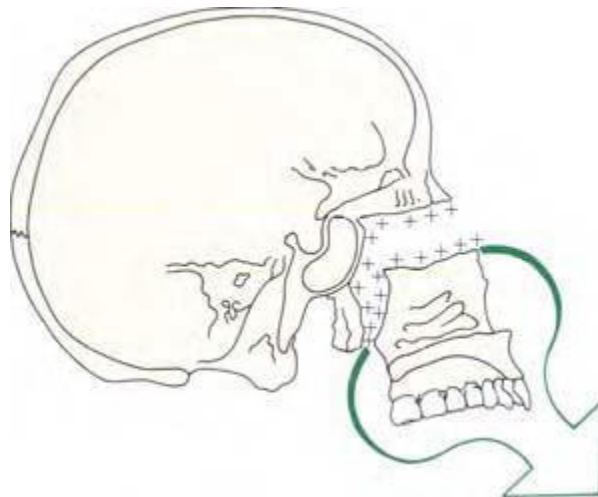
### **TERMINOLOGY RELATED TO GROWTH GROWTH FIELDS**

**GROWTH SITES:** Are growth fields that have a special significance in the growth of a particular bone, e.g. mandibular condyle in the mandible, maxillary tuberosity in the maxilla. The growth sites may possess some intrinsic potential to grow (debatable).

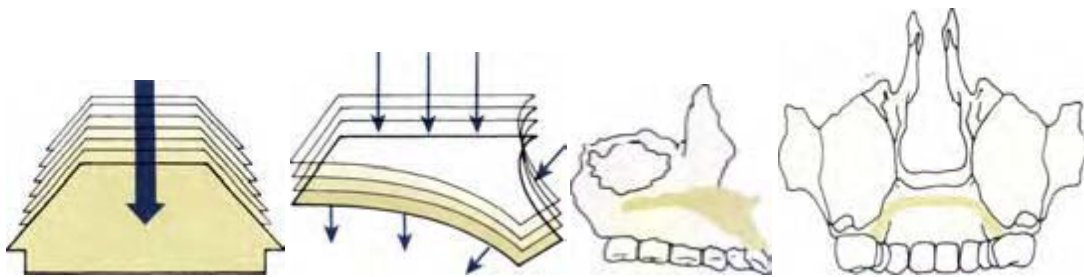
**GROWTH CENTERS:** Are special growth sites, which control the overall growth of the bone, e.g. epiphyseal plates of long bones. These are supposed to have an intrinsic growth potential (unlike growth sites).

**Displacement:** Growth which causes the mass of the bone to be moved relative to its neighbors, usually brought about by forces exerted by the soft tissues and by intrinsic growth of the bones themselves, e.g. epiphyseal plates and synchondroses; an example is forward and downward translation of the maxillary complex (fig. 1).

**Drift:** The in the position of the bony structure owing to the remodeling of that structure, as seen in (fig.2) in which the palate moves downward during growth as a result of bone being laid down on its inferior surface and resorbed on its superior surface.



**Figure 1 displacement**



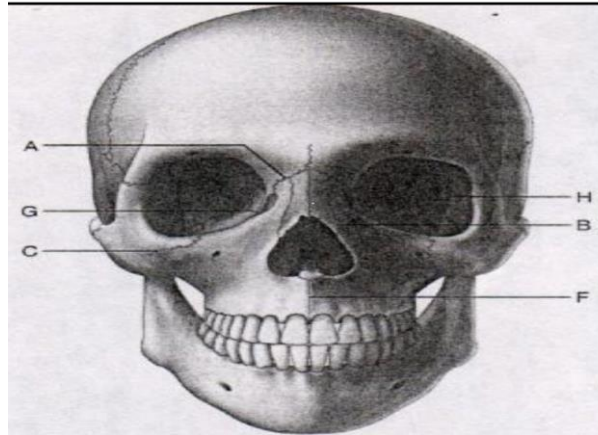
**Figure 2 drift**

***Naso-maxillary growth***

**The maxilla:**

The maxilla develops postnatally entirely by intra-membranous ossification. Since there is no cartilage replacement, growth occurs into two ways : Sutural growth and surface remodeling which can be described as

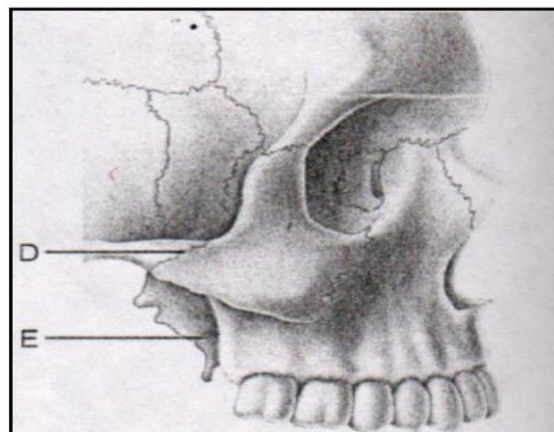
**A- Trasversal growth:** by apposition of bone at the sagittal sutures such as inter nasal suture, intermaxillary suture, interpalatine suture, their activity decrease at the end of the first year but they continue forming osteal tissue for a long period. Also apposition of bone at the external aspect of the maxilla on both sides at the premolar regions by surface remodeling.



**B- Vertical and antero-posterior growth:**

this is accomplished in two ways:

\* Apposition of bone at the sutures that connect the maxilla to the cranium and cranial base such as temporo-zygomatic suture, maxillo-zygomatic suture, pterygo-palatine suture and fronto-maxillary suture, these are parallel to each other and they orient the direction of the facial growth downward and forward



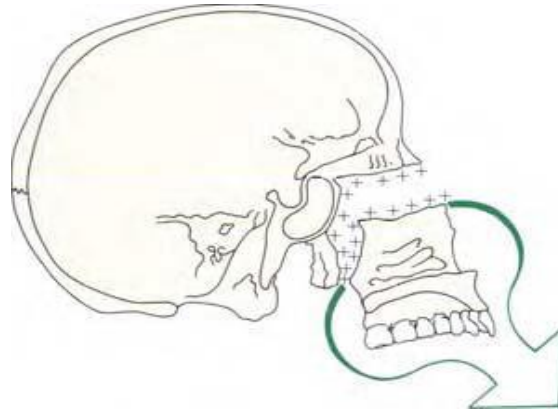
\* Surface remodeling which occurs by include:

1-vertical growth

# alveolar process: the formation of alveolar process start about the 4th month of intrauterine life their growth is by apposition of bone on three aspects( inferior, internal, external ) in posterior region and on two aspect( internal, inferior ) in the anterior region.

# palate: there will be resorption on the superior aspect ( nasal ) and apposition on the inferior aspect ( oral ) which will bring the palate downward





2-antero-posterior growth occurs by

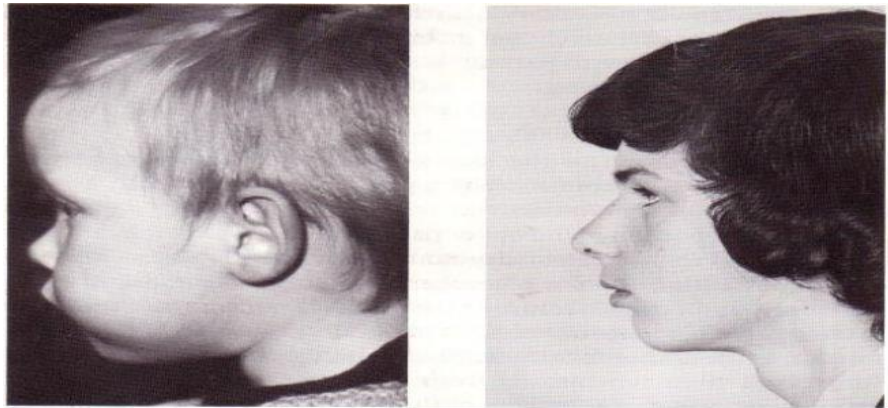# anterior alveolar growth, resorption in the vestibular part and apposition on the inferior and palatal part.

# an apposition on the posterior aspect of the horizontal part of the palate.

# development of the tuberosity.

### **Nasal region**

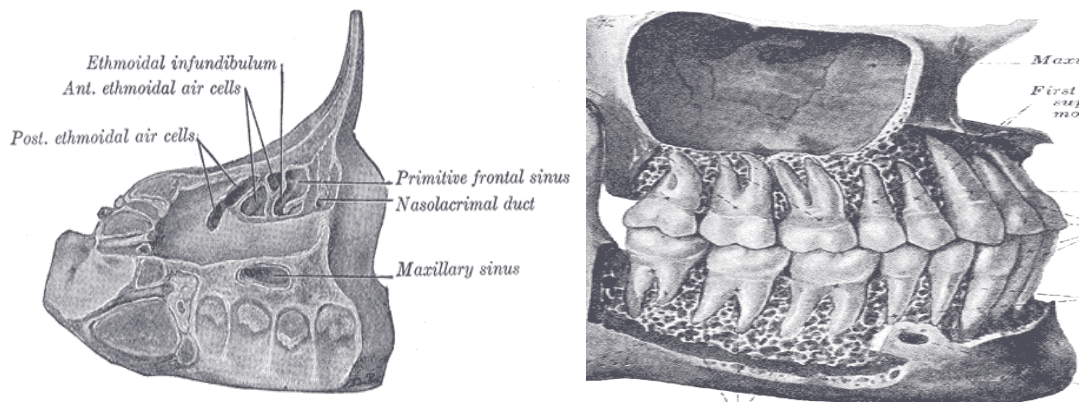
The superior part of the nose wedged between the orbits and the nasal cavity develops particularly on their inferior part from the 10 years of age and continue to develop in the vertical and transversal direction which is in relation with the descending palate.



### **Maxillary sinus**

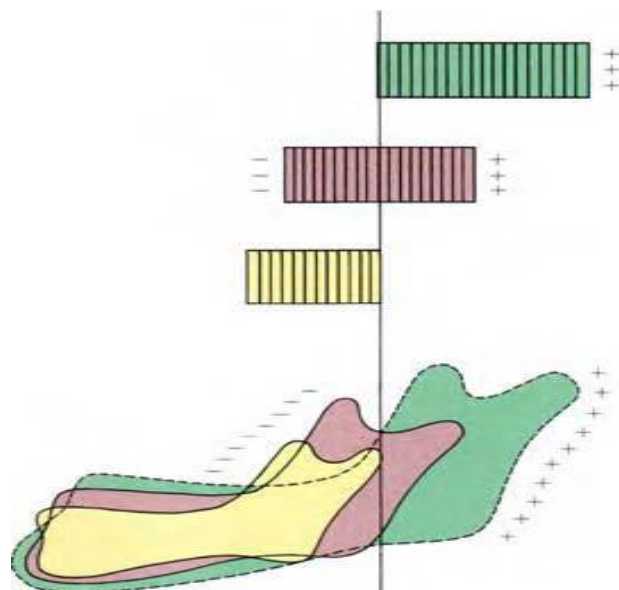
As the sinus has the volume of small peas, the eruption of deciduous teeth will modify its volume and it increases in size with the eruption of the 1st molar, about 8 years it has a pyramidal form that will lengthen after the eruption of the canine and the last molar.





### ***Mandibular growth***

The mandible is a bone of membranous origin but there are secondary cartilages that develop in it. At birth the mandible consist of two hemi-mandible separated by sympheseal suture. The condylar cartilage will persist for long time but the coronoid cartilage and the cartilage of the angle of the mandible will disappear early and play no role in the mandibular growth. The sympheseal suture will disappear at two years of age. The condylar cartilage will contribute in the vertical and antero-posterior growth. The increase in size is due to apposition and resorption phenomena.



### ***a- Trasversal growth:***

After the first year, the sympheseal cartilage does not play any more role in the growth, only the apposition and resorption phenomena continue to manifest but they stop early, only the alveolar borders show thickening which accommodate the roots of the permanent teeth, in fact the increase in transverse dimension of the mandible result from its vertical growth because of its divergence toward the posterior, the trasversal growth is

therefore sensitive in the posterior part, particularly at the condyles which are more away from each other following the transversal growth of the cranial base.

***b- Antero-posterior growth:***

1- ramus of the mandible: it result in important apposition on its posterior border and resorption on the anterior border but less rapid than the apposition in a way that the ramus will move backward and become more thick.

2- body of the mandible: the resorption of the anterior border of the ramus will increase the antero-posterior dimension of the body of the mandible. So the inferior part of the ramus is therefore incorporated progressively in the body also an osteal apposition occurs during the first year of life particularly at the mental symphysis.

***c- Vertical growth:***

1- ramus of the mandible :at birth the ramus is very short, its size ramus of the mandible depending on the activity of the condylar cartilage that determines the vertical dimension in the same time as the total length of the mandible.

2- body of the mandible :the vertical growth of the ramus will move away the body of the mandible from the maxilla in the space that is liberated there through the development of the alveolar process by osteal apposition jointly with the phenomena of teeth eruption. Little apposition during the first year occurs at the inferior border of the body of mandible.

**Cleft lip and palate**

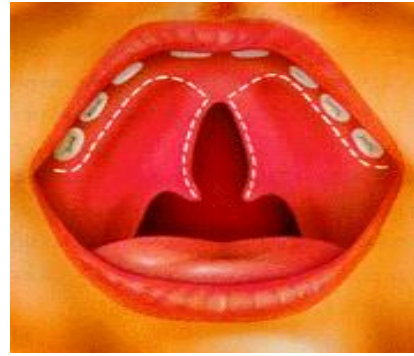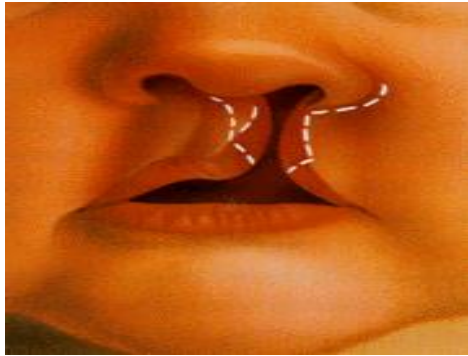
The most common craniofacial anomaly, caused by failure of fusion between certain embryological processes during facial morphogenesis. Failure of fusion between the medial and lateral nasal and the maxillary processes results in a cleft of the lip and/or alveolar process.

Failure of fusion between the lateral palatine processes results in a cleft of the palate.

The etiology of cleft lip and palate is thought to be multifactorial. Genetic is implicated in 20%-30%of the patients. Environmental factors that have been shown in

experimental animals to result in clefting include nutritional deficiencies, radiation, several drugs, hypoxia, viruses, and vitamin excesses or deficiencies. In complete or bilateral

clefts of the lip, alveolus and palate, the maxillary arch typically is collapsed in the transverse direction, especially in the area of the cleft. The maxillary permanent lateral incisors may be congenitally missing or malformed, and many atypically shaped supernumerary teeth may be present in the area of the cleft.



### **Classification:**

A cleft can be complete or incomplete, and it can occur unilaterally or bilaterally. A useful classification divides the anatomy into primary and secondary palates. An individual thus may have clefting of the primary palate, the secondary palate, or both.

Cleft lip is classified either unilateral or bilateral and it could be minor cleft of the lip ( small notch in the upper lip ) or increase in the severity to complete cleft of the upper lip or continue to reach the nostril or to the internal angle of the eye, mostly unilateral, sometimes cleft lip may include cleft of the alveolar ridge.

Cleft palate: the fusion of the palatal components that form the palate usually start from the anterior aspect and continue posteriorly so that cleft palate could happen at any site through this process of fusion.

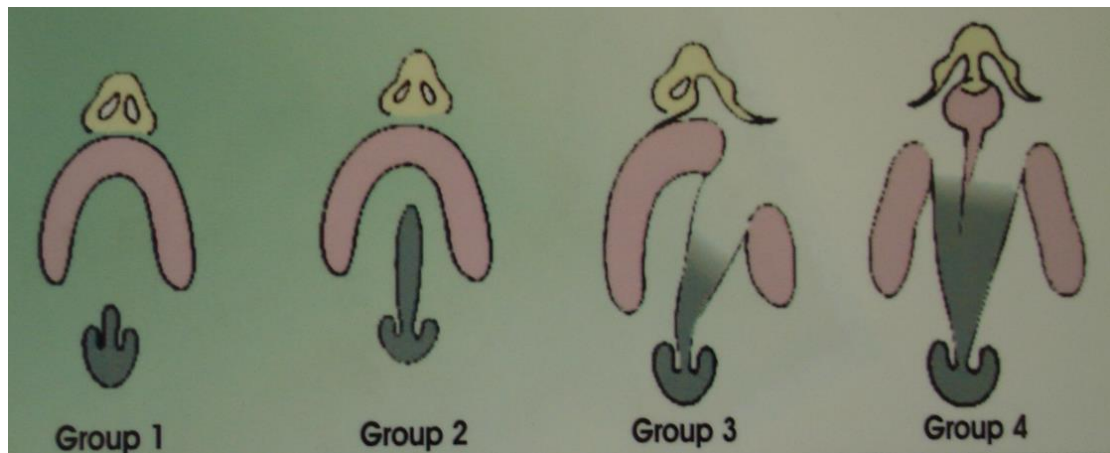
Cleft palate can be classified according to its severity as follows:

Class I : Cleft of soft palate (uvula)

Class II : Cleft of the secondary palate ( median palatine cleft )

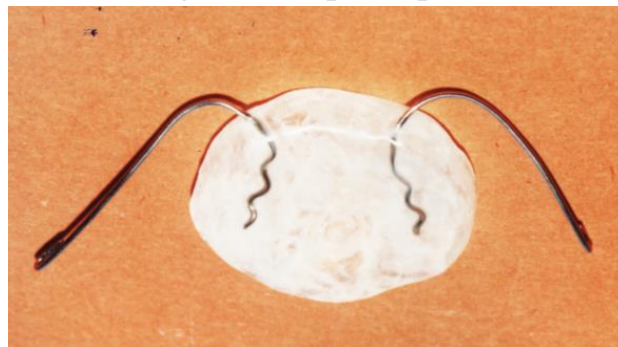
Class III: Complete unilateral cleft palate

Class IV: Complete bilateral cleft palate



### **Treatment**

Treatment of cleft lip and palate must be started as soon as possible after birth because of its physiological effect on the infant since it interferes with the natural feeding process, and its psychological trauma to the parents, this treatment of patients with cleft lip and / or palate is a long and involved process, requiring many stages of intervention by many different specialists, forming a cleft lip and palate team.



The involvement of the team, orthodontist starts a few days after the baby was born, with presurgical infant orthopedic treatment if applicable, ( construction of baby feeding plate which assists the infant to suck and swallow the milk properly ).

Baby feeding plate is a piece of acrylic that disconnect between the oral and nasal cavities which are opened to each other through the cleft palate. This plate has advantage to help the two pieces of the palate to approximate toward each other ( orthopedic movement ).

Repair of the lip usually is performed within the first three months after birth, and the palate subsequently is repaired within the first year. The scar tissue created from these and other surgical procedures is considered responsible for variable degrees of maxillary growth inhibition which is commonly seen during subsequent growth. When the cleft involves the

alveolar process, a bone graft may be necessary to restore the alveolar anatomy. Alveolar bone grafting usually is performed prior to the eruption of the permanent maxillary canine on the side of the cleft.

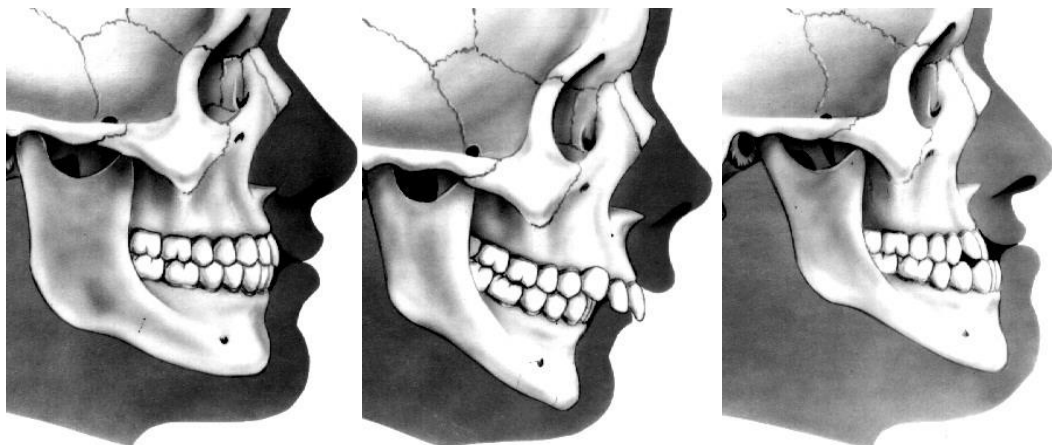
*Phase I* of orthodontic treatment, in preparation for the alveolar bone graft, may consist of expansion of the constricted maxilla and correction of any cross bites. Following alveolar bone grafting, and when the patient is in the permanent dentition, *phase II* of orthodontic treatment is performed to idealize the occlusion, or if a severe skeletal discrepancy is present, to prepare the arches for orthodontic surgery.

### ***Facial growth and the occlusion***

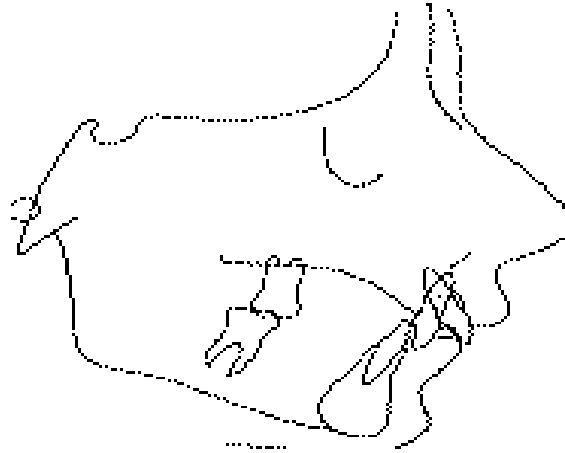The alveolar bone is highly adaptable, depending for its existence and location on the presence and position of the teeth: remove a tooth and the associated alveolar process resorbs, move a tooth into the same area make the bone remodels.

### **Dento-alveolar compensation**

Because the upper and lower teeth erupt into the 'neutral zone' of muscle balance between lips, cheeks and tongue they tend to be guided towards one another to establish an occlusion and to compensate for any transverse or antero-posterior mal-relationships of the jaws. Variations in vertical jaw relationships are compensated, to a greater or lesser degree, on eruption of the teeth and growth of the alveolar processes. Where the skeletal malrelationships are too severe, the dento-alveolar compensation described above may not be sufficient to establish a normal occlusion and so crossbite, open bite and antero-posterior arch mal-relationships may develop. Therefore, mal-occlusion often will be less severe than might have been expected from the jaw mal-relationship by this compensation. (see Figure below).



Dento-alveolar compensation is not always advantageous: in some cases of mandibular retrusion, for example, compensation occurs by retroclination of the upper incisors (see Figure below).



This type of incisor relationship is usually associated with a deep overbite and may, when associated with poor oral hygiene, be traumatic as well as being unsightly.

### **Dento-alveolar adaptation**

As the face grows, the intermaxillary space increases in height and the anteroposterior jaw relationship may change. As a result of vertical growth of the teeth and alveolar processes, occlusal contacts, and the soft tissue environment of the teeth, so the existing occlusion tends to be maintained. Dentoalveolar adaptation is a dynamic process (occurs as a result to normal growth in normal jaws relation) .

Dento-alveolar adaptation is greatest vertically, in response to vertical growth of the intermaxillary space. Little change in transverse jaw relationships occurs with growth. Where changes in antero-posterior jaw relationships occur there will usually be a corresponding dento-alveolar adaptation. Most commonly the mandible grows forwards slightly more than the maxilla, so the upper incisors expected to procline whilst the lower incisors retrocline. The proclination of the upper incisors does not produce spacing in the same upper arch because the upper buccal segments come forwards by a comparable amount. Retroclination of the lower incisors usually results in crowding (late lower incisor crowding in young adults).

### **Growth rotations:**

Growth rotations are most obvious and have their greatest impact on the mandible (particularly in vertical dimension) while their effects on the maxilla are small.

Mandibular growth rotations result from the interplay of growth of a number of structures which determines the ratio of the posterior to anterior facial heights.

The posterior facial height is affected by the followings:

- 1- The direction of the mandibular growth at the condyles.
- 2- The vertical growth at the spheno-occipital synchondrosis.

The anterior facial height is affected by

- 1- The eruption of the teeth.
- 2- The vertical growth of the soft tissues including the masticatory musculature.

### **Types of growth rotations:**

a-The rotation of either jaw is considered "forward" or "anterior" and given a negative sign if there is more growth posteriorly than anteriorly (clockwise rotation) bringing the chin forward and upward (tendency to skeletal deepbite).

b-The rotation is "backward" or "posterior" and given a positive direction if it lengthens anterior facial dimensions more than posterior ones, bringing the chin downward and backward (counter clockwise rotation). {tendency to skeletal open bite}

c- Average rotation: A mild forward rotation which produces a well-balanced facial appearance.





Forward growth rotations are more common than backward rotations with the average being a mild forward rotation which produces a well balanced facial appearance. A marked forward growth rotation tends to reduce anterior vertical facial proportions and increased overbite {deepbite}.while backward rotation will tend to increase anterior vertical facial proportions and reduced overbite (anterior open bite).

**Developmental Anomalies:**

- 1-Supernumerary teeth: Extra teeth in the dental arch.
- 2-Congenitally missing teeth: Reduce number of teeth in the dental arch.(Lower second premolar; Upper lateral incisor and wisdom teeth.
- 3-Cleft lip and or palate.

*My great wishes for my lovely students for success. Thanks*

# Orthodontics

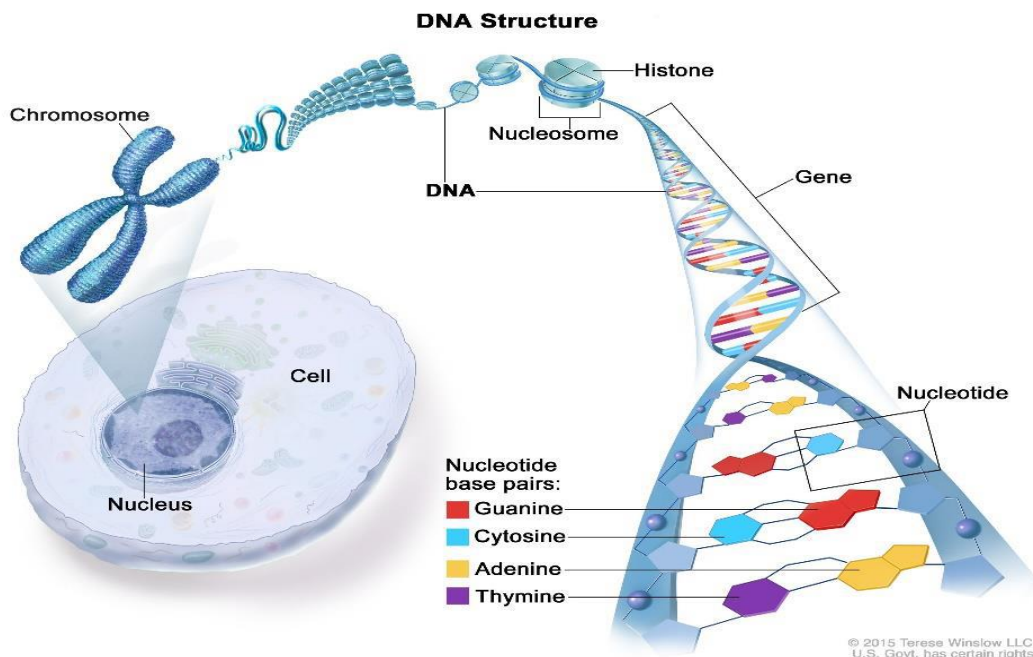
## *Principles of Genetics:*

### **Genetic Factors and Inherited Factors, Its Role on Cranio-Facial Abnormalities Basic Information and Definitions**

Before proceeding, a few basic genetic definitions and concept descriptions are required.

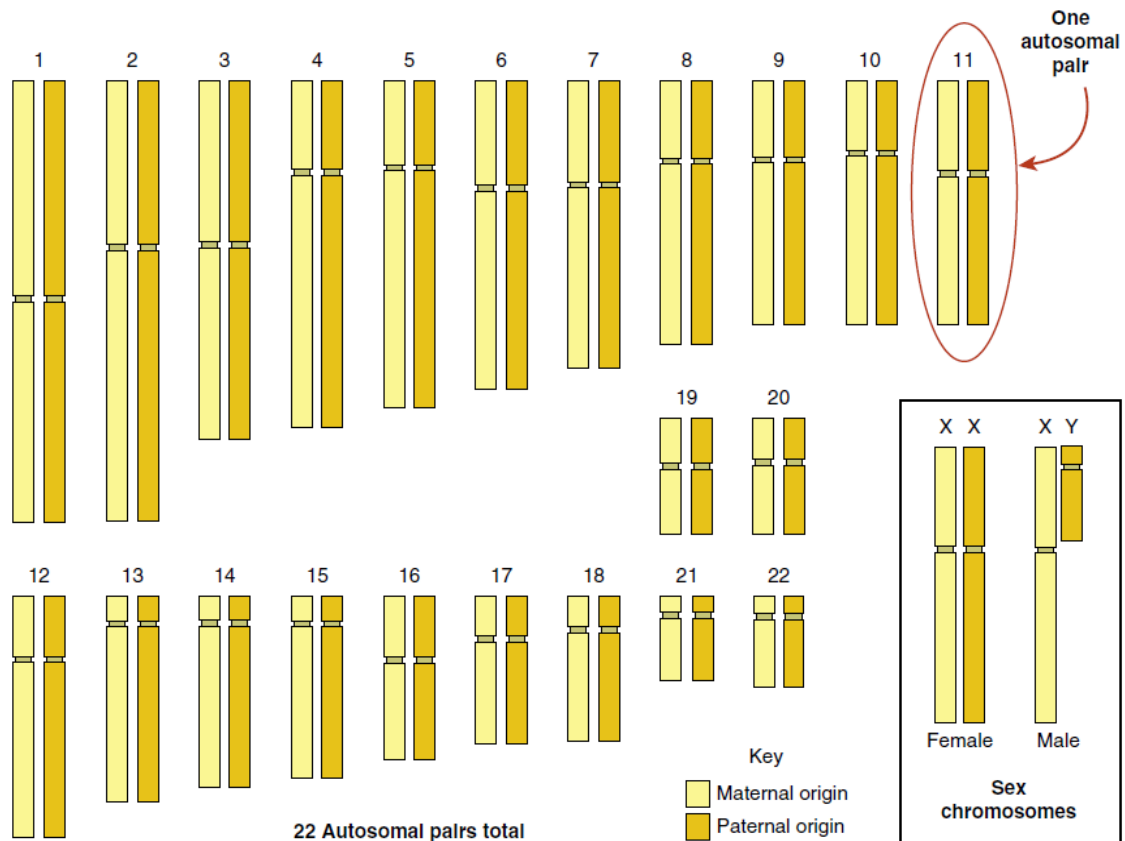
#### **Human Genome**

- An organism's *genome* is defined as the complete set of genetic instructions for that organism. The human genome is made up of a double helix of deoxyribonucleic acid (DNA) comprised of ~3.2 billion chemical nucleotide base pairs (A, Adenine; G, Guanine; T, Thymine and C, Cytosine),
- This genetic information is normally organized into smaller units (ranging in length from ~50 to 250 million base pairs each) called *chromosomes*. A chromosome is made up of a continuous stretch of the double helical DNA that is wrapped around proteins that are called histones.



**Chromosome and DNA structure.**

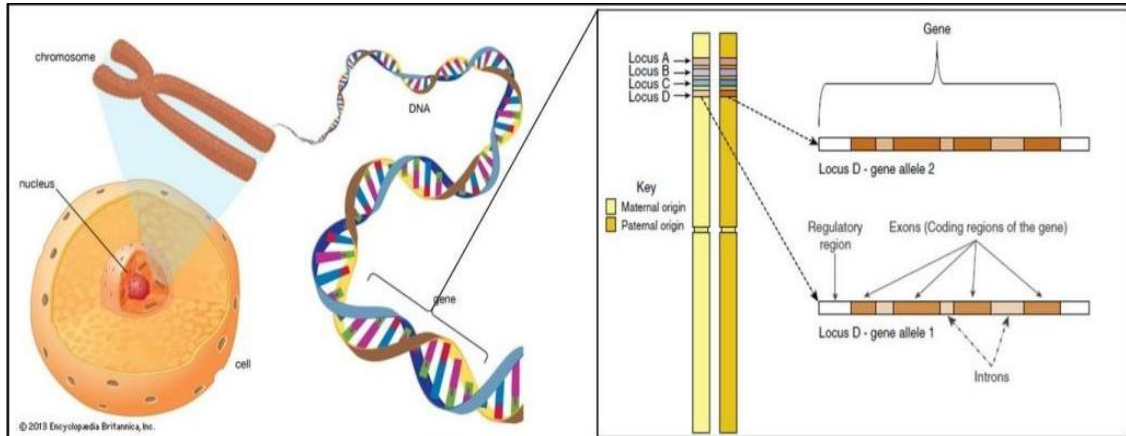
- Altogether, we each inherit a total of 46 chromosomes; 22 *homologous pairs* of chromosomes called *autosomes* that are numbered by size and other characteristics, along with one pair of *sex chromosomes* that are homologous (X,X) in females and only partly homologous (X,Y) in males.
- *Homologous chromosomes* are units of genetic material that are similar in size and structural features. Upon conception, a person inherits all 46 chromosomes (22 autosomal pairs total and one pair of sex chromosomes) that make them a unique individual; one chromosome for each autosomal pair is contributed by each parent, and one sex chromosome originates from each parent. Chromosomes in all subsequent cells are copies of the original maternal or paternal chromosomes.



### Diagram of human chromosomes

□ Looking closer at the chromosomes, they are further organized into smaller units called *genes*, which represent the smallest physical and functional unit of inheritance. A *gene* can be defined as the complete DNA sequence that codes for the synthesis of a specific polypeptide or the synthesis of a specific RNA molecule. Based on the findings of the Human Genome Project (HGP), we have learned that: a) there are an

estimated 25,000 genes in the human genome; b) our genes only make up 2% of the whole genome; and c) the average gene is 3000 nucleotide base pairs in length.



**One autosomal pair of chromosomes illustrating the concepts of four unique gene loci contained on the autosomal pair, multiple alleles, and the general structure of a gene.**

#### □ Allele vs Gene

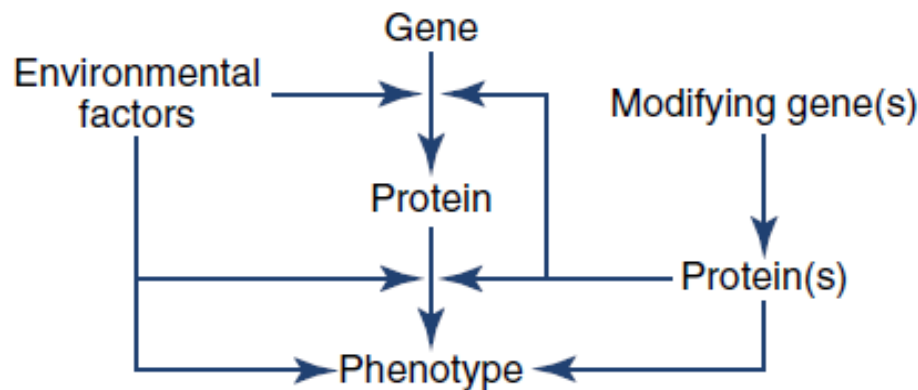
Within the human genome, every gene resides in a specific location referred to as a locus. The term locus is used when describing a single genetic region or location, and loci is plural. Genes at the same locus on a pair of homologous chromosomes are called alleles. One allele would be a copy of the maternal allele and the other a copy of the paternal allele. If these alleles are not identical, they can produce different polypeptide sequences and possibly diverse effects. When a pair of alleles are identical in DNA sequence (e.g., allele A and allele A), the individual is said to be homozygous for that locus. However, when the two alleles have one or more differences in the DNA sequence (e.g., allele A and allele a), the individual is said to be heterozygous for that locus.

#### **Genotype vs Phenotype**

- *Genotype* is a complete heritable genetic identity; it is a unique genome that would be revealed by personal genome sequencing. A genotype generally refers to the combination of alleles at a given locus within the genome (e.g., AA, Aa, or aa). A person's genotype cannot be seen with our eyes but must be determined with the use of a genetic test or analysis. According to the information gained in the HGP, we now know that the human genome is ~99.9% identical from one person to another. Thus, there is only an estimated 0.1% variation within the entire

DNA code between two people that makes each individual unique.

- In contrast to genotypes, *phenotypes* are the observable properties, measurable features, and physical characteristics of an individual. A phenotype is generated by the summation of the effects arising from an individual's genotype and the environment in which the individual develops over a period of time.



**Environmental factors and other genes may modify the clinical expression of the disease or other type of trait but are not of crucial importance for its development.**

### **Heritability of Malocclusion**

The trait is a particular aspect or character of phenotype, e.g. number of teeth, arch length and arch width. Syndrome is a combination of traits that occur together in non-random pattern that is different from the usual pattern. Depending on the genetic influence on traits, the traits can be considered to be of three types:

- i. Monogenic traits (Mendelian):** Traits that develop because of the influence of a single gene locus.
- ii. Polygenic traits (complex or common):** Traits that are resulted from complex interaction of multiple genes.
- iii. Multifactorial traits:** When polygenic traits are influenced by environmental factors along with multiple genetic factors, meaning they are influenced by the interaction of multiple genes, as well as environmental factors.

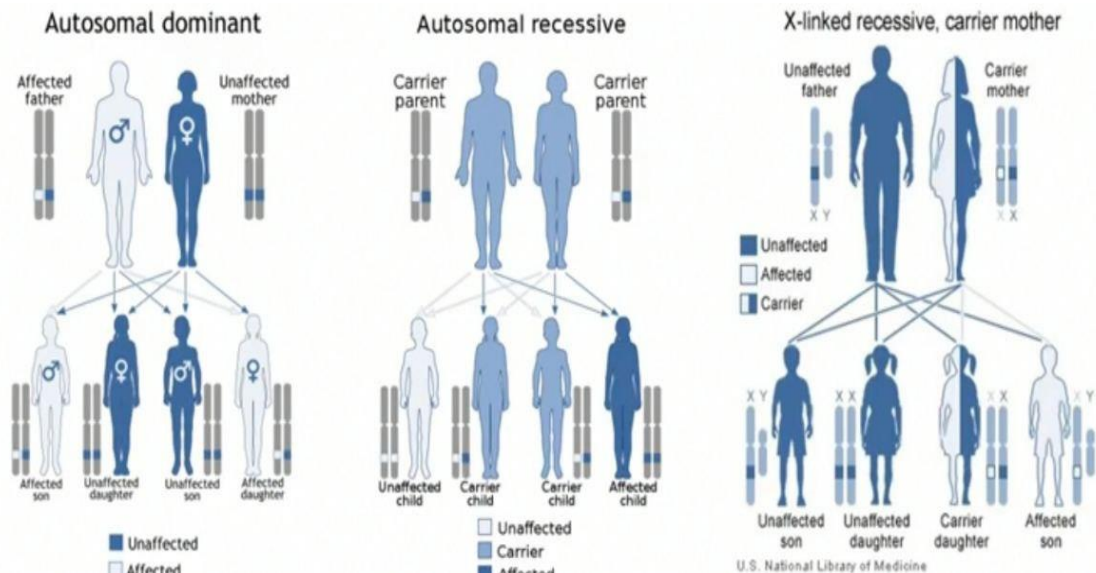
Thus, describes how the genetic information is passed down one generation to the next, as follow:

**I. Autosomal dominant trait or syndrome** – if the gene locus is located on one of 22 autosomal chromosome pairs and the trait or disease manifests itself when the affected person carries only one copy of the

gene responsible, along with one normal allele, then the individual is heterozygous for that allele. However, the affected individual could be homozygous for the responsible gene allele. The mode of inheritance of the trait is called autosomal dominant.

**II. Autosomal recessive trait or syndrome** – if the production of the trait or syndrome does not occur when only one copy of a particular allele is present at the locus on a pair of autosomes, but does occur when two copies of that particular allele are present at the locus of a pair set of autosomes. Two copies of the defective gene are required for expression of the trait. The parents are heterozygous.

**III. X-linked (recessive) trait** – recessive genes on X chromosome. Express themselves phenotypically in males as if they were dominant genes because a male usually only has one X chromosome (hemizygous). A male with the genotype is affected in the pedigree.



□ ***But why should a student of orthodontics be interested in genetics?***

The reason is very simple, whatever affects the growth, development and function of the oral and facial structures is of interest to the student of orthodontics. We have to know exactly why or how a malocclusion occurs, to what extent does it express in the next generation, what is its prevalence and how will it react to a certain treatment plan. And, most importantly, if it can be prevented.

**Mode of Transmission of Malocclusion**

Malocclusion may be defined as a significant deviation from what is defined as normal or ‘ideal’ occlusion. Many components are involved in normal occlusion.

The most important are: (a) the size of the maxilla; (b) the size of the



mandible, both ramus and body; (c) the factors which determine the relationship between the two skeletal bases, such as cranial base and environmental factors; (d) the arch form; (e) the size and morphology of the teeth; (f) the number of teeth present; and (g) soft tissue morphology and behavior, lips, tongue, and peri-oral musculature.

**\*Important Note:**

*For an anomaly to be considered of hereditary origin, it should occur and be a well-defined variation in family groups. A diagnosis of genetic malocclusion should not be made on the basis of a single case of recurrence in the family. Longitudinal studies of pedigree same family are a great help in recognizing and quantifying such malocclusions.*

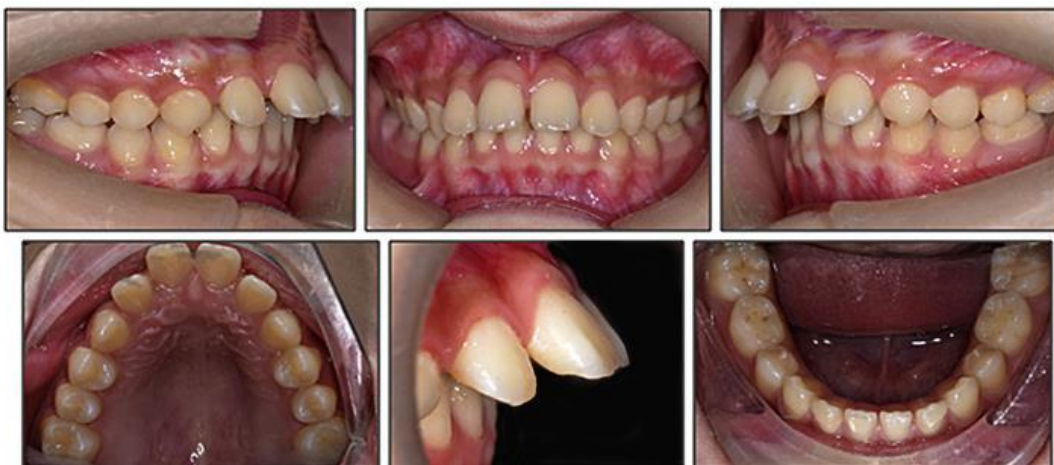**Dental and Skeletal Characteristics that are Inherited**

Most problems in orthodontics are not strictly the result of only genetic or only environmental factors, unless trauma, but a combination of both. It is important to understand the cause of the problem before attempting treatment.

**□ Class II Division 1 Malocclusion**

Class II division 1 malocclusion appears to have a polygenic/multifactorial inheritance.

Environmental factors can also contribute to the aetiology of class II division 1 malocclusions such as digit sucking. Soft tissues can exert an influence on the position and inclination of upper and lower incisors and the need to achieve lip/tongue contact for anterior oral seal during swallowing can encourage the lower lip to retrocline the lower incisors and the protruding tongue to procline the uppers, influencing the severity of the overjet.

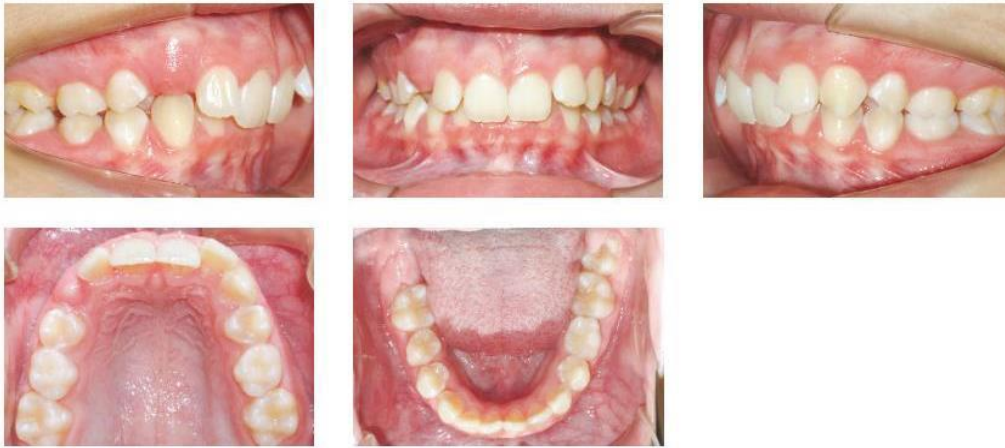

**Class II division 1 malocclusion**



- **Class II div 2 (have strong genetic component)**

Class II division 2 malocclusion exhibits high genetic influence and is often considered as a genetic trait. Results of many studies suggest the possibility of autosomal dominant inheritance. Class II div 2 is a multifactorial (polygenic complex) trait; a number of genes (acting additively) rather than being the effect of a single controlling gene for the entire occlusal malformation. High lip line, lip morphology and behaviour are also considered to be causing Class II division 2 malocclusion. Furthermore, the presence of strong masticatory muscle pattern in Class II division 2 cases is explained by the genetically determined muscular and neuromuscular system.



**Class II division 2 malocclusion.**

- **Class III (have strong genetic component)**

Class III malocclusion with mandibular prognathism often runs in families. The most famous example of a genetic trait in humans passing through several generations is probably the pedigree of the so-called "Hapsburg family". This was the famous mandibular prognathism demonstrated by several generations of the Hungarian/Austrian dual monarchy. Many studies had suggested a strong genetic basis for mandibular prognathism (autosomal dominant trait). The genetic factors appear to be heterogeneous with monogenic influence in some families and multifactorial (polygenic complex) influence in others. Although wide range of environmental factors have also been suggested as a contributor to the development of mandibular prognathism. Among these are enlarged tonsils, nasal blockage, posture, hormonal disturbances, endocrine imbalances and trauma/disease. Soft tissues do not play a part in the aetiology of class III.



Mandibular prognathism in the Hapsburg family. (A) Phillip II and Prince Ferdinand, 1575 (Titian). (B) Phillip IV, 1638 (Velasquez). (C) Charles IV and family, 1800 (Goya). In C, note the strong lower jaw in baby, father, and grandmother but not in mother.

### **Malocclusion associated with genetic syndromes**

Craniofacial disorders and genetic aetiology with malocclusion include:

- 1) Facial clefts, cleft lip and cleft palate.
- 2) Cleidocranial dysplasia.
- 3) Gardner's syndrome.
- 4) Down's syndrome.
- 5) Osteogenesis imperfecta.

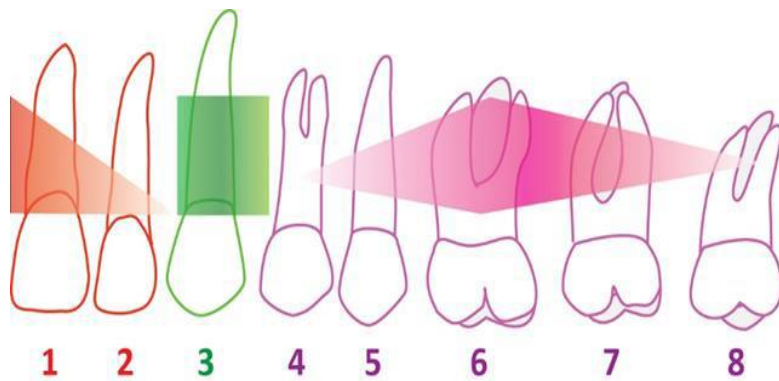
### **Butler's Field Theory**

According to this theory, mammalian dentition can be divided into several developmental fields. The developmental fields include molar/premolar field, the canine field and the incisor field. Within each developmental field, there is a key tooth, which is more stable developmentally and on either side of this key tooth, the remaining teeth within the field become progressively less stable.

□ Within Molar/Premolar Field: Within molar/ maximum variability will be seen for the third molars. Third molars are the most common teeth to be congenitally absent and to be impacted. When premolars are congenitally absent, the second premolars are more commonly affected than the first premolars.

□ Within Incisor Field: Within incisor field, according to Butler's field theory, the maximum variability will be seen for the lateral incisor. Variabilities of lateral incisor include:

- a) Peg-shaped lateral incisor.
- b) Congenitally missing laterals.



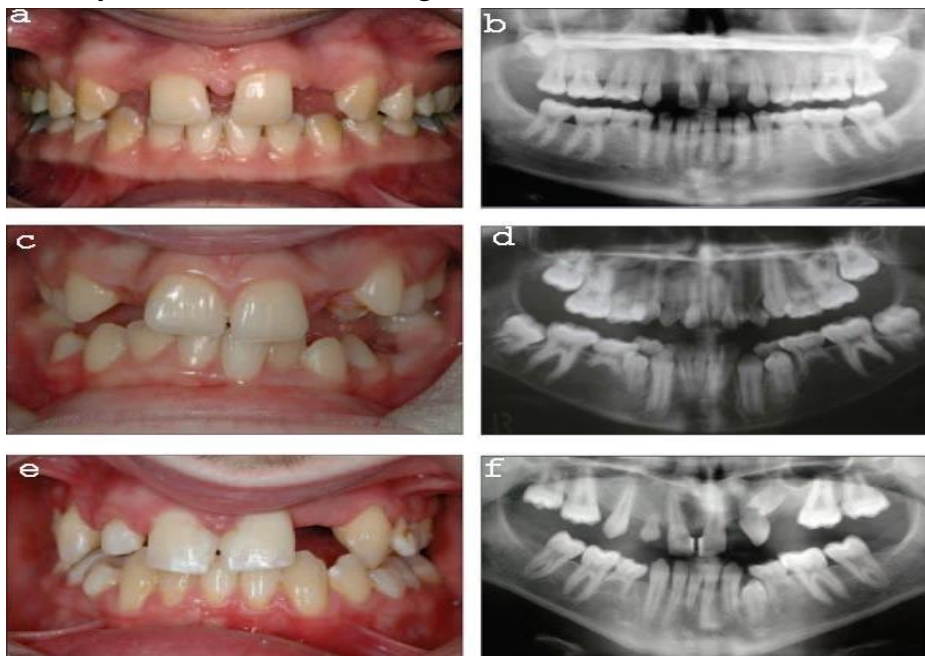### Butler's Field Theory

#### Local occlusal variables

##### □ Hypodontia

Hypodontia has a hereditary nature. Maxillary lateral incisor is the most common tooth to be congenitally missing, next to third molars followed by the second premolar. Hypodontia often exhibits familial occurrence and fits polygenic models of inheritance.

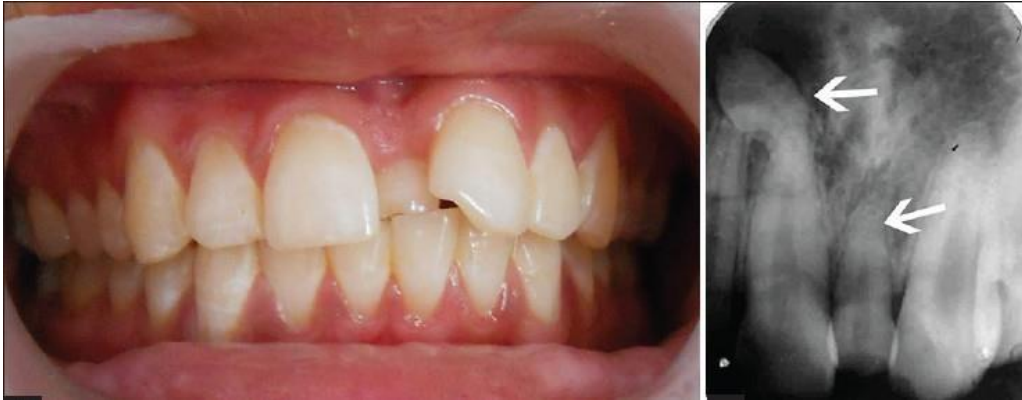Congenital absence of teeth and reduction in tooth size are associated, hypodontia and hypoplasia of maxillary lateral incisors frequently present simultaneously. Hypodontia and the reduction in tooth size are in fact controlled by the same or related gene loci.



Familial hypodontia, In the upper panel there is hypodontia with UR2, UL2, LL8, LL5, LR5 and LR8 absent. In the middle panel there is more severe hypodontia, with UR8, UR5, UR4, UL4, UL5, UL8, LR8, LR5, LL5 and LL8 absent. In the lower panel there is oligodontia, with the UR8, UR5, UR4, UR2, UL2, UL5, UL8, LL8, LL5, LL1, LR4, LR5, LR8 absent

### □ **Supernumerary**

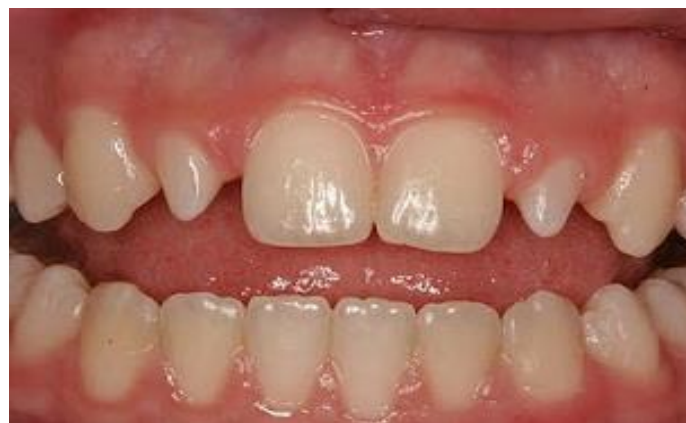Supernumerary teeth, most frequently seen on premaxillary region, also appears to be genetically determined. Mesiodens are more commonly present in parents and siblings of the patients who exhibit them. The mode of transmission could be explained by a single autosomal dominant gene.



**Supernumerary teeth (mesiodens)**

### □ **Tooth size and shape**

Studies have shown that tooth crown dimensions are strongly determined by heredity. As dietary habits in humans adapt from a hunter/gatherer to a defined food culture, evolutionary selection pressures are tending to reduce tooth volume, which is manifested in third molar, second premolar and lateral incisor "fields",



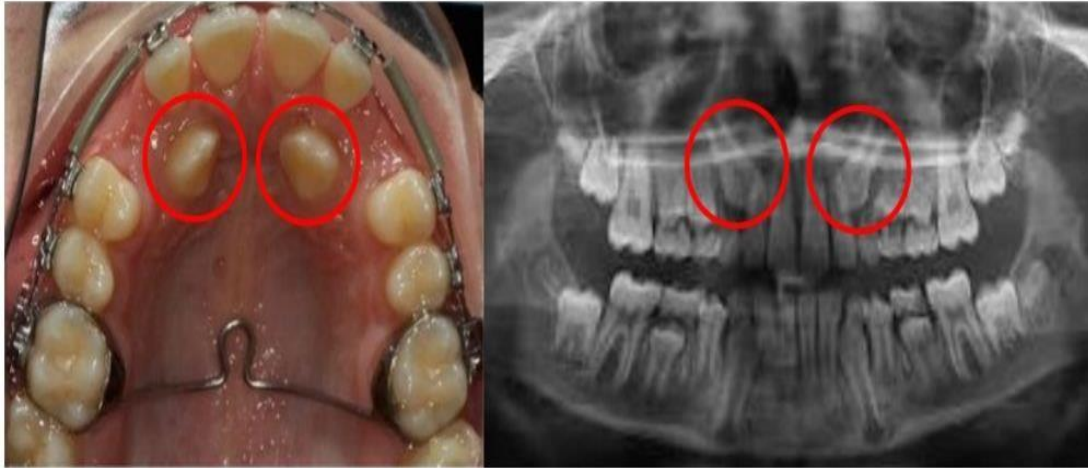**Peg shaped maxillary lateral incisors (bilateral red circles)**

### □ **Ectopic maxillary canine**

Various studies have indicated a genetic tendency for ectopic maxillary canine. Palatally ectopic canines have an inherited trait, being one of the anomalies in a complex and genetically related dental disturbances, often occurring in combination with missing teeth, microdontia, supernumerary



teeth and other ectopically positioned teeth. Studies have also shown an association between ectopic maxillary canines and class II malocclusion, which has a strong basis. In addition, tooth transposition most commonly affects maxillary canine/first premolar class position and shows a familial occurrence.



**Palatal bilateral ectopic maxillary canine, (red circles)**

### **Clinical Implications of Genetics in Orthodontics**

Malocclusion with a "genetic cause" is generally thought to be less responsive to treatment than those with an "environmental cause". The greater the genetic component, the worse the prognosis for a successful outcome by means of orthodontic intervention. However, knowing exactly the relative contribution of genetic and environmental factors is not always possible. Malocclusions of genetic origin (skeletal discrepancies) when detected in growing period, are being successfully treated using orthopaedic and functional appliances, except in extreme cases where surgical intervention is required. When malocclusion is primarily of genetic origin, for example, severe mandibular prognathism then treatment will be palliative or surgical. Examination of parents and older siblings can give information regarding the treatment need for a child and treatment can be begun at an early age.

*My great wishes for my lovely students for success. Thanks*

## Orthodontics

### *Development of occlusion*

The development of dentition is an important part of craniofacial growth as the formation, eruption, exfoliation and exchange of teeth take place during this period.

According to Angle occlusion is "The normal relation of the occlusal inclined planes of the teeth when the jaws are closed"

According to Ash and Ramfjord occlusion is the " The contact relationship of the teeth in function and parafunction"

Periods of Occlusal development can be divided into the following development periods:

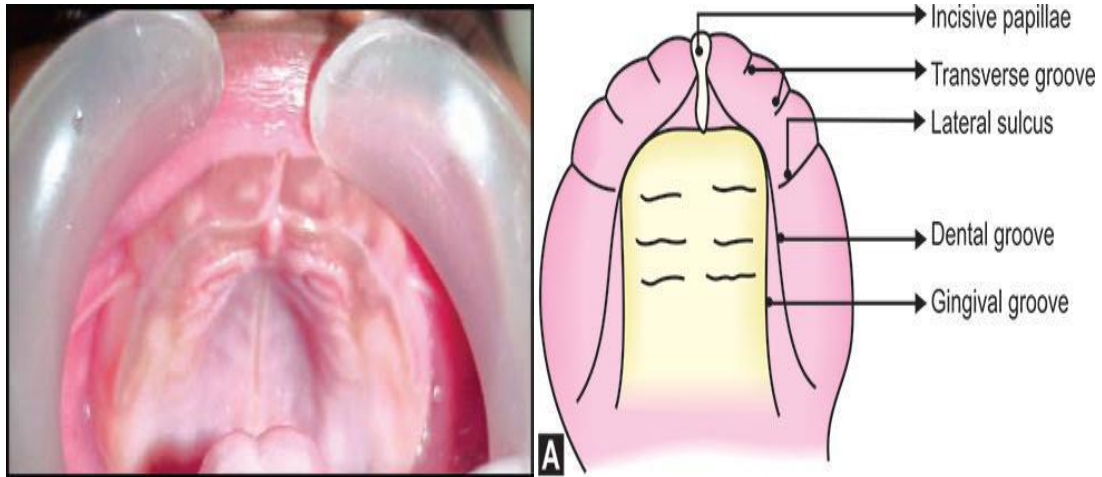
- 1-Neo-natal period (at birth).
- 2- Primary dentition period.
- 3- Mixed dentition period.
- 4- Permanent dentition period

### **Neonatal period**

Alveolar processes at the time of birth known as gum pads. Which is Pink in color, firm and are covered by a dense layer of fibrous periosteum , the pads get divided into 'labio- buccal' & 'lingual portion', by a **Dental groove**, and gum pad soon gets segmented into 10 segment by a groove called **Transverse groove**, & each segment is a developing tooth site. The groove between the canine and the 1st molar region is called the **lateral sulcus** which helps to judge the inter-arch relationship.

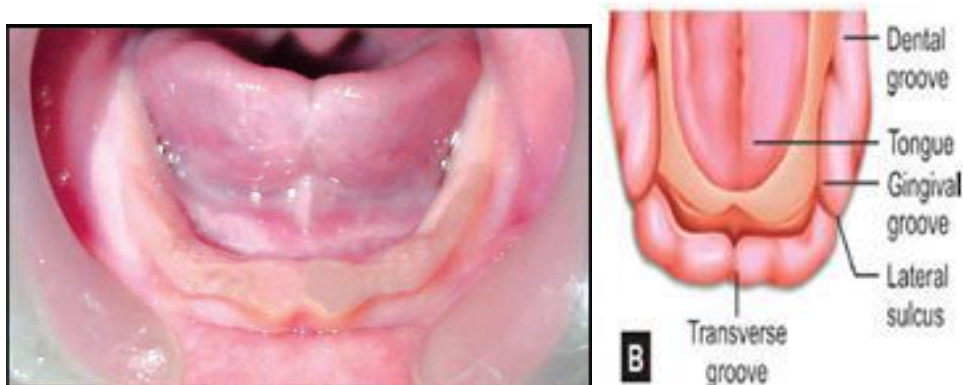
\* **The upper gum pad** is horse shoe shaped, shows

- Gingival groove separates gum pad from the palate
- Dental groove starts at the incisive papilla, extends backward to touch the gingival groove in the canine region & then moves laterally to end in the molar region
- Lateral sulcus.



**The lower gum pad:** U shaped , characterized by

- Gingival groove lingual extension of the gum pads
- dental groove
- Lateral sulcus.





## Relationship of Gum Pads

- ❖ Anterior open bite is seen at rest with contact only at the molar region.
- ❖ Upper gum pad being more wider and longer than lower gum pads thus when approximated a complete over jet present all around.
- ❖ Class II pattern with the maxillary gum pad being more prominent Mandible is distal to the maxilla and usually the upper jaw overlap the lower jaw in anterior posterior and transverse direction.
- ❖ Mandibular lateral sulci posterior to maxillary lateral sulci

The anterior opening of the mouth will facilitate the feeding process without discomfort to the mother, at this stage the labial frenum is usually attached to the incisive papillary region and after the eruption of the deciduous teeth it will migrate in upward direction and gives the incisive papillary attachment is due to alveolar bone formation in association with the development of deciduous teeth, the upper lip at this stage is usually short, and the anterior oral seal of the mouth occurs due to the contact between lower lip and the tongue.

## Neonatal Jaw Relationships

Mandibular functional movements are mainly vertical and to a little extent anteroposterior. Lateral movements are absent, precise bite or jaw relationship is not yet seen, therefore neonatal jaw relationship can not be used as a diagnostic criterion for reliable prediction of subsequent occlusion in primary dentition.

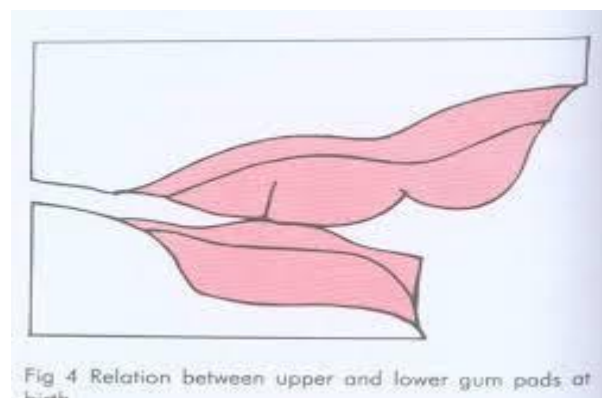


Fig 4 Relation between upper and lower gum pads at birth

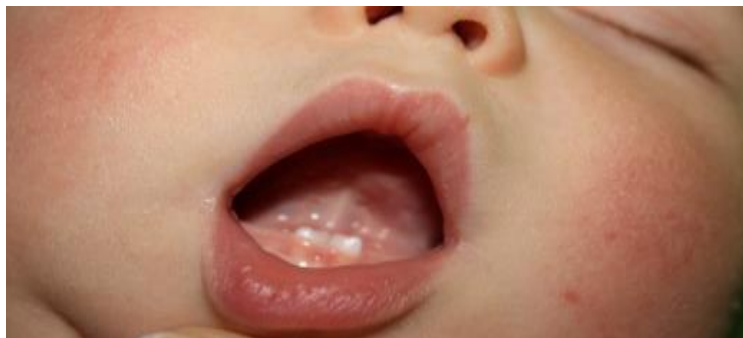The newly born child mouth is usually without teeth, sometimes Natal teeth that are present above the gumline (have already erupted) at birth.

Neonatal teeth or Early Infansive teeth that erupt during the 1st month of life these teeth look-like the deciduous teeth.

Pre-erupted teeth erupt during the second or third month.

they are contained enamel, dentine and pulpal tissue and usually without roots or there is a very short root with them. No intervention is usually recommended unless they are causing difficulty to the infant or mother .

The incidence of natal and neonatal teeth is estimated to be 1:1000and 1:30000respectively. These teeth are almost always mandibular incisors, which frequently display enamel hypoplasia. There are familial tendencies for such teeth. They should not be removed if normal but removed if supernumerary or mobile

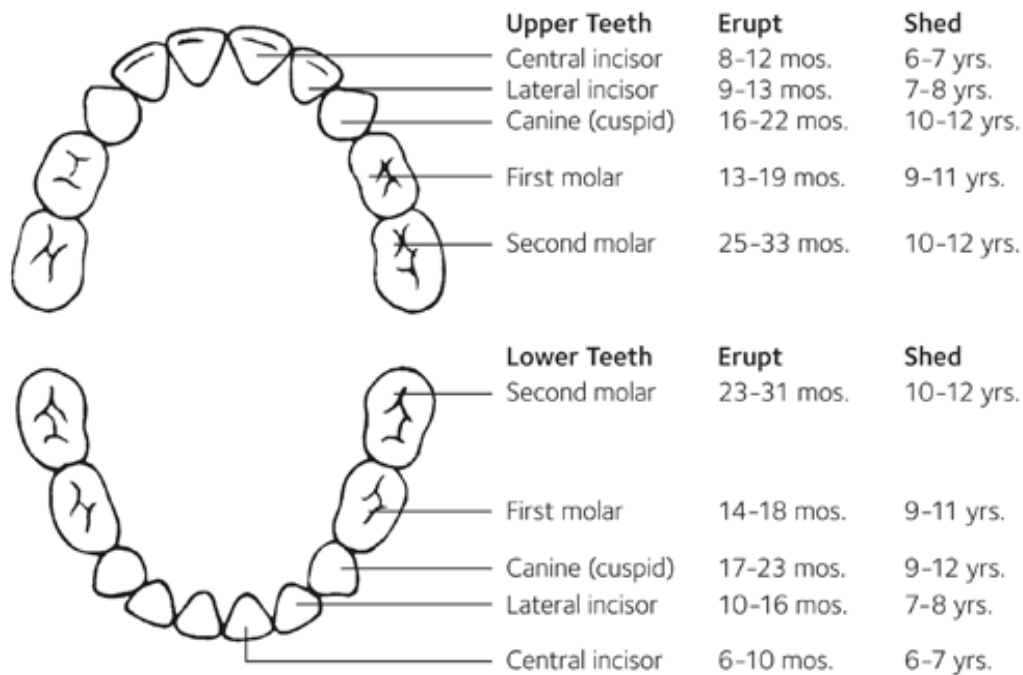


### **Deciduous Dentition**

**Deciduous teeth** or **primary teeth**, are the first set of teeth in the growth development of humans . They develop during the embryonic stage of development starts at the sixth week of tooth development as the dental lamina, there are ten buds on the upper and lower arches that will eventually become the primary (deciduous) dentition. These teeth will continue to form until they erupt and become visible in the mouth during infancy, there are a total of twenty teeth that is made up of central incisors, lateral incisors, canines, first molars, and secondary molars; there is one in each quadrant, making a total of four of each tooth: five

per quadrant and ten per arch. The eruption of these teeth (teething) starts from the eruption of the first deciduous tooth, usually the deciduous mandibular central incisors. By 2½ years of age, deciduous dentition is usually complete and in full function.

**The sequence of eruption and shedding of deciduous teeth**



**Normal Signs of Primary Dentition**

- 1-Ovoid arch form
- 2- Straight or vertical inclination of the incisors
- 3- Deep bite are present this could be duo to vertical inclination of primary incisors over aperiod of time these deep bite reduced duo to eruption of primary molars ,rapid attrition of incisors and forward movement of the mandible due to growth , and which change to edge to edge relationship
- 4-Minimal overjet and absence of crowding.

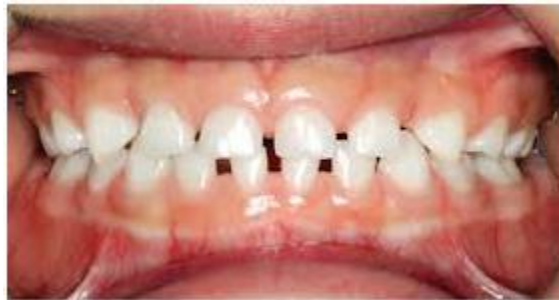**Two types of primary dentitions seen**

A- **Closed primary dentition:** absence of spaces is an indication that

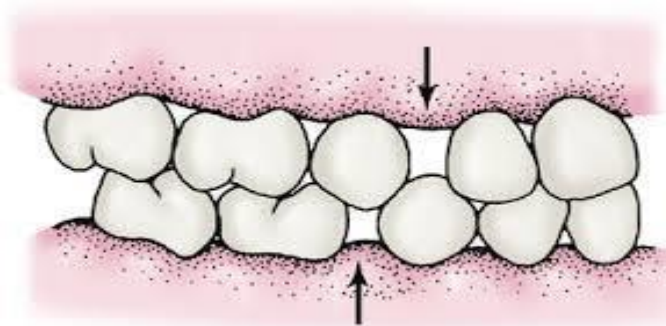
crowding of teeth may occur when the larger permanent teeth erupt.

**B- Spaced or opened primary dentition:** in which interdental spaces are present called spaced dentition there are 2 types of spacing.

**1- Physiologic or generalized spaces :** usually seen in the deciduous dentition to accommodate the larger permanent teeth in the jaws, more prominent in the anterior region.



**2- Primate spaces or anthropoid spaces:** naturally occurring spacing between the teeth of the primary dentition. In the maxillary arch, it is located between the lateral incisors and canines, where as in the mandibular arch the space is between the canines and first molars, This space is used for early mesial shift.



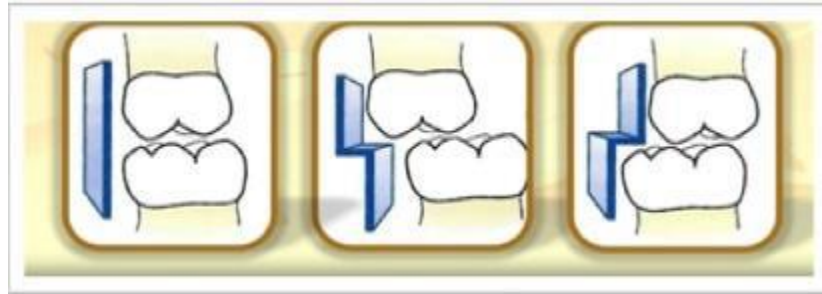molar relation in primary dentition described in terms of terminal planes, terminal planes are the distal surfaces of the 2nd primary molars, these two planes can be related in **3** ways:

**1- Flush terminal plane:** both maxillary and mandibular planes are at the same level anteroposteriorly, normal molar relationship in the primary dentition, because the mesiodistal width of the mandibular molar is greater than the mesiodistal width of the maxillary molar.

**2- Mesial terminal plane:** maxillary terminal plane is relatively more

posterior than the mandibular terminal plane forming a mesial step.

**3-Distal terminal plane:** the maxillary terminal plane is relatively more anterior to the mandibular.



All of primary teeth are gradually replaced with a permanent, but in the absence of permanent replacements, they can remain functional for many years. The replacement of primary teeth begins around age six, when the permanent teeth start to appear in the mouth, resulting in mixed dentition. The erupting permanent teeth cause root resorption, where the permanent teeth push on the roots of the primary teeth, causing the roots to be dissolved by odontoclasts (as well as surrounding alveolar bone by osteoclasts) and become absorbed by the forming permanent teeth. The process of shedding primary teeth and their replacement by permanent teeth is called **exfoliation**. This may last from age six to age thirteen. By age twelve there usually are only permanent teeth remaining. However, it is not extremely rare for one or more primary teeth to be retained beyond this age, sometimes well into adulthood, often because the permanent tooth fails to develop.

The spaces of the deciduous teeth try to increase with age due to growth of the jaws in anteroposterior, vertical, and transverse direction, and due to attrition, and these teeth subjected to large amount of attrition due to wear at the incisal edge, and proximal surfaces since the deciduous teeth mostly converted to edge to edge relationship at late stages, the occlusal forces with root resorption will increase the mobility of the deciduous teeth and

if the closed case ( no spacing) this will produce attrition at the proximal surfaces due to friction produced by movement during mastication, so the mobility progresses the spaces to increase and this will facilitate the normal shedding of the incisors.

### **Mixed Dentition period**

(Around 6 years- 13 years) Most malocclusions make their appearance during this stage. The mixed dentition period can be divided into:

1. First transitional period.
- 2- Inter-transitional period.
- 3- Second transitional period.

### **First Transitional Period**

Emergence of the first permanent molars and transition of incisors

The following events take place during this period.

### **Eruption of Permanent First Molars**

The first permanent molars erupt at 6 years. They play an important role in the establishing and in the functioning of occlusion, in the permanent dentition.

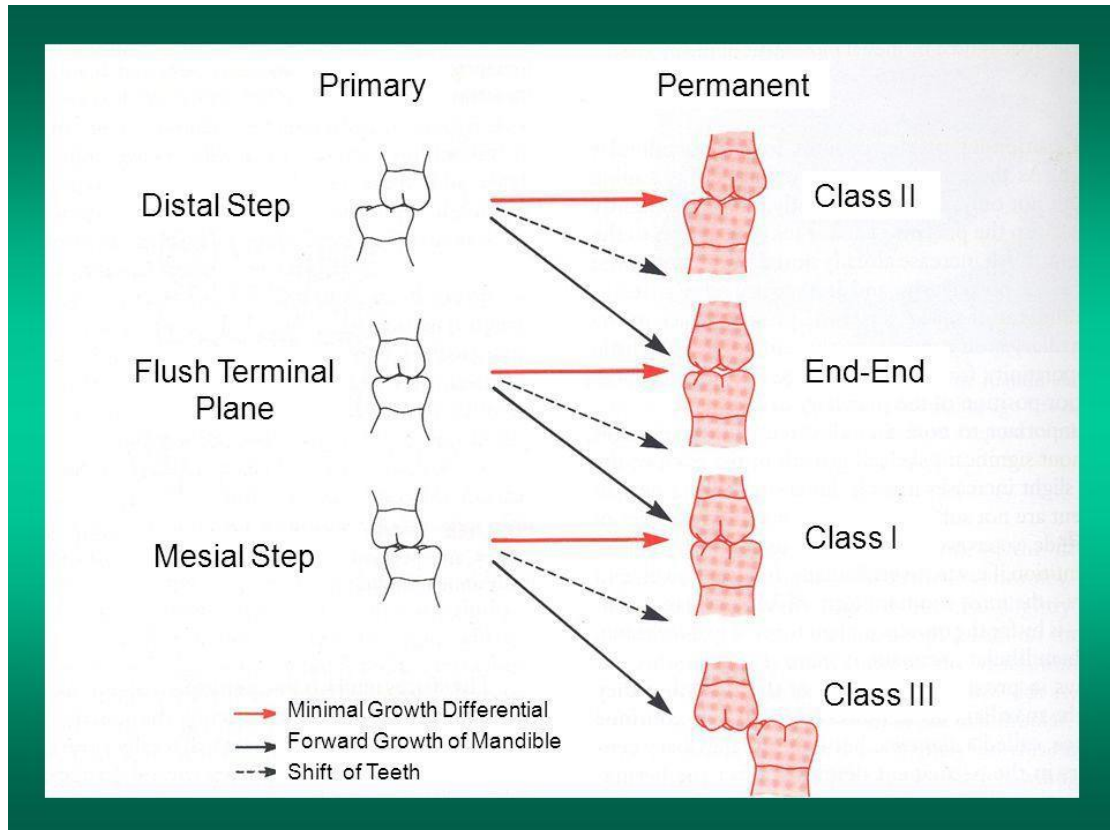
Anteroposterior positioning of the permanent molars is influenced by:

Terminal plane relationship the distal surface of the upper & lower 2nd deciduous molar. When the deciduous second molars are in a flush terminal plane, the permanent first molar erupts initially into a cusp-to-cusp relationship, which later transforms into a Class I molar relationship using the primate spaces. Later, cusp-to-cusp relationship of the permanent first molar can be converted to a Class I relationship by the mesial shift of the permanent first molar following exfoliation of the primary molar and thus making use of the Leeway space (late mesial shift)

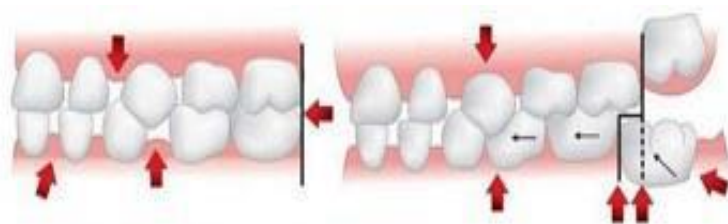
**Distal Step:** When the deciduous second molars are in a distal step, the permanent first molar will erupt into a class II relation. This molar

configuration is not self correcting and will cause a class II malocclusion despite Leeway space and differential growth.

**Mesial Step:** Primary second molars in mesial step relationship lead to a class I molar relation in mixed dentition. This may remain or progress to a half or full cusp class III with continued mandibular growth.

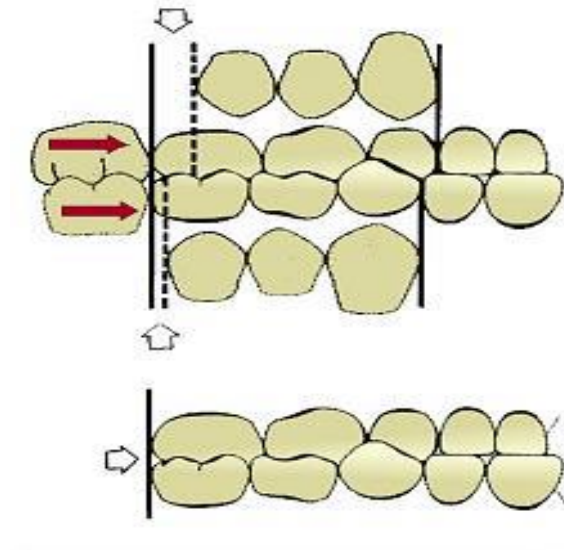


**Early mesial Shift :** Early shift occurs during the early mixed dentition period. Since this occurs early in the mixed dentition, it is called early shift , the eruptive force of first permanent molar push the deciduous 1st & 2nd deciduous molar to close the primate space. In a spaced arch, eruptive force of the permanent molars causes closing of any spaces between the primary molars or primate spaces, thus allowing molars to shift mesially





**Late mesial Shift:** This occurs in the late mixed dentition period when the second deciduous molar exfoliate the first permanent molar drift mesially & use leeway space and is thus called late shift. When the primary second molar are lost there is an adjustment in the occlusion of the first molar teeth, There is a decrease in arch length in both maxillary and mandibular arches as the first molar shift mesially this shift is more in mandible which accounts for the establishment of full cusp molar class I relation from flash terminal plane relation ship in deciduous .dentition this shift is called late mesial shift of molars.

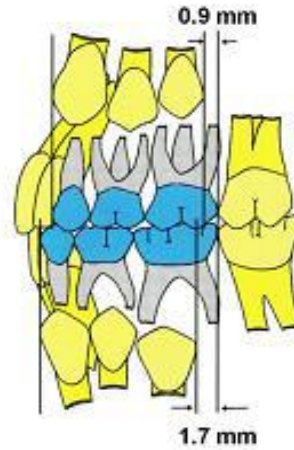
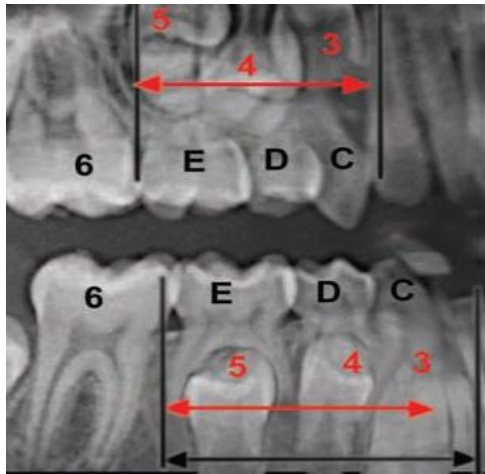


### **Leeway Space of Nance**

Described by Nance in 1947 (the combined mesiodistal width of the permanent canines and premolars 3,4 and 5 is usually less than of the deciduous canines and molars CD&E).

Maxilla: 0.9 mm/segment = 1.8 mm arch .

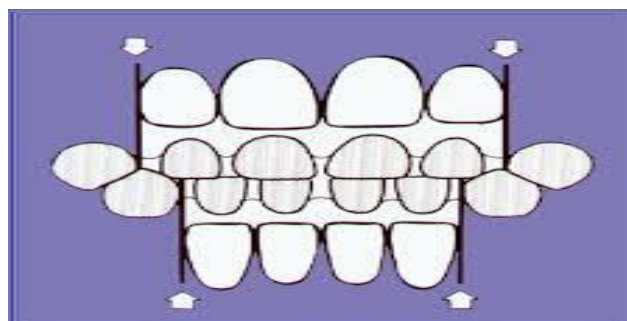
Mandible: 1.7 mm/segment = 3.4mm arch



### **Exchange of Incisors:**

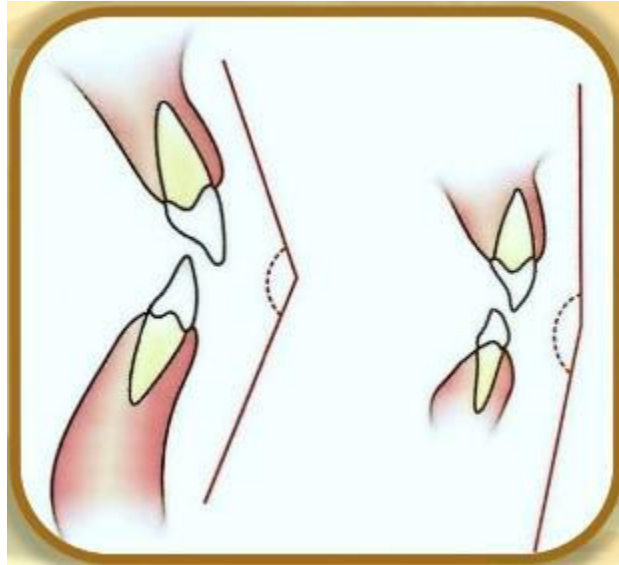
Transition of Incisors Permanent incisors develop lingual to the primary incisors. For incisors to erupt in normal alignment, there is an obligate space requirement in the anterior part of both the arches which is termed as the incisal liability (permanent incisors is larger than deciduous incisors the difference between the amount of space needed for the incisors and the amount available for them) is overcome by the following factors:

- 1- Interdental physiological spacing in the primary incisor region. (4 mm in maxillary arch & 3 mm in mandibular arch)
- 2-Increase in inter-canine arch width: Significant amount of growth occurs with the eruption of incisors and canines
- 3-Increase in anterior length of the dental arches: Permanent incisors erupt labial to the primary incisors to obtain an added space of around 2-3 mm, change in inclination of permanent incisors, Primary teeth are upright but permanent teeth incline to the labial surface. This increases the arch parameter .



**Change in inclination of permanent incisors:**

Primary teeth are upright but permanent teeth incline to the labial surface thus decreasing the inter-incisal angle from about  $150^\circ$  in the deciduous dentition to  $123^\circ$  in the permanent dentition This increases the arch perimeter



*My great wishes for my lovely students for success. Thanks*

## Orthodontics

### *Mixed Dentition period*

#### **Inter-Transitional Period**

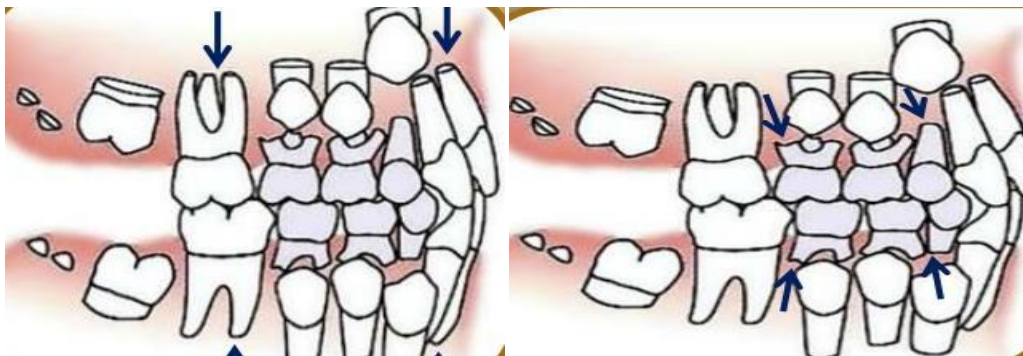
This is a stable phase where little changes take place in the dentition. The teeth present are the permanent incisors and first molar along with the deciduous canines and molars. Some of the features of this stage are:

1. Any asymmetry in emergence and corresponding differences in height levels or crown lengths between the right and left side teeth are made up.
2. Occlusal and interproximal wear of deciduous teeth causes occlusal morphology to approach that of a plane.
3. Ugly duckling stage.
4. Root formation of emerged incisors, canines and molars continues, along with concomitant increase in alveolar process height.
5. Resorption of roots of deciduous molars.

it is a silent period extend from 8.5 years of age to 10 years of age ,this period is called (Lull period) In this period ,the teeth present are

6EDC21 12CDE6

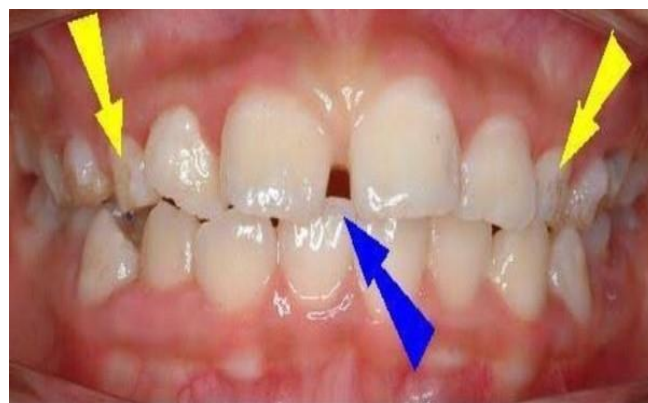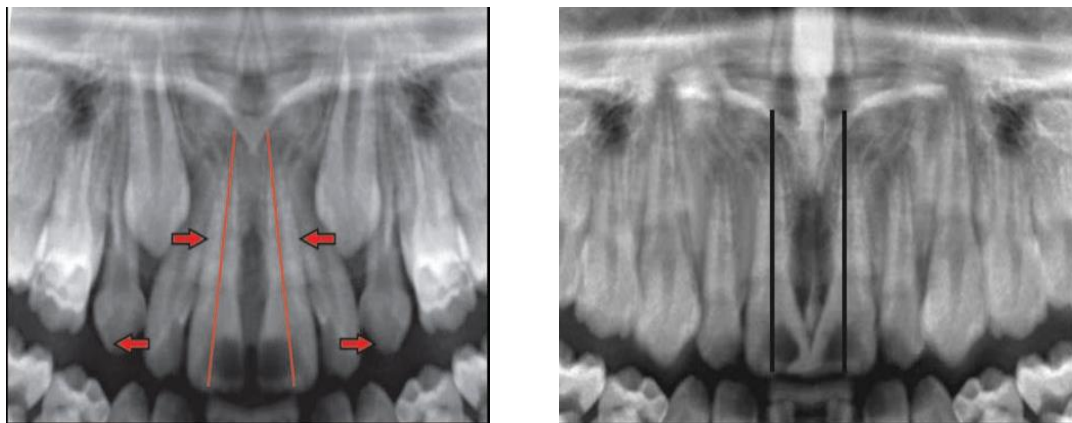
This phase prepares for the second transitional phase



### **Ugly Duckling Stage (Broadbent's phenomenon):**

Around the age of 8 - 9 years, a midline diastema is commonly seen in the upper arch, which is usually misinterpreted by the parents as a malocclusion. Its typical features are: Flaring of the lateral incisors.

Maxillary midline diastema, crowns of canines on young jaws impinge on developing lateral incisor roots, thus driving the roots medially and causing the crowns to flare laterally, the roots of the central incisors are also forced together, thus causing maxillary midline diastema , With the eruption of the canines, the impingement from the roots shift incisally thus driving the incisor crowns medially, resulting in closure of the diastema as well as the correction of the flared lateral incisors.



### **Second Transitional Period**

This period is marked by the eruption of the four permanent second molar, establishment of proper occlusion, replacement of deciduous canines and molars by permanent molars and permanent cuspid respectively.

**The following events take place:**

**1. Exfoliation of primary molars and canines** At around 10 years of age, the first deciduous tooth in the posterior region, usually the mandibular canine sheds and marks the beginning of the second transitional period. Usually no crowding is seen before emergence except maybe between the maxillary first premolar and canine.

**2. Eruption of permanent canines and premolars** These teeth erupt after a pause of 1-2 years following incisor eruption. The first posterior teeth to erupt are the mandibular canine and first premolar (9-10 years) followed by maxillary premolars and canine around 11-12 years. Most common eruption sequence is 4-5-3 in the maxilla and 3-4-5 in the mandible. Favorable occlusion in this region is largely dependent on:

- Favorable eruption sequence.
- Satisfactory tooth size- available space ratio.
- Attainment of normal molar relation with minimum diminution of space available for bicuspids.

**3. Eruption of permanent second molars:** the eruption of second permanent molars(upper&lower) at the age of 12 years old, it takes along path of eruption, but less than the path of eruption of canine,so ,they subjected to less amount of crowding, the malocclusion of second molars is very rare,and their impaction very rare,but sometimes the lower second molars may be impacted, Before emergence second molars are oriented in a mesial and lingual direction. These teeth are formed palatally and are guided into occlusion by the Cone Funnel mechanism (the upper palatal cusp/cone slides into the lower occlusal fossa/funnel). The arch length is reduced prior to second molar eruption by the mesial eruptive forces. Therefore, crowding if present is accentuated

## **Mixed dentition problems**

### ***1-Premature loss of deciduous teeth***

The major effect of early loss of a primary tooth, whether due to caries, premature exfoliation, or planned extraction, is localization of preexisting crowding. In an uncrowded mouth this will not occur. However, where some crowding exists and a primary tooth is extracted, the adjacent teeth will drift or tilt around into the space provided. The extent to which this occurs depends upon the degree of crowding, the patient's age, and the site.

### ***2-Retained deciduous teeth***

A difference of more than 6 months between the shedding of contralateral teeth should be regarded with suspicion. Provided that the permanent successor is present, retained primary teeth should be extracted, particularly if they are causing deflection of the permanent tooth.

### ***3- Infra-occluded (submerged) primary molars***

term for describing the process where a tooth fails to achieve or maintain its occlusal relationship with adjacent or opposing teeth.

### ***4- Impacted first permanent molars***

### ***5- Dilaceration***

Dilaceration is a distortion or bend in the root of a tooth. It usually affects the upper central and/or lateral incisor

### ***6- Supernumerary teeth***

### ***7- Habits***

### ***8- First permanent molars of poor long-term prognosis***

### ***9- Median diastema***

## ***The Permanent Dentition***

**Permanent teeth** or adult teeth are the second set of teeth formed in mammals. In humans, there are thirty-two permanent teeth, consisting of six maxillary and six mandibular molars, four maxillary and four



mandibular premolars, two maxillary and two mandibular canines, four maxillary and four mandibular incisors. The first permanent tooth usually appears in the mouth at around six years of age, and the mouth will then be in a transition time with both primary (or deciduous dentition) teeth and permanent teeth during the mixed dentition period until the last primary tooth is lost or shed. The first of the permanent teeth to erupt are the permanent first molars, right behind the last 'milk' molars of the primary dentition. These first permanent molars are important for the correct development of a permanent dentition. Up to the age of thirteen years, twenty-eight of the thirty-two permanent teeth will appear. The full permanent dentition is completed much later during the permanent dentition period. The four last permanent teeth, the third molars, usually appear between the ages of 17 and 25 years; they are considered wisdom teeth.

Calcification of permanent begins at birth with the calcification of the cusps of the first permanent molar and extends as late as the 25th year of life. Complete calcification of incisor crowns take place by 4 – 5 years and of the other permanent teeth by 6 – 8 years except for third molars, at approximately 13 years of age all permanent teeth except third molars are fully erupted,

The permanent incisors develop lingual to the deciduous incisors and move labially as they erupt. The premolars develop below the diverging roots of the deciduous molars.

The third molars erupt at 18-25 years of age, Their path of eruption is nearly similar to the path of eruption of the second molars. The upper molars developed at the posteroinferior position of the maxillary tuberosity, so, these teeth are subjected to a high amount of crowding in comparison with the first or second molars due to the lack of space available for them. The lower third molars may be subjected to impaction

due to lack of space, these teeth may be absent or congenitally missing.

**Features of the permanent dentition:**

- Coinciding midline.
- Class I molar relationship of the permanent first molar.
- Vertical overbite of about one-third the clinical crown height of the mandibular central incisors

**The sequence of Permanent teeth emergence:**

There is wide variability in the sequence of arrival of teeth in the mouth.

*Maxilla 6-1-2-4-3-5-7 or 6-1-2-4-5-3-7 (most common)*

*Mandible 6-1-2-4-5-3-7 or 6-1-2-3-4-5-7 (most common)*

**Dental age 6: First stage of eruption**

- Eruption of mandibular central incisor and permanent first molar
- Mandibular molar eruption precedes maxillary molar.

**Dental age 7**

- Eruption of maxillary central and mandibular lateral incisor.
- Root formation of maxillary lateral incisor well advanced.
- Crown completion of canines and premolars.

**Dental age 8**

- Eruption of maxillary lateral incisor.
- Delay of 2-3 years before any further teeth erupt.

**Dental age 9**

- One-third root formation of mandibular canine and first premolar is complete.
- Root development of mandibular second premolar begins.

**Dental age 10**

- One-half root formation of mandibular canine and first premolar is complete.
- Significant root development of maxillary and mandibular second premolar as well as maxillary canine.

- Root completion of mandibular incisors and near completion of maxillary laterals.
- According to Moyers, mandibular canine erupts between 9 and 10 years.

### Dental age 11

- Eruption of mandibular canine, mandibular first premolar and maxillary first premolar.
- Maxillary first premolar erupts ahead of canine and second premolar.

### Dental age 12

- Remaining succedaneous teeth erupt.
- Second permanent molars nearing eruption
- Early beginnings of third molar

### Dental age 13,14,15

- Completion of roots of permanent teeth
- Third molars apparent on the radiograph Change in eruption sequence is a reliable sign of disturbance in normal development of the dentition

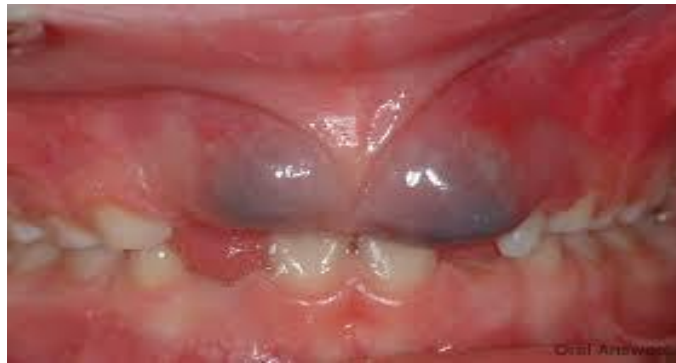|                         | Calsification(months) | Eruption(years) |
|-------------------------|-----------------------|-----------------|
| <b>Maxillary teeth</b>  |                       |                 |
| Central incisor         | 3-4                   | 7-8             |
| Lateral incisor         | 10-12                 | 8-9             |
| canine                  | 4-5                   | 11-12           |
| First premolar          | 18-21                 | 10-11           |
| Second premolar         | 24-27                 | 10-12           |
| First molar             | Around birth          | 5-6             |
| Second molar            | 30-36                 | 12-13           |
| Third molar             | 84-108                | 17-25           |
| <b>Mandibular teeth</b> |                       |                 |
| Central incisor         | 3-4                   | 6-7             |
| Lateral incisor         | 3-4                   | 7-8             |
| canine                  | 4-5                   | 9-10            |
| First premolar          | 21-24                 | 10-12           |
| Second premolar         | 27-30                 | 11-12           |
| First molar             | Around birth          | 5-6             |
| Second molar            | 30-36                 | 12-13           |
| Third molar             | 96-120                | 17-25           |

Root development complete 2–3 years after eruption

## *Abnormalities of eruption and exfoliation*

### **1-Eruption cyst**

An eruption cyst is caused by an accumulation of fluid or blood in the follicular space overlying the crown of an erupting tooth. They usually rupture spontaneously, but very occasionally marsupialization may be necessary.



### **2-Failure of/delayed eruption**

There is a wide individual variation in eruption times, Where there is a generalized tardiness in tooth eruption in an otherwise fit child, a period of observation is indicated. However, the following may be indicators of some abnormality and therefore warrant further investigation:

1-A disruption in the normal sequence of eruption.

2-An asymmetry in eruption pattern between contralateral teeth. If a tooth on one side of the arch has erupted and 6 months later there is still no sign of its equivalent on the other side, radiographic examination is indicated.

Localized failure of eruption is usually due to mechanical obstruction – this is advantageous as if the obstruction is removed then the affected tooth/teeth has the potential to erupt. More rarely, there is an abnormality of the eruption mechanism, which results in primary failure of eruption (the tooth does not erupt into the mouth) or arrest of eruption (the tooth erupts, but then fails to keep up with eruption/ development).

This problem usually affects molar teeth and unfortunately for the

individuals concerned, commonly affects more than one molar tooth in a quadrant. Extraction of the affected teeth is often necessary.

## **FACTORS DETERMINING TOOTH POSITION DURING ERUPTION**

Tooth passes through four distinct stages of development:

**1. *Pre-eruptive*** Initially position of tooth germ is dependent on heredity.

**2. *Intra-alveolar*** Tooth position is affected by-

- Presence or absence of adjacent teeth
- Rate of resorption of primary teeth
- Early loss of primary teeth
- Localized pathologic conditions.

**3. *Intraoral stage*** Tooth can be moved by lip, cheek, tongue muscles or external objects and drift into spaces.

**4. *Occlusal stage*** Muscles of mastication exert influence through interdigitation of cusps. The periodontal ligament disseminates the strong forces of chewing to the alveolar bone.

## **DISTURBANCES DURING ERUPTION OF TEETH**

1. Concrescence Cemental union of two teeth.

2. Retarded eruption Due to endocrine disturbances, vitamin deficiencies, local causes

3. Ankylosed teeth Teeth fail to erupt to the occlusal level as they are fused to the bone.

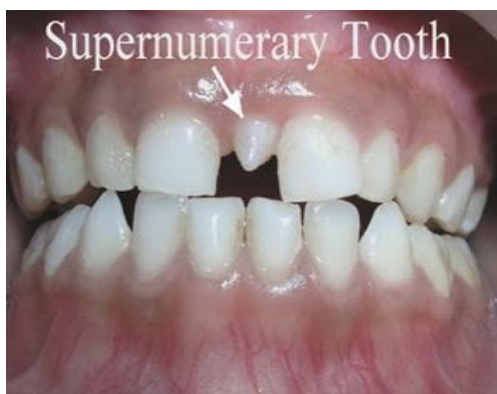Causes of delayed eruption

### **Generalized causes**

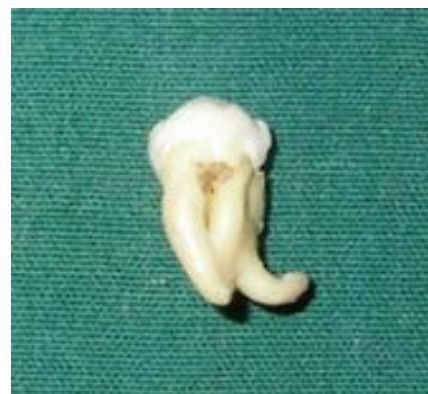- Hereditary gingival fibromatosis
- Down syndrome
- Cleidocranial dysostosis
- Cleft lip and palate
- Rickets

### Localized causes

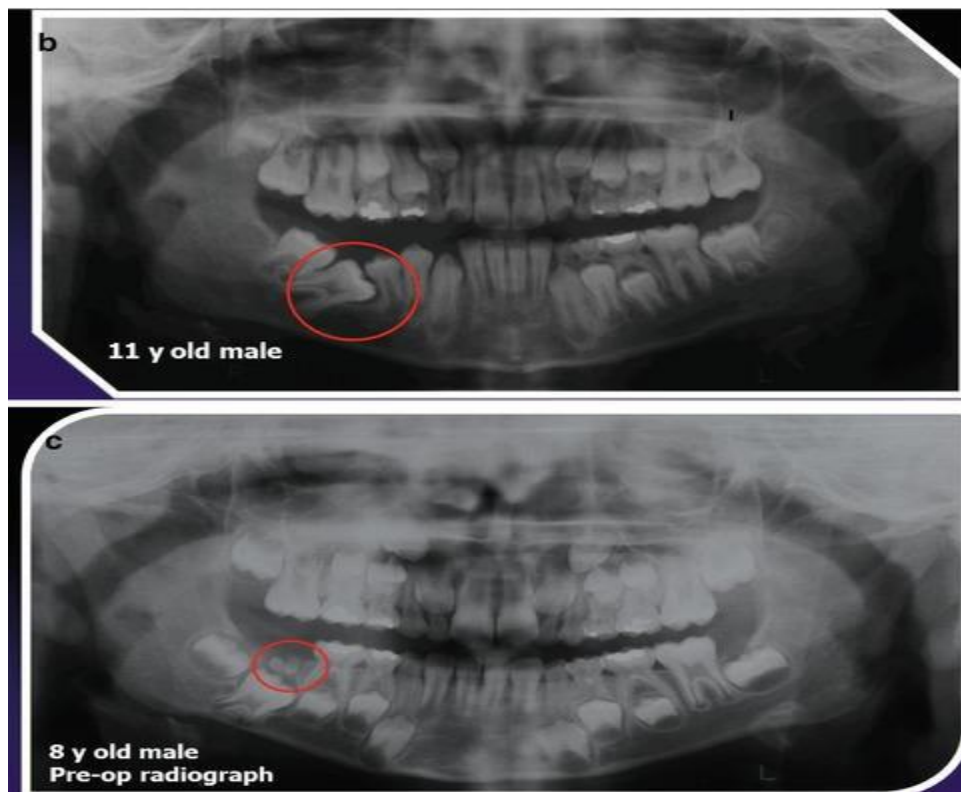
- Congenital absence
- Crowding
- Delayed exfoliation of primary predecessor
- Supernumerary tooth
- Dilaceration
- Abnormal position of crypt
- Primary failure of eruption



Supernumerary tooth



dilaceration



Primary failure of eruption

## **What to refer and when**

### ***\*\*Deciduous dentition***

- Cleft lip and/or palate (if patient not under the care of a cleft team)
- Other craniofacial anomalies

### ***\*\*Mixed dentition***

- Severe Class III skeletal problems which would benefit from orthopaedic treatment
- Delayed eruption of the permanent incisors
- Impaction or failure of eruption First permanent molars of poor long-term prognosis where forced extraction is being considered
- Marked mandibular displacement on closure and/or anterior crossbites
- Ectopic maxillary canines
- Patients with medical problems where monitoring of the occlusion would be beneficial
- Pathology e.g. cysts on of the first permanent molars

***My great wishes for my lovely students for success. Thanks***



# Orthodontics

## *Development of Dentition*

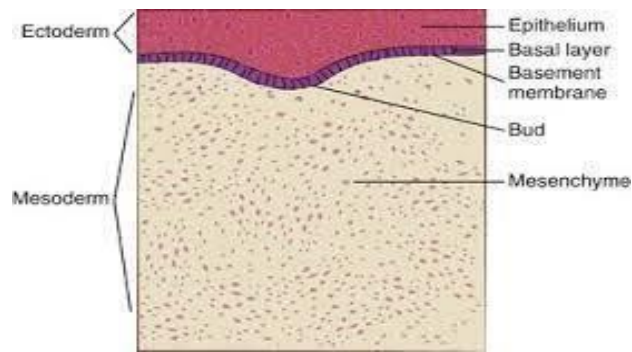
### **Prenatal Development of Dentition**

The embryonic oral cavity is lined by stratified squamous epithelium called the *oral ectoderm*, which is visible around 28-30 days of intrauterine life.

The first sign of tooth development appears late in the 3rd embryonic week when the epithelial lining begins to thicken on the inferior border of the maxillary process and the superior border of the mandibular process which join to form the lateral margins of the oral cavity.

At 6 weeks, four maxillary odontogenic zones coalesce to form the dental lamina and the two mandibular zones fuse at the midline. The dental lamina is the foundation for the future dental arches. Tooth formation begins with invagination of the dental lamina epithelium into the underlying mesenchyme at specific locations. The dental lamina gets demarcated into ten knoblike structures namely the tooth bud/germ.

A tooth bud (Fig. 1) consists of an enamel organ, which is derived from the oral ectoderm, a dental papilla and a dental sac, both of which are derived from the mesenchyme. Each of these swellings of the lamina proliferates and differentiate, passing through various histological and morphological differentiation stages namely bud, cap and bell stages.

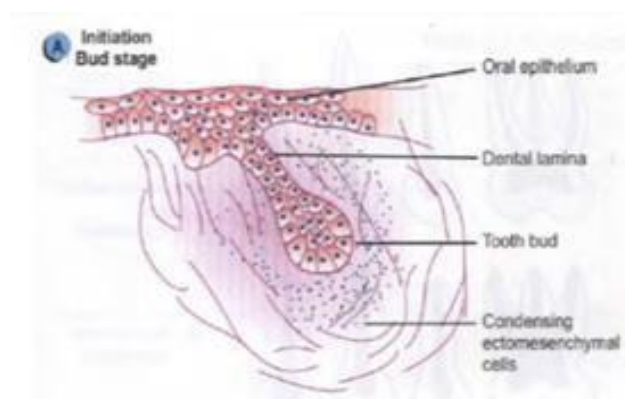


**Figure no.1 tooth bud**

### ***Stages of Tooth Bud Development***

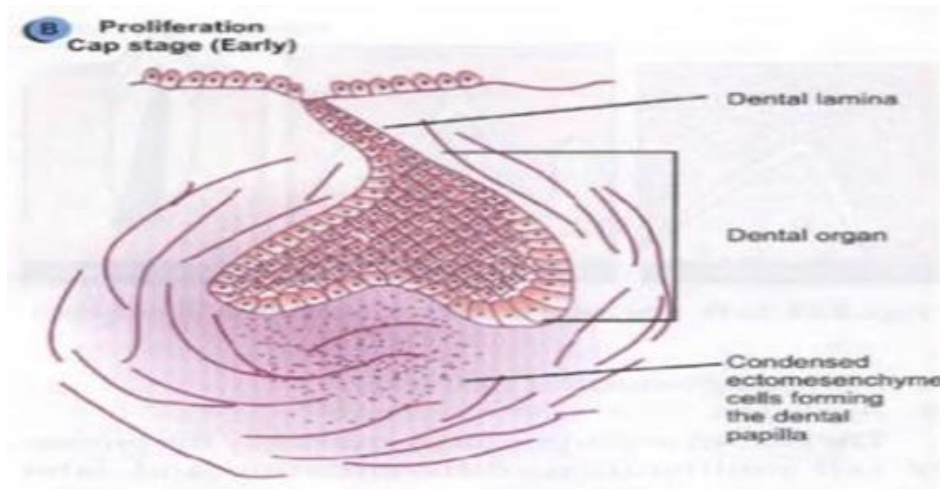
**1. Initiation:** This is the first epithelial incursion into the ectomesenchyme of the jaw. The tooth bud is the primordium of the enamel organ. Histologically it consists of peripheral low columnar cells and centrally located polygonal cells. The area of ectomesenchymal condensation subjacent to the bud is the dental papilla. The dental sac surrounds the tooth bud and the dental papilla. The dental papilla later on forms the dentin and pulp whereas the dental sac forms cementum and the periodontal ligament. Initiation takes place as follows:

- Deciduous dentition: 2nd month *in utero*.
- Permanent dentition: Growth of the free distal end of dental lamina gives rise to the successional lamina, which initiates the permanent dentition; starts from 5th month *in utero*.
- Dental lamina elongates distal to the second deciduous molar and gives rise to the permanent molar tooth germs.



**Figure no.2 Initiation stage**

**2. Proliferation:** Unequal growth in different parts of the bud produces a shallow invagination on the deep surface of the bud to produce a cap shaped structure. Histologically it is made up of the outer enamel epithelium (cuboidal cells) at the convexity of the cap and the inner enamel epithelium (tall, columnar cells) at the concavity of the cap. Between the above 2 layers polygonal cells are located which is known as the stellate reticulum. These cells assume a branched reticular network as more intercellular fluid is produced.



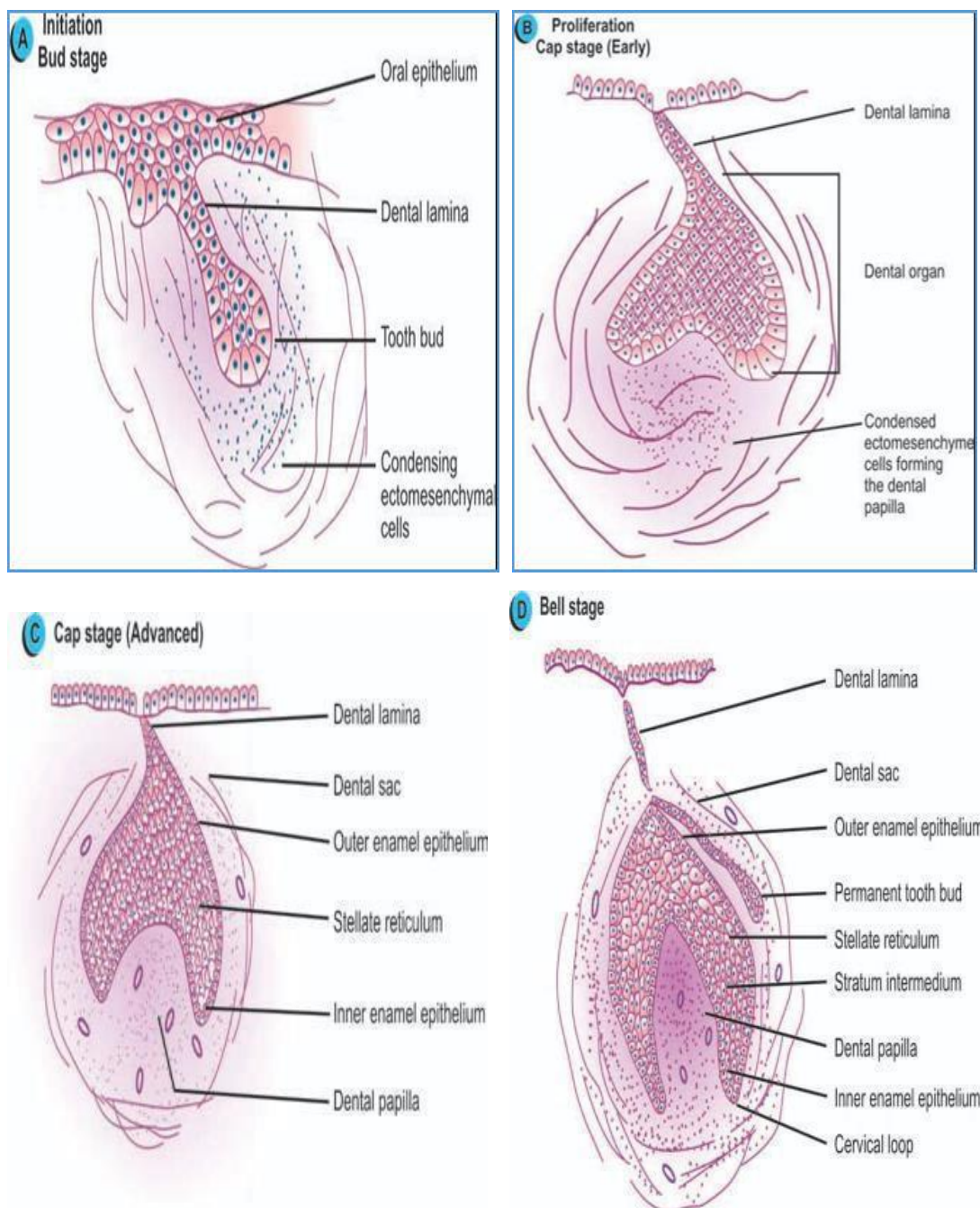
**Figure 3: Proliferation stage**

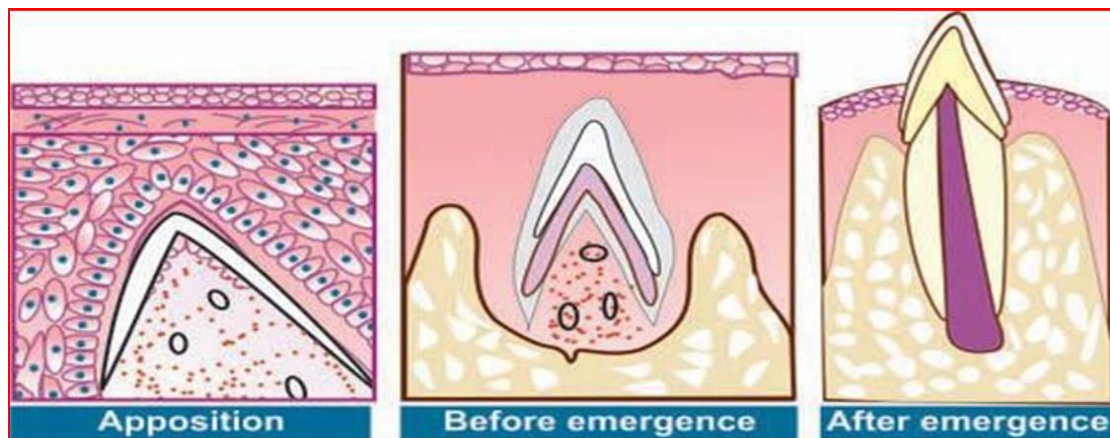
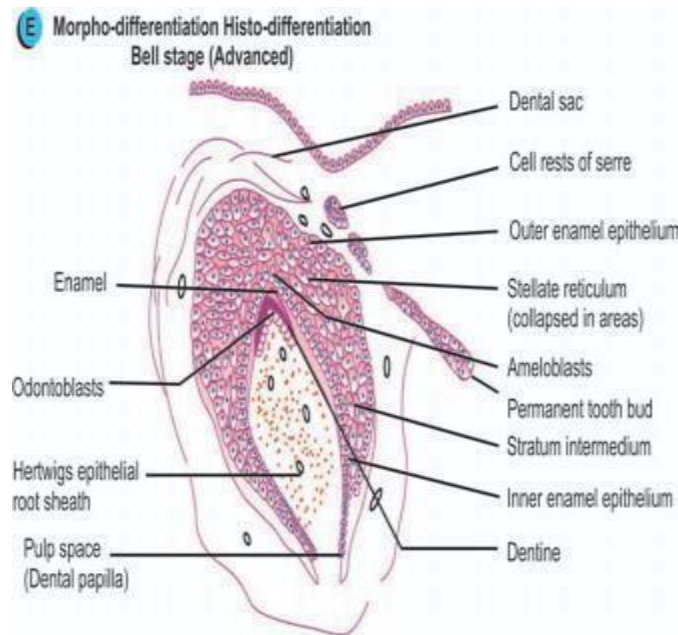
**3. Histo-differentiation:** The enamel organ now assumes a bell shape as the invagination of the cap continues and the margins grow longer. Four different layers are seen. The inner enamel epithelium (IEE) cells remain tall columnar cells. The outer enamel epithelium flatten to low cuboidal cells. The stellate reticulum expands further and the cells become star shaped. A new layer of cells known as Stratum Inter medium whose function is to provide nutrition to IEE cells appears between inner enamel epithelium and stellate reticulum.

**4. Morpho-differentiation (bell stage)**

## 5. Apposition

The enamel organ produces enamel by the process of cell proliferation, differentiation and later mineralization. Mineralization commences in the deciduous dentition around the 14th week of intrauterine life and occurs first in the central incisors. The permanent tooth buds appear around the fourth to fifth month of intrauterine life and their mineralization is initiated at birth, beginning with the first permanent molar





**Figure no.4 A to H: Life cycle of tooth**

## **Eruption**

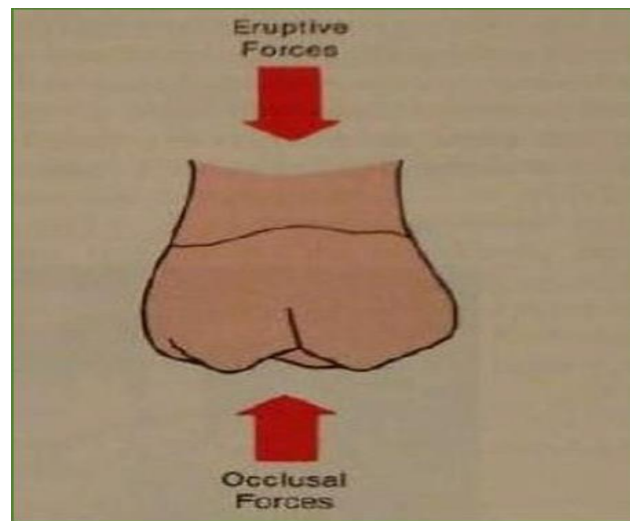
Eruption is the developmental process that moves a tooth from its crypt position through the alveolar process into the oral cavity and to occlusion with its antagonist. During eruption of succedaneous teeth:

- Primary tooth resorbs
- Roots of the permanent teeth lengthen
- Increase in the alveolar process height
- Permanent teeth move through the bone.

Teeth do not begin to move occlusally until crown formation is complete. It takes 2-5 years for posterior teeth to reach the alveolar crest following crown completion and 12-20 months to reach occlusion after reaching



alveolar margin.



**Figure 5: Eruption**

## **THEORIES OF ORIGIN OF MAMMALIAN TEETH**

### **THEORY OF CONCRESCENCE**

Mammalian dentition was produced by the fusion of two or more primitive conical teeth and each tubercle with its root originated as simple reptilian tooth.

### **THEORY OF TRITUBERCULY**

Each of the mammalian tooth was derived from a single reptilian tooth by secondary differentiation of tubercles and roots.

### **THEORY OF MULTI-TUBERCULY**

Mammalian dentition is a result of reduction and condensation of primitive multi-tuberculate teeth.

In terms of evolution, teeth are said to have developed from lobes or primary centrals. Incisors, premolars and maxillary molars developed from 4 lobes whereas mandibular molars developed from 5 lobes

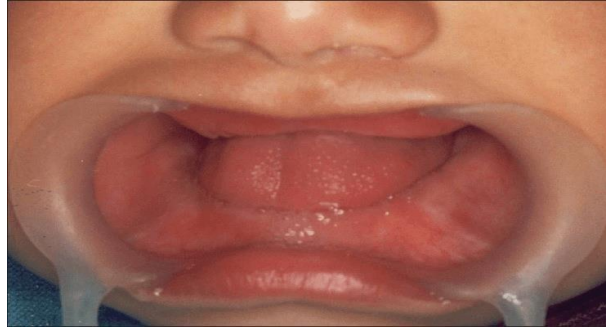### ***Developmental Disturbances Affecting The Teeth***

#### **Disturbances During Initiation Of Tooth Germs**

1. *Ectodermal dysplasia* Complete or partial anodontia of both the dentitions along with the presence of malformed teeth.



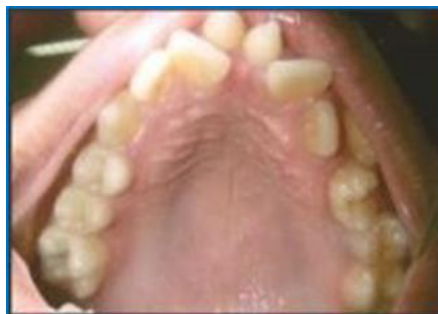2. *Anodontia* Absence of 1 or more teeth due to failure of tooth bud initiation. Most commonly missing teeth are third molars followed by mandibular second premolars, maxillary lateral incisor and maxillary second premolars.



**Figure no,6 Anodontia**

*Supernumerary and supplemental teeth:* teeth in excess of the normal complement of teeth. The difference between the two is that supplemental teeth resemble normal teeth whereas supernumerary teeth do not, e.g. of supernumerary teeth.

*Mesiodens :* between maxillary central incisors.



**Figure no.7 Mesioden**

- *Peridens :* located buccal to the arch
- *Distomolar :* distal to the third molar.
- *Paramolar:* located buccal or lingual to molars.

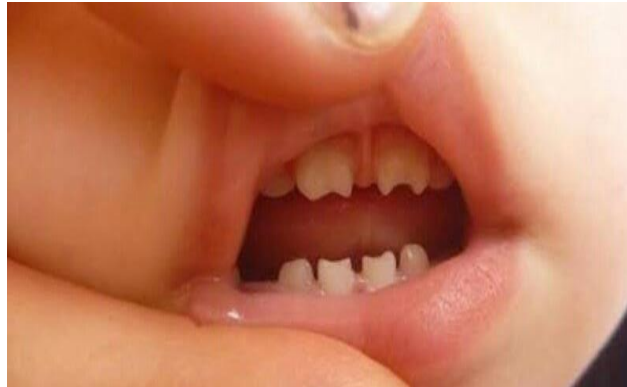3. *Natal and neonatal teeth:* These may be either supernumerary or deciduous teeth.

4. *Pre deciduous dentition:* Aborted structures with caps of enamel and dentine.

5. *Post permanent dentition*: Teeth erupt after the loss of the permanent dentition, usually impacted accessory teeth.

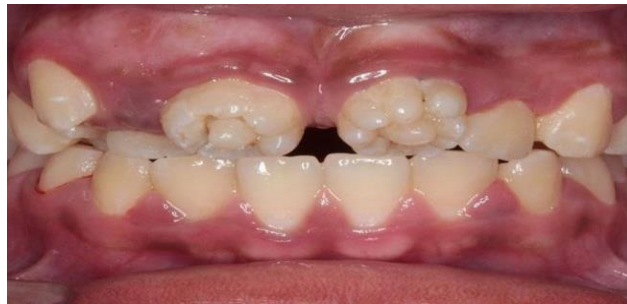### **Disturbances During Morpho differentiation of Tooth Germs**

1. Hutchinson's incisors: Screwdriver shaped notched incisors, e.g. in congenital syphilis.



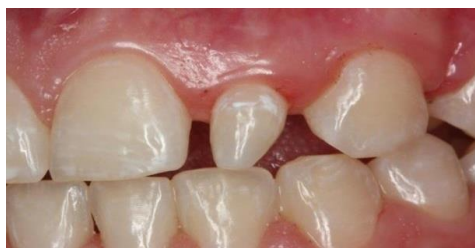**Figure no.8 Hutchinson's incisor**

2. Mulberry molars : Occlusal surface is narrower than the cervical margin and is made up of agglomerate mass of globules; seen in congenital syphilis.



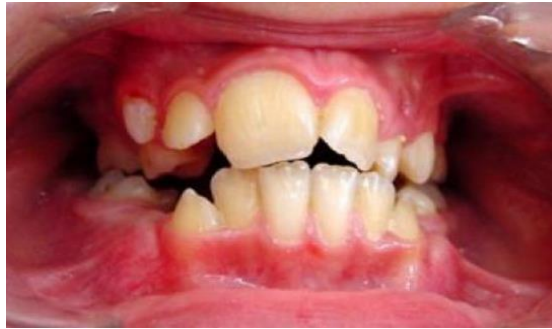**Figure no.9 Mulberry molars.**

3- Peg shaped laterals: Proximal surfaces of the crown converge giving the tooth a conical shape.



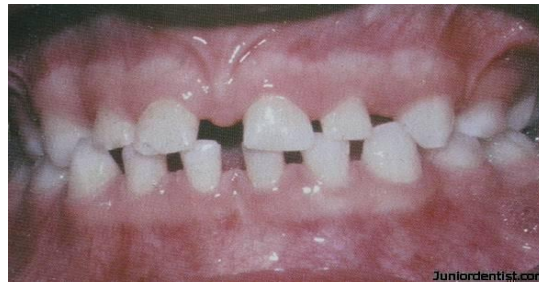**Figure no.10 Peg shaped laterals**

3. MacrodoniaTeeth: larger than normal. It may be true or relative generalized.



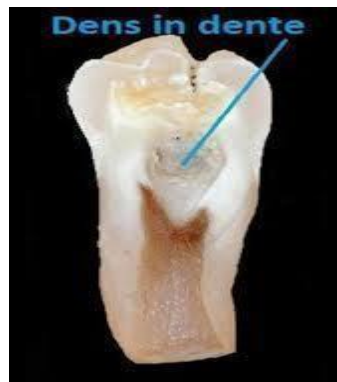
**Figure no.11 Macrodonia Teeth**

4. MicrodoniaTeeth: smaller than normal. It may be true or relative generalized; most commonly the lateral incisor and third molars.



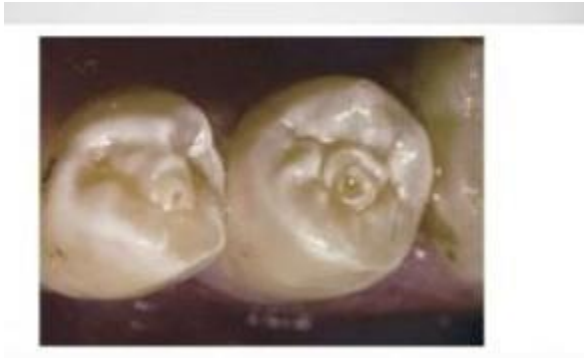**Figure no.12 Microdonia Teeth**

5. Dens in dente: Tooth invaginates before calcification, e.g. permanent maxillary lateral incisor.



**Figure no. 13 Dens in dente.**

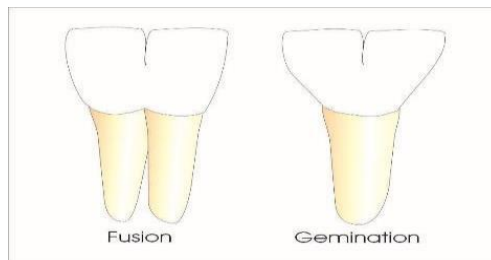6. *Dens evaginatus*: A tubercle or protruberance from the involved surface of the affected tooth; occurs due to proliferation or evagination of part of the inner enamel epithelium into the stellate reticulum. Seen in premolars.



**Figure no. 14 Dens evaginatus**

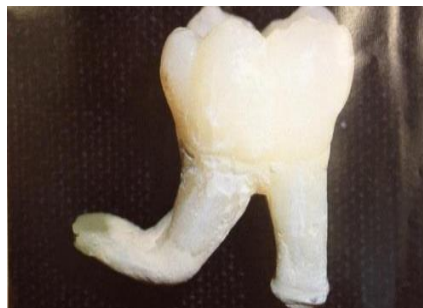7. *Gemination* : Single tooth germ splits into partially or fully separated crowns but with a common root and root canal.

8. *Fusion* Two tooth germs unite to form a single large crown with two root canals; seen in incisors.



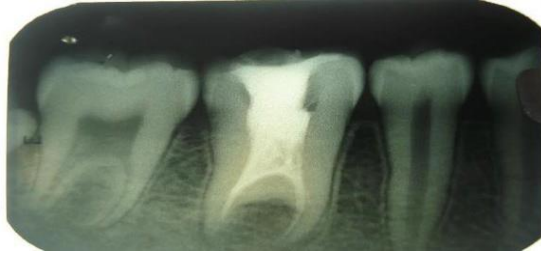**Figure no.15 Gemination and Fusion**

9. *Dilaceration*: Twisting, bending or distortion of a root.



**Figure 16: Dilaceration**

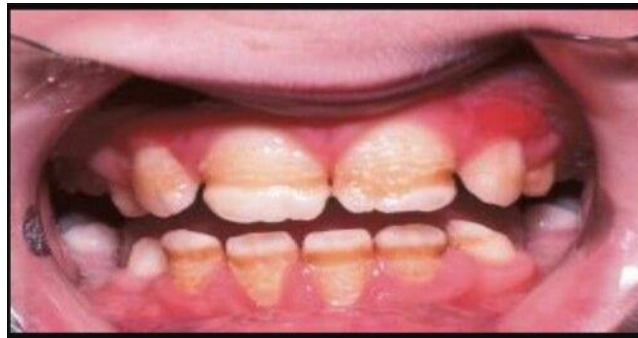10. *Taurodontism*: Enlargement of the body and pulp chamber of a multi-rooted tooth with apical displacement of the pulpal floor and bifurcation of the root.



**Figure 17: Taurodontism.**

***Disturbances During Apposition of Hard Tissues***

1. Enamel hypoplasia: Reduction in the amount of enamel formed.

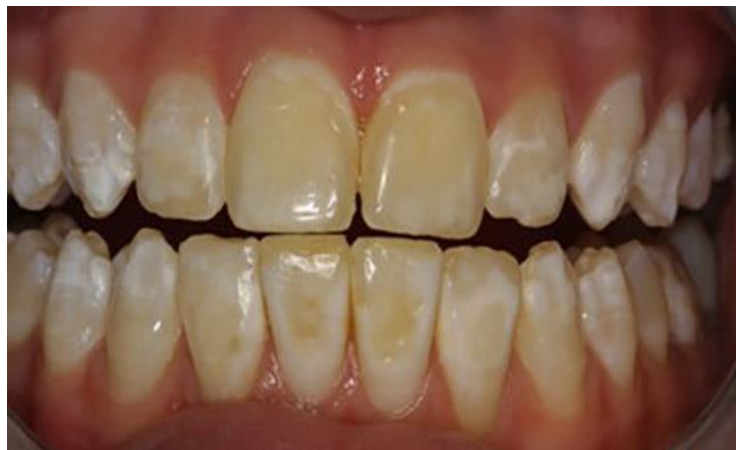

**Figure no.18 Enamel hypoplasia**

Local enamel hypoplasia Periapical infection or trauma (Turner's tooth)

- Systemic enamel hypoplasia Rickets, German measles, fluoride ingestion.
- Hereditary enamel hypoplasia Tooth appears yellow due to reduced enamel thickness.

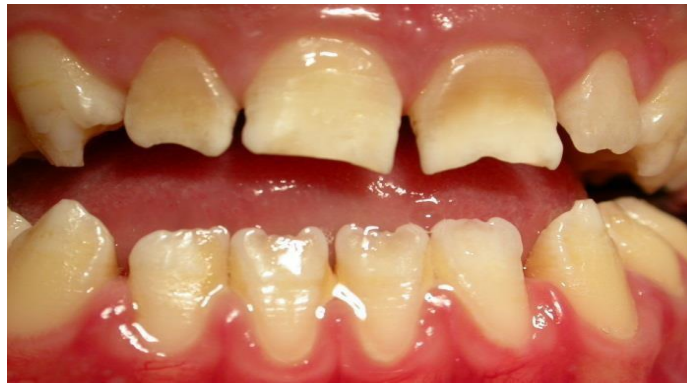3. Amelogenesis imperfect: Hereditary disorder wherein the quality and quantity of enamel formed is altered. Three types:



**Figure no.19 Amelogenesis imperfect**

- Hypoplastic Defective matrix formation
- Hypocalcification Defective mineralization of matrix.
- Hypomaturation Immature enamel crystals.

4. *Dentinogenesis imperfect*: Hereditary developmental disorder of the dentine. The dentine appears grey to brownish violet, enamel frequently separates from the defective dentine, roots become short, canals get obliterated, rapid attrition is seen.



**Figure 20: Dentinogenesis imperfect**

4. *Dentinal dysplasia* Premature loss of teeth, short roots.
5. *Shell teeth* Roots fail to form, pulp chambers are wide.
6. *Odontodysplasia (Ghost teeth)* Enamel and dentine is defective and very thin.
7. *Pigmentation of enamel and dentine*
  - Erythroblastosis fetalis: enamel is green/blue.
  - Porphyria: red to brownish
  - Tetracyclines: brownish
8. *Cementalhypoplasia* Reduced rate of cementum formation, e.g. hypophosphatasia.
9. *Enamel pearls* Attached to the furcation area of maxillary molars.

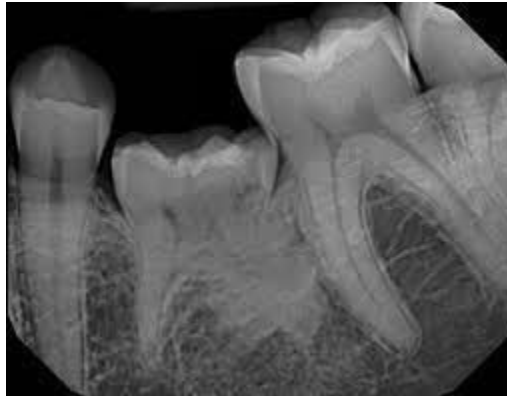### ***Disturbances During Calcification Of Hard Tissue***

1. *Enamel hypocalcification* Calcification is subnormal. It may be local, systemic or hereditary.
2. *Interglobular dentine* Areas of partially calcified dentine.



## **Disturbances During Eruption of Teeth**

1. *Concrescence*: Cemental union of two teeth.
2. *Retarded eruption*: Due to endocrine disturbances, vitamin deficiencies, local causes.
3. *Ankylosed teeth*: Teeth fail to erupt to the occlusal level as they are fused to the bone.



**Figure no.21 Ankylosed teeth**

Development of dentition in humans is complex and depends on many variables. Development of dentition deviates markedly from that of other parts and structures of the body. Crowns of teeth are formed directly to adult size and housed within the jaws years before they emerge. To determine an abnormal course of development, it is the responsibility of an orthodontist to have adequate knowledge on the subject to differentiate abnormal from normal before initiating therapy.

*My great wishes for my lovely students for success. Thanks*



# Orthodontics

## *Orthodontic Tooth Movement*

Orthodontic movement of teeth is based on the observation that if prolonged light pressure is applied to a tooth, tooth movement will occur as the bone around the tooth remodels. Bone is selectively removed in some areas and added in others. In essence, the tooth moves through the bone carrying its attachment apparatus with it, as the socket of the tooth migrates. Because the bony response is mediated by the periodontal ligament (PDL), tooth movement is primarily a PDL phenomenon.

Forces applied to the teeth can also affect the pattern of bone apposition and resorption at sites distant from the teeth, particularly the sutures of the maxilla and bony surfaces on both sides of the temporomandibular joint. In addition, it is possible now to apply force to implants in the maxilla or mandible to influence growth at maxillary sutures and at the mandibular condyle, affecting skeletal growth with minimal or no tooth movement. Thus the biologic response to orthodontic therapy includes not only the response of the PDL but also the response of growing areas distant from the dentition. It is not possible to move bones in the same way teeth are moved, because pressure against sutures, synchondroses or joints does not stimulate similar remodeling of adjacent bone, but it is possible to generate formation of new bone.

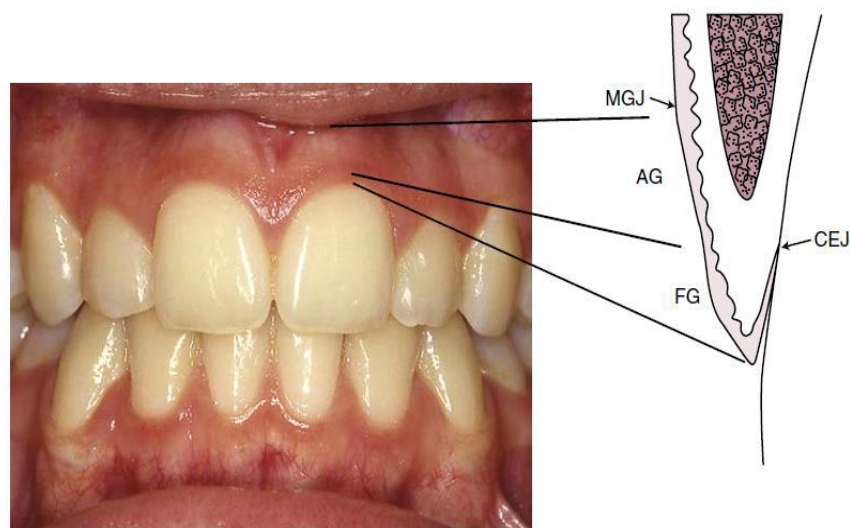
### **1.1. Histology of Periodontium**

During tooth movement, changes in the periodontium occur, depending on magnitude, direction, and duration of the force applied, as well as the age of the orthodontically treated patient. Tooth movement is a

complicated process, requiring changes in the gingiva, periodontal ligament, root cementum, and alveolar bone with their differences in cell population and remodeling capacity. Therefore, a brief description of the normal periodontium is illustrated below:

### 1.1.1. Gingiva

The gingiva is differentiated into the free and attached gingiva. In a clinically healthy condition, the free gingiva is in close contact with the enamel surface, and its margin is located 0.5 to 2mm coronal to the cemento enamel junction after completed tooth eruption, see Figure 1.1. The attached gingiva is firmly attached to the underlying alveolar bone and cementum by connective tissue fibers and is therefore comparatively immobile in relation to the underlying tissue.

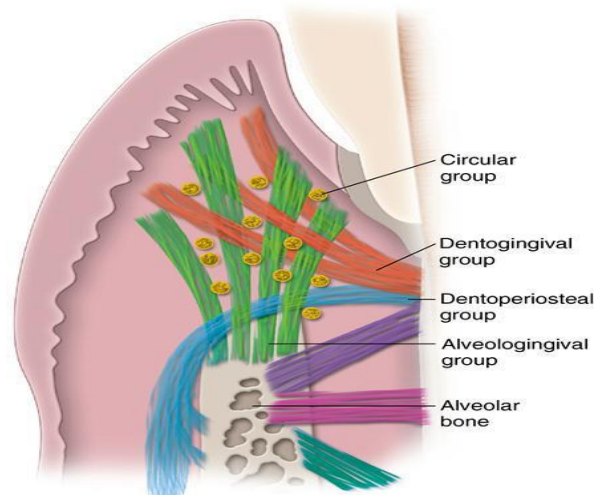


**Figure 1.1:** Macroscopic anatomy of the gingiva showing free gingiva (FG), attached gingiva (AG), mucogingival junction (MGJ), and cemento enamel junction (CEJ).

The predominant component of the gingiva is the connective tissue, consists of collagen fibers, fibroblasts, vessels, nerves, and matrix. The fibroblast is engaged in the production of various types of fibers but is also instrumental in the synthesis of the connective tissue matrix. The collagen fibers are bundles of collagen fibrils with a distinct orientation.

They provide the resilience and tone necessary for maintaining its architectural form and the integrity of the dentogingival attachment. They are usually divided into the following groups, see Figure 1.2:

1. Circular fibers: run in the free gingiva and encircle the tooth.
2. Dentogingival fibers: are embedded in the cementum of the supraalveolar portion of the root and project from the cementum in a fanlike configuration into the free gingival tissue.
3. Dentoperiosteal fibers: are embedded in the same portion of the cementum as the dentogingival fibers but terminate in the tissue of the attached gingiva.
4. Transseptal fibers: run straight across the interdental septum and are embedded in the cementum of adjacent teeth.

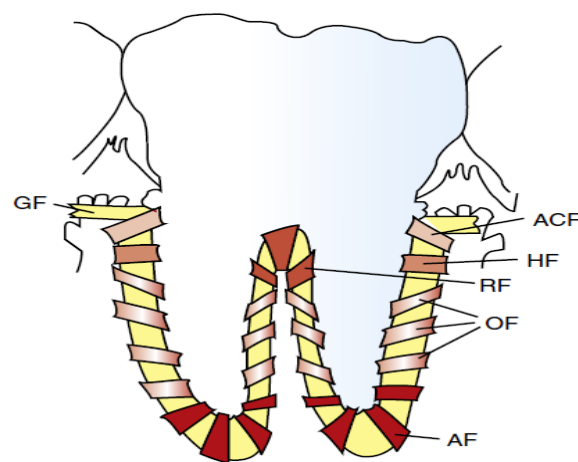


*Figure 1.2: The collagen fibers bundles run in the gingiva.*

### **1.1.2. Periodontal Ligament**

The periodontal ligament (PDL), about 0.25mm wide, is the soft, richly vascular and cellular connective tissue that surrounds the roots of the teeth and joins the root cementum with the lamina dura or the alveolar bone proper. In the coronal direction, the PDL is continuous with the lamina propria of the gingiva and is separated from the gingiva by the collagen fiber bundles, which connect the alveolar bone crest with the

root (the alveolar crest fibers). The PDL and the root cementum develop from the follicle, which surrounds the tooth bud. The true periodontal fibers, the principal fibers, develop along with the eruption of the tooth. The orientation of the collagen fiber bundles alters continuously during tooth eruption. When the tooth has reached contact in occlusion and is functioning properly, they associate with the following well-oriented groups: alveolar crest fibers and horizontal, oblique, apical, and interradicular fibers, as shown in Figure 1.3.



**Figure 1.3:** The PDL fibers: Alveolar-crest fibers (ACF), Apical fibers (AF), gingival fibers (GF), horizontal fibers (HF), Oblique fibers (OF), and interradicular fibers (RF).

The individual bundles have a slightly wavy course, which allows the tooth to move within its socket (physiologic mobility). The presence of a PDL makes it possible to distribute and resorb the forces elicited during mastication and is essential for movement of the teeth in orthodontic treatment. The fibrils of the PDL are embedded in a ground substance with connective tissue polysaccharides (glycosaminoglycans), which vary with age. The tissue response to orthodontic forces, including cell mobilization and conversion of collagen fibers, is considerably slower in older individuals than in children and adolescents. The ground substance has a more rapid turnover than the collagen fibers. During physiologic

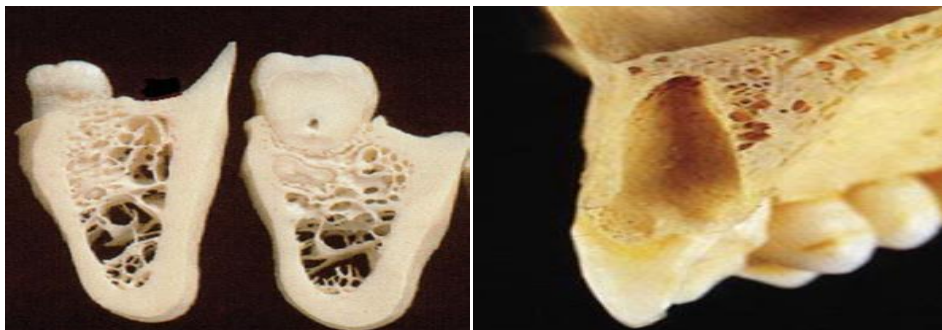
conditions, collagen turnover in the PDL is much higher than that in most other tissues (e.g., twice as high as that of the gingiva).

The high turnover has been attributed to the fact that forces on the PDL are multidirectional, having vertical and horizontal components. The lower collagen turnover in the gingiva may result from the lowered functional stress as the transseptal fibers function in a manner similar to tendons, providing firm anchorage of the tooth.

### **1.1.3. Alveolar Bone**

The alveolar bone is covered with the periosteum, which is differentiated from the surrounding connective tissue. The contiguous mesenchymal cells acquire the character of osteoblasts. The matrix-producing and proliferating cells in the cambium layer, as well as osteocytes inside the bone matrix, are subject to mechanical influence. The alveolar process forms and supports the sockets of the teeth. It consists of dense outer cortical bone plates with varying amounts of spongy or cancellous bone between them. The thickness of the cortical laminae varies in different locations, as shown in Figure 1.4.

The cancellous bone contains bone trabeculae architecture of which is partly genetically determined and partly the result of forces to which teeth are exposed during function or orthodontic treatment.



*Figure 1.4: Alveolar bone in maxilla and mandible.*

## **1.2. Periodontal and Bone Response to Normal Function**

Tooth movements can be broadly divided into three types:

1. Physiologic
2. Pathologic/ (Pathologic migration)
3. Orthodontic.

The term physiologic tooth movement designates, primarily, the slight tipping of the functioning tooth in its socket and secondarily, the changes in tooth position that occur in young persons during and after tooth eruption. These are normal or routine in nature and the tooth and its supporting structures are designed to undertake and withstand such movements. During masticatory function, the teeth and periodontal structures are subjected to intermittent heavy forces. Tooth contacts last for 1 second or less; forces are quite heavy, ranging from 1 or 2kg while soft substances are being chewed to as much as 50kg against a more resistant object. When a tooth is subjected to heavy loads of this type, quick displacement of the tooth within the PDL space is prevented by the incompressible tissue fluid. Instead, the force is transmitted to the alveolar bone, which bends in response.

Very little of the fluid within the PDL space is squeezed out during the first second of pressure application. If pressure against a tooth is maintained, however, the fluid is rapidly expressed, and the tooth displaces within the PDL space, compressing the ligament itself against adjacent bone. Not surprisingly, this hurts. Pain is normally felt after 3 to 5 seconds of heavy force application, indicating that the fluids are expressed and crushing pressure is applied against the PDL in this amount of time. The resistance provided by tissue fluids allows normal mastication, with its force applications of 1second or less, to occur without pain, see Table 1.1.

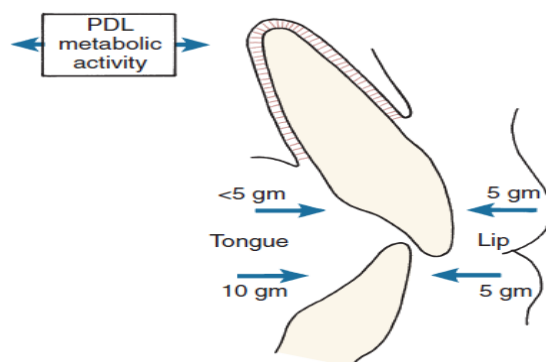
**Table 1.1: Physiologic Response to Heavy Pressure Against a Tooth**

| Time (seconds) | Event   |
|----------------|---|
| <1             | PDL fluid incompressible, alveolar bone bends, piezoelectric signal generated   |
| 1-2            | PDL fluid expressed, tooth moves within PDL space                               |
| 3-5            | PDL fluid squeezed out, tissues compressed; immediate pain if pressure is heavy |

*PDL, Periodontal ligament.*

Although the PDL is adapted to resist forces of short duration, it rapidly loses its adaptive capability as the tissue fluids are squeezed out of its confined area.

Prolonged force, even of low magnitude, produces a different physiologic response-remodeling of the adjacent bone. Orthodontic tooth movement is made possible by the application of prolonged forces. In addition, light prolonged forces in the natural environment-forces from the lips, cheeks, or tongue resting against the teeth-have the same potential as orthodontic forces to cause the teeth to move to a different location. Resting pressures from the lips or cheeks and tongue are usually not balanced. In some areas, as in the mandibular anterior, tongue pressure is greater than lip pressure. In other areas, as in the maxillary incisor region, lip pressure is greater. Active stabilization produced by metabolic effects in the PDL probably explains why teeth are stable in the presence of imbalanced pressures that would otherwise cause tooth movement. See Figure 1.5.

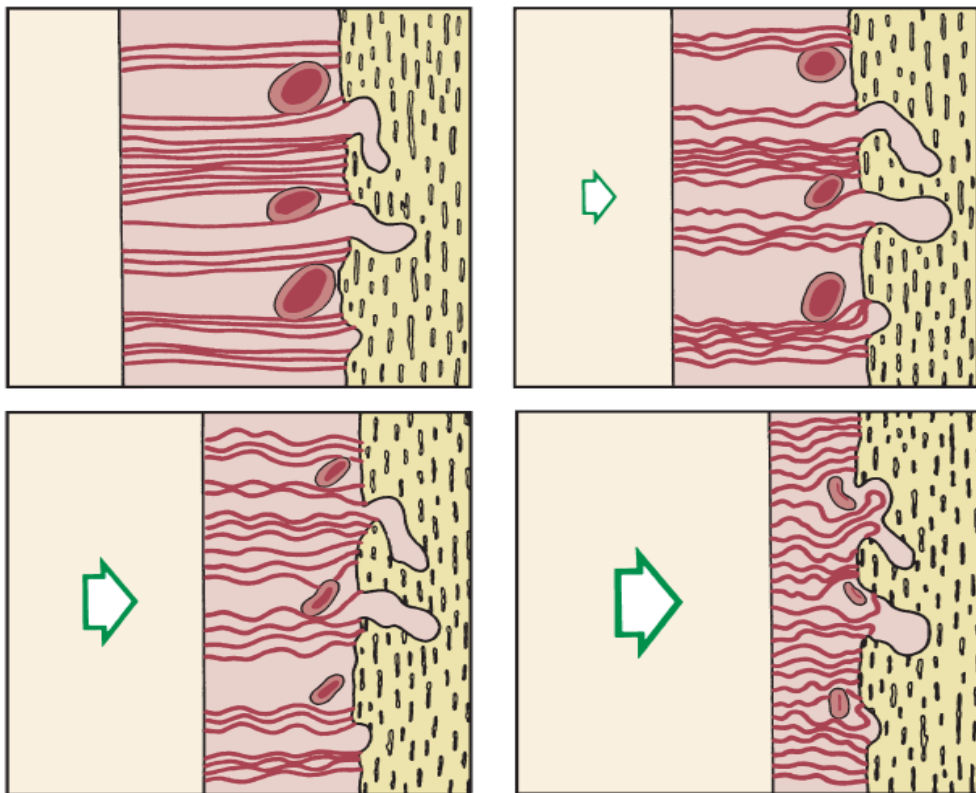


**Figure 1.5: Resting pressures from the lips or cheeks and tongue**



### 1.3. Periodontal and Bone Response to Orthodontic Forces

Orthodontic tooth movement is based on the observation that if prolonged light pressure is applied to a tooth, tooth movement will occur as the bone around the tooth remodels. Bone is selectively removed in areas and added in the other area. The response to sustained force against the teeth is a function of force magnitude. Heavy forces lead to rapidly developing pain, necrosis of cellular elements within the PDL, and the phenomenon of “undermining resorption” of alveolar bone near the affected tooth, as shown in Figure 1.6. Lighter forces are compatible with survival of cells within the PDL and a remodeling of the tooth socket by a relatively painless “frontal resorption” of the tooth socket.



*Figure 1.6: Diagrammatic representation of the increasing compression of blood vessels as pressure increases in the periodontal ligament. At a certain magnitude of continuous pressure, blood vessels are totally occluded and a sterile necrosis of periodontal ligament tissue ensues*

*Table 1.2: Physiologic Response to Sustained Pressure Against a Tooth*

| TIME           |                | Event  |
|----------------|----------------|--|
| Light Pressure | Heavy Pressure |  |
|                | <1 second      | PDL fluid incompressible, alveolar bone bends, piezoelectric signal generated  |
|                | 1-2 seconds    | PDL fluid expressed, tooth moves within PDL space  |
|                | 3-5 seconds    | Blood vessels within PDL partially compressed on pressure side, dilated on tension side; PDL fibers and cells mechanically distorted |
|                | Minutes        | Blood flow altered, oxygen tension begins to change; prostaglandins and cytokines released   |
|                | Hours          | Metabolic changes occurring; chemical messengers affect cellular activity, enzyme levels change                                      |
|                | ~4 hours       | Increased cAMP levels detectable, cellular differentiation begins within PDL   |
|                | ~2 days        | Tooth movement beginning as osteoclasts and osteoblasts remodel bony socket  |
|                | 3-5 seconds    | Blood vessels within PDL occluded on pressure side   |
|                | Minutes        | Blood flow cut off to compressed PDL area  |
|                | Hours          | Cell death in compressed area  |
|                | 3-5 days       | Cell differentiation in adjacent narrow spaces, undermining resorption begins  |
|                | 7-14 days      | Undermining resorption removes lamina dura adjacent to compressed PDL, tooth movement occurs   |

cAMP, Cyclic adenosine monophosphate; PDL, periodontal ligament.

## 1.4. Theories of Orthodontic Tooth Movement

Theories of orthodontic Tooth movement are:

1. Pressure tension theory.
2. Blood flow/ Fluid Dynamic theory.
3. Piezoelectric/ Bioelectric theory.

### 1.4.1. Pressure tension theory

Schwartz proposed the pressure tension theory in 1932. This is the simplest and the most widely accepted theory. According to this theory: ‘Whenever a tooth is subjected to an orthodontic force, it results in areas of pressure and tension. The alveolar bone is resorbed whenever the root, for a certain length of time, causes compression of PDL, i.e. the pressure side. New alveolar bone is deposited whenever there is a stretching force acting on PDL fibers, i.e. the tension side’.

### 1.4.2. Blood flow/ Fluid Dynamic theory

Bien (1966) has been credited for proposing the fluid dynamic or the blood flow theory. According to this theory: ‘Tooth movement occurs as a result of alterations in fluid dynamics in the PDL. Periodontal space is a confined space and the passage of fluid in and out of this space is limited.

The contents of PDL create a unique hydrodynamic condition resembling a hydraulic mechanism’.

When a force of short duration is applied to a tooth, the fluid in the periodontal space escapes through tiny vascular channels. When the force is removed, the fluid is replenished by diffusion from capillary walls and recirculation of the interstitial fluid. A force of greater magnitude and duration causes the interstitial fluid in PDL space to get squeezed out and move towards the apex and cervical margins. This results in the slowing down of the tooth movement and is called the “squeeze film” effect.

Bien characterized three distinct but interacting fluid systems in PDL:

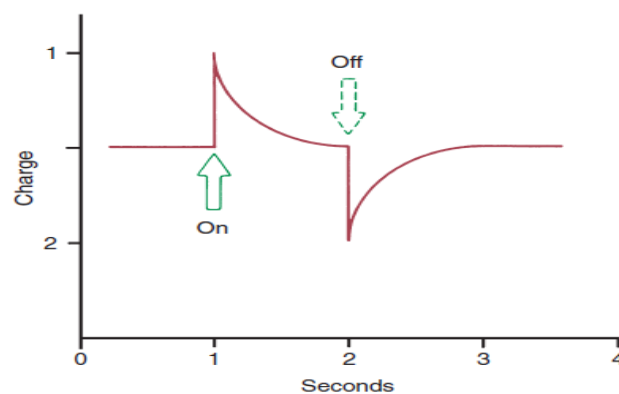
1. Vascular system
2. Cellular system
3. Interstitial fluid system.

#### **1.4.3. Piezoelectric/ Bioelectric/ Bone Bending theory.**

Piezoelectricity is a phenomenon observed in many crystalline materials. The deformation of the crystal structure produces a flow of electric current as electrons are displaced from one part of the crystal lattice to another.

Piezoelectric signals have two unique characteristics, see Figure 1.7:

1. A quick decay rate and
2. The production of an equivalent signal opposite in direction, when the force is released.

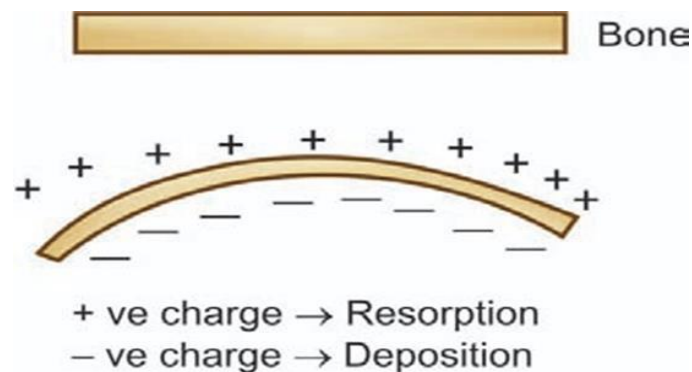


**Figure 1.7: Piezoelectricity:** When a force is applied to a crystalline structure such as bone or collagen, a flow of current is produced that quickly dies away. When the force is released, an opposite current flow is observed. This piezoelectric effect results from migration of electrons within the crystal lattice as it is distorted by applied force and then returns to its original form when the force is removed.

The piezoelectric signal is created in response to the force, but it quickly reaches zero even though the force is maintained. The piezoelectric signal is again produced, this time in the opposite direction, when the force is removed. Both these characteristics are explained by the migration of electrons within the crystal lattice as it is distorted by pressure. Not only is bone mineral a crystal structure with piezoelectric properties but so is collagen. Hence, the possible sources of electric current are:

1. Collagen
2. Hydroxyapatite
3. Collagen hydroxyapatite interface
4. The mucopolysaccharide fraction of the ground substance.

When the force is applied on a tooth, the adjacent alveolar bone bends. Areas of concavity are associated with negative charge and cause bone deposition. Areas of convexity are associated with positive charge and cause bone resorption, as shown in Figure 1.8.



**Figure 1.8:** Areas of concavity and convexity produced on bone bending

*My great wishes for my lovely students for success. Thanks*

# Orthodontics

## *Biomechanics in Orthodontic*

### **1.1. Phases of Tooth Movement**

Burstone categorized three distinct yet overlapping stages of tooth movement. They are:

- **Initial phase**
- **Lag phase**
- **Post-lag phase.**

#### **1.1.1. Initial Phase**

The initial phase of tooth movement is immediately seen following the application of a force on a tooth. The phase is characterized by a sudden displacement of the tooth within its socket. The movement of the tooth into the periodontal space and the bending of the alveolar bone probably cause it. The extent of movement achieved is nearly same for both light and heavy forces.

#### **1.1.2. Lag Phase**

The lag phase is characterized by very little or no tooth movement. It is the phase where the cellular components around the area of interest get activated to cause tooth movement. The lag phase is longer if high forces are applied, as the area of hyalinization created is large and the resorption is rearward. Shorter duration of the lag phase is noticed for lighter forces.

#### **1.1.3. Post-Lag Phase**

This phase is characterized by the removal of the hyalinized tissue and tooth movement. The movement is mediated by osteoclasts and there is either direct resorption of the bony surface facing the periodontal

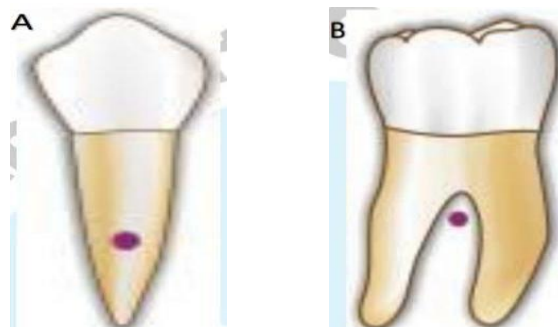
ligament or rearward bone resorption.

## 1.2. Forces, Moments and Couples

□ **Force:** can be defined as ‘an act upon a body that changes or tends to change the state of rest or of motion of that body.’

□ **Center of Resistance (COR):** Every unrestrained body has a point at which it can (at least in theory) be perfectly balanced. This point is called the center of gravity. When we talk about teeth, we are talking of a body which is restrained by adjacent structures like the periodontal ligament etc. For such restrained bodies the analogous point to the center of gravity is called the center of resistance. By definition, a force with a line of action passing through the COR produces translation.

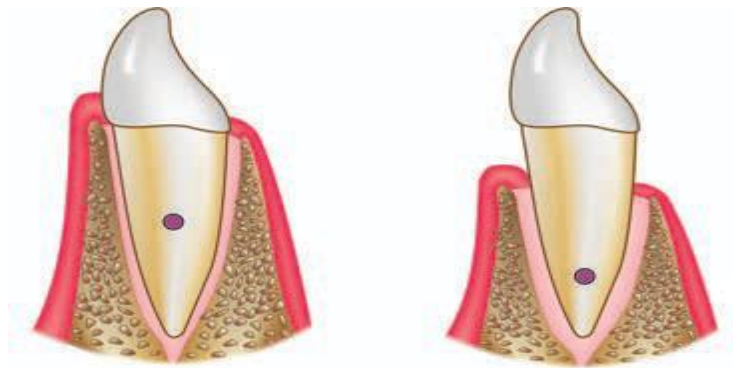
The COR of a single-rooted tooth is on the long axis of the tooth, probably between one third and one half of the root length apical to the alveolar crest (see Figure 1A). For a multi-rooted tooth, the COR is probably between the roots, 1 or 2 mm apical to the furcation (see Figure 1B).



**Figure 1:** Center of resistance. (A): of single rooted tooth, (B): For a multi-rooted tooth.

COR varies with:

- 1) Root length.
- 2) Alveolar bone height, see Figure 2.
- 3) The root morphology- single or multi-rooted teeth.

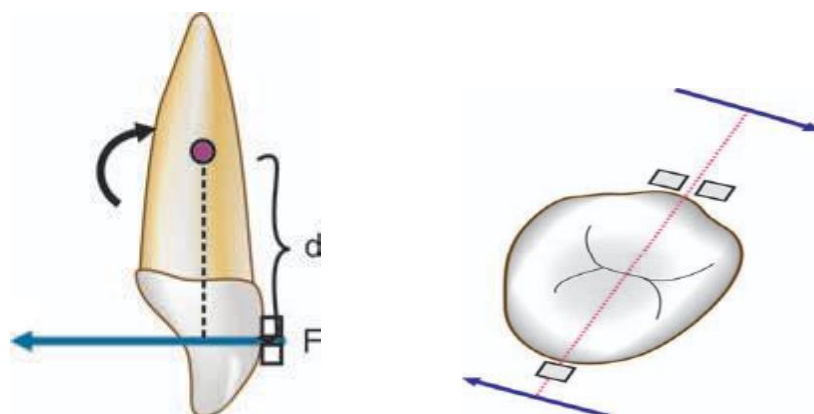


**Figure 2:** Change in center of resistance of tooth following alveolar bone loss.

- **Moment of force:** When the line of action of an applied force does not pass through the COR, the force will produce some rotation. The potential for rotation is measured as a *moment*.

The magnitude of the moment is equal to the magnitude of the force multiplied by the perpendicular distance of the line of action of the force to the COR (Figure 3A).

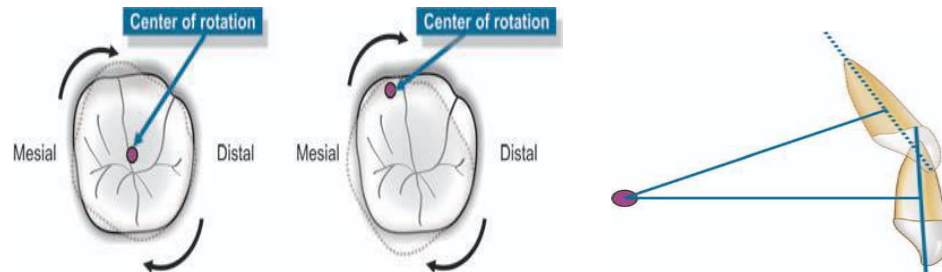
- **A couple:** consists of two forces of equal magnitude but opposite in direction, with parallel lines of action. When two forces are applied in this manner the resultant produced is a pure moment (the translatory effect of the individual forces gets cancelled) (Figure 3B).



**Figure 3:** **A**, Moment-magnitude of force ( $F$ )  $\times$  perpendicular distance of the point of application from the center of resistance ( $d$ ). **B**, a couple.



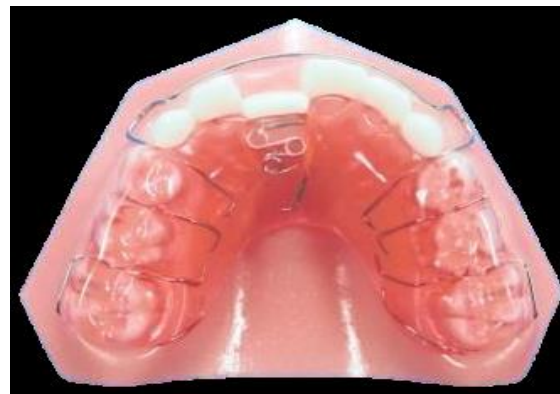- **Center of rotation (CORo):** is the point around which rotation actually occurs when an object is being moved/rotated. The CORo can be at any position on or off a tooth (Figure 4). As the CORo moves towards the apex, the more the displacement of the crown and vice versa.



**Figure 4:** The concept of a center of rotation can be used to define any type of tooth movement in any plane of space.

### 1.3. Types of Tooth Movements

1) **Tipping or Inclination:** a. Uncontrolled. b. Controlled. It is tooth movement with greater movement of the crown of the tooth than of the root. The crown will move to the same direction as the force while the root will move to the opposite direction. The CORo of the motion is apical to the COR, see Figure 5.



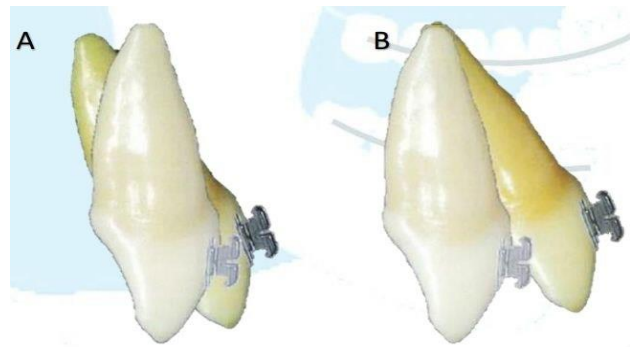
**Figure 6:** Labial crown tipping of upper right central incisor in a palatal crossbite using upper removable appliance by z-spring.

a. **Uncontrolled:** When the CORo is located between the COR and the apex. This is the simplest type of tooth movement, but it is undesirable.

Uncontrolled tipping can be useful in some cases, eg: class II div. 2 and class III where the excessively upright incisors often need flaring, (Figure

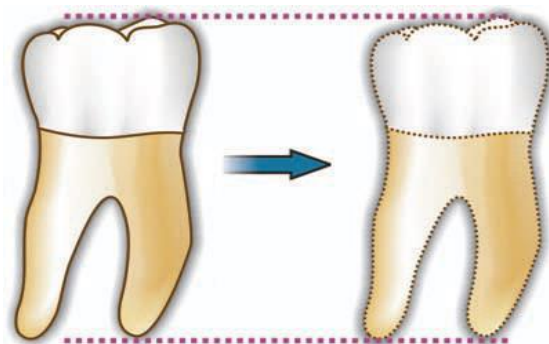
6A).

b. **Controlled:** When the CORo is at root apex. It is a very desirable type of tooth movement; it is obtained with the application of a force to move the crown, and application of a moment to control or maintain the position of the root apex. An example of this inclination is when we want to retract the anterior sector without moving the location of the tooth apex, (Figure 6B).



**Figure 6:** *A, Uncontrolled tipping. B, Controlled tipping.*

2) **Translation:** It is also known as en-mass or bodily movement. Happens when the crown and the root move the same distance and in the same horizontal direction. This is only possible when the line of action of a force passes through the center of resistance of the tooth. The CORo is at infinity.



**Figure 7:** *Pure translation.*

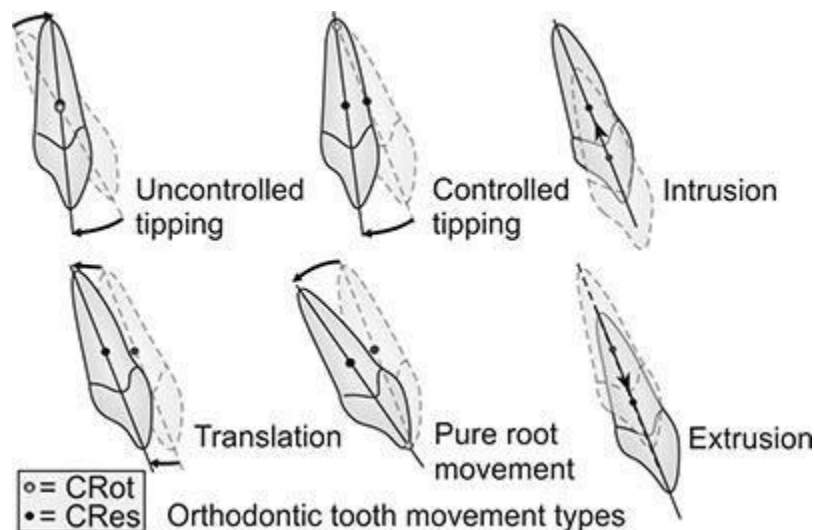
3) **Vertical Movement:** The movement of the whole tooth (crown and root), could be (see Figure 8):

a. **Extrusion:** A translational type of tooth movement parallel to the long

axis of the tooth in the direction of the occlusal plane (resembles tooth eruption); e.g. closure of anterior open bites by extrusion of upper and /or lower teeth.

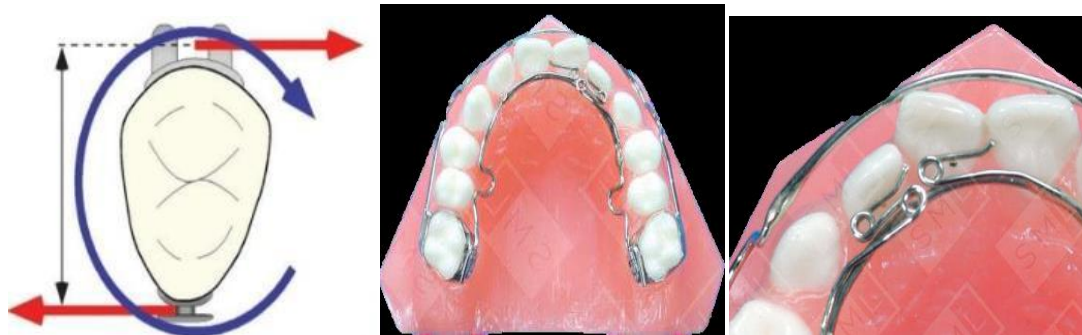b. **Intrusion:** The same definition of extrusion but in an apical direction; e.g. intrusion of upper and / or lower anterior teeth to reduce a deep bite.

4) **Root movement:** It means major movement of the root with minimal crown movement. The CORo of a tooth is at the incisal edge, or bracket, see Figure 8. Root movement includes torque and upright. Torquing means palatal or lingual root movement, while reverse torquing means buccal or labial root movement. Mesial or distal root movement is called root uprighting. An example for torque movement is the correction of maxillary centrals root inclination in class II div. 2 malocclusion.



**Figure 8:** Types of orthodontic tooth movements.

5) **Rotation:** Pure rotation is achieved by the application of what is called couple force system; i.e. applying two equal forces but opposite in direction that result in circular movement of the tooth around its long axis, see Figure 9. The CORo will be situated at the COR of the tooth. Rotational movements have great tendency to relapse after orthodontic treatment due to re-coil action of the PDL fibers.



*Figure 9: Rotation.*

#### **1.4. Rate of Tooth Movement**

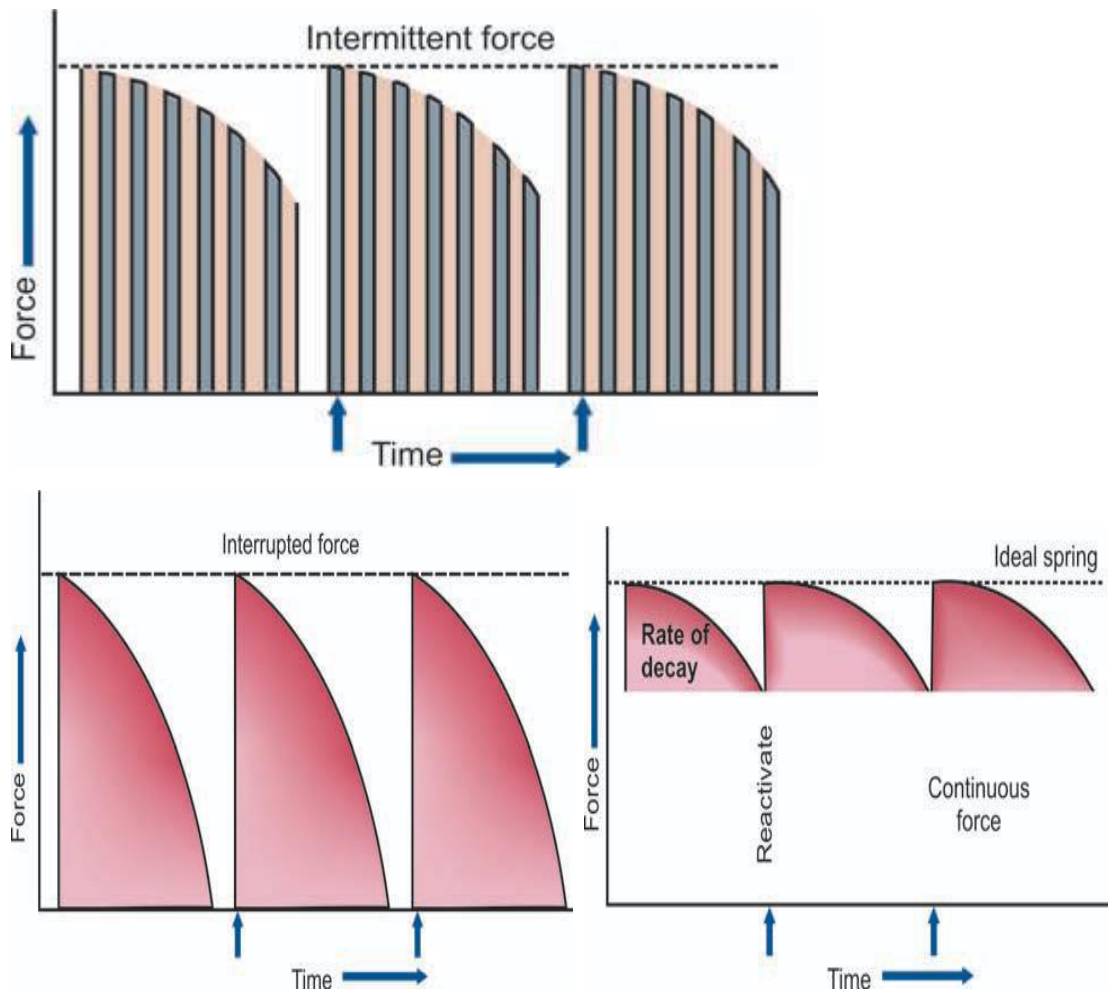
It is defined as the displacement of a tooth per unit time, and is usually measured in mm per an hour, a day, a week, or a month. About 1 mm per month may be regarded as an acceptable rate of tooth movement.

The rate of orthodontic movement is affected by many factors:

##### **1.4.1. Nature and duration of force applied**

Both light and heavy forces will result in orthodontic movement. If light forces are used; minimizing hyalinization (necrotic area) of periodontal ligament, the rate of tooth movement will be greater. The optimum force for tooth movement is around (20-25g/cm<sup>2</sup>) of root surface area. The force magnitude applied to an individual tooth will depend upon its root surface area and the type of planned tooth movement.

The manner of orthodontic force application is generally either intermittent (e.g. removable appliances, see Figure 10), interrupted or continuous (e.g. fixed appliances, see Figure 10). The chemical mediators for tooth movement appear in the blood stream within a few hours after force application, and clinical tooth movement occurs with a force duration of as little as six hours per day. However, for optimal tooth movement, application of a light continuous force is preferable to intermittent forces because the cell biology system remains in a constantly responsive state, not a fluctuating state.



**Figure 10:** Types of orthodontic forces.

### 1.4.2. Age

Tooth movement and biologic responses to orthodontic treatment in the adults are slower than in adolescents and children because the PDL is much less cellular in adults. In addition, the alveolar bone in adults is denser.

### 1.4.3. Individual Variation

Individual differences in rate of growth, bone density and metabolism, and turn over in the PDL may be responsible for the variation in rate of tooth movement. In some individuals, the alveolar bone is loose and cancellous with large marrow spaces, whereas in other the alveolar bone is dense lamellated bone with few marrow spaces, in this case the tooth movement will be much slower.

#### **1.4.4. Drugs and Chemical Agents**

Many studies have been conducted to test the accelerative or preventive effect of many drugs and chemical agents on orthodontic tooth movement, and it has been found that the rate of tooth movement can be altered by applying certain agents locally or systemically. The promoter agents accelerate the required tooth movement by enhancement of bone resorption; e.g. Prostaglandins, Vitamin D3, and Corticosteroids. The suppressor agents reduce tooth movement by reducing bone resorption or enhancing bone formation; e.g. NSAIDs, Calcitonin and Bisphosphonates.

#### **Iatrogenic effect of tooth movement**

Orthodontic treatment have an adverse effects associated with the treatment like other fields in dentistry. These effects can be related to the patient or practitioner.

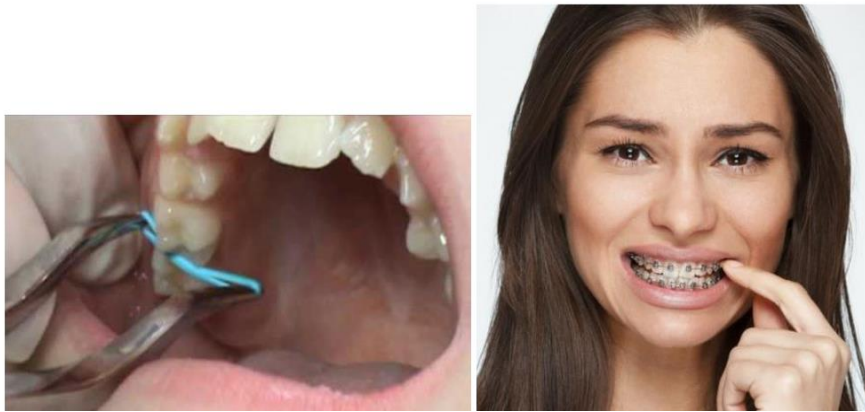- 1) Pain.
- 2) Periodontal disease.
- 3) Pulp effect.
- 4) Root resorption.
- 5) Decalcification and associated caries.
- 6) Temporal mandibular disorders.

#### **1) Pain associated with orthodontic treatment:**

Pain and discomfort is a common adverse effect associated with orthodontic treatment. 70–95% of orthodontic patients experience pain. This pain could be a reason for discontinuing treatment in some cases; the pain and discomfort associated with orthodontic treatment is characterized by pressure, tension, or soreness of the teeth. Pain in the anterior teeth is greater than the posterior teeth. Pain has been reported to begin 4 h after the placement of separators or orthodontic wire, and the worst pain was found to occur on the second day of treatment. Usually,

pain lasts for seven days. Management of pain should include informing the patient of the possibility of experiencing pain to reduce anxiety. Furthermore, the clinician can ask the patient to chew on plastic wafers or chewing gums containing aspirin.

Additionally, clinicians are recommended to prescribe Ibuprofen or acetaminophen analgesics preoperatively and for a short duration after the placement of separators and initial wires.

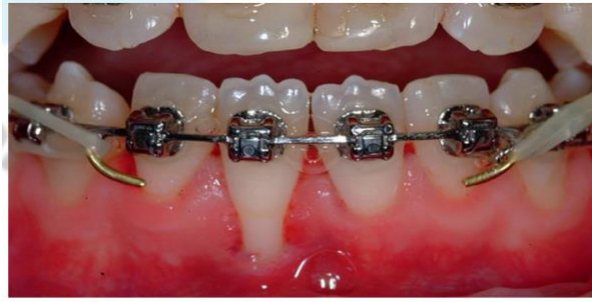

## **2) Periodontal disease and orthodontic treatment:**

Periodontal disease includes gingivitis, alveolar bone loss (periodontitis), and loss of attached gingival support. The periodontal reaction toward orthodontic appliances depends on multiple factors, such as host resistance, the presence of systemic conditions, the amount and composition of dental plaque, smoking and the negative effects of uncontrolled diabetes.

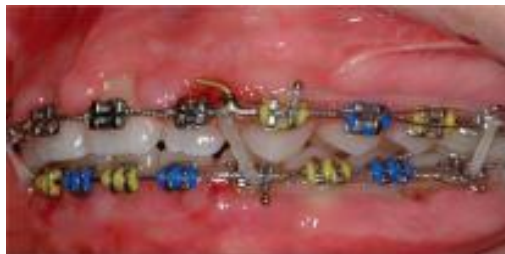Bacteria present in dental plaque are the primary causative agent of periodontal disease. Orthodontic treatment with fixed appliances is known to induce an increase in the volume of dental plaque. Therefore, fixed orthodontic treatment may result in localized gingivitis, which rarely progresses to periodontitis.





*Recession of a lower incisor following proclination during orthodontic treatment.*

Therefore, oral hygiene instructions should be given before the initiation of orthodontic treatment and reinforced during every visit. Regularly brushing the teeth is the first line of defense in controlling dental plaque in addition to the use of an interproximal brush. Orthodontic treatment of patients with active periodontal disease is contraindicated as the risk for further periodontal breakdown is markedly increased. And the treatment of uncontrolled diabetic individuals is contraindicated also.



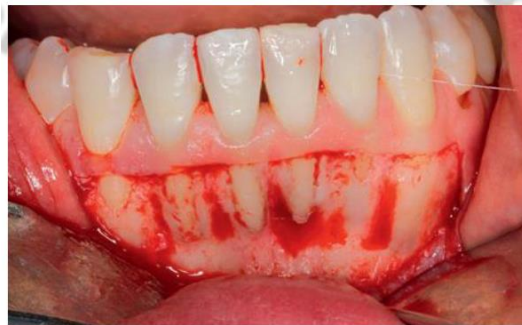*Gingival hyperplasia during orthodontic treatment*

### **3) Pulpal changes during orthodontic treatment:**

Although pulpal reactions to orthodontic treatment are minimal, there is probably transient inflammatory response within the pulp, at least at the beginning of treatment. This may contribute to the discomfort that patients often experience for a few days after appliances are placed. The possibility of pulp vitality loss during orthodontic treatment does exist. The risk factors for loss of pulp vitality include a history of trauma

associated with the teeth. Pre-treatment periapical radiographs of previously traumatized teeth are essential for comparative purposes.

Additionally, the use of heavy uncontrolled, continuous forces by the orthodontist or round tripping of the teeth may lead to loss of pulp vitality since root apex may moved outside the alveolar process. Therefore, orthodontist should use optimal light forces during their treatment.



#### **4) Root resorption:**

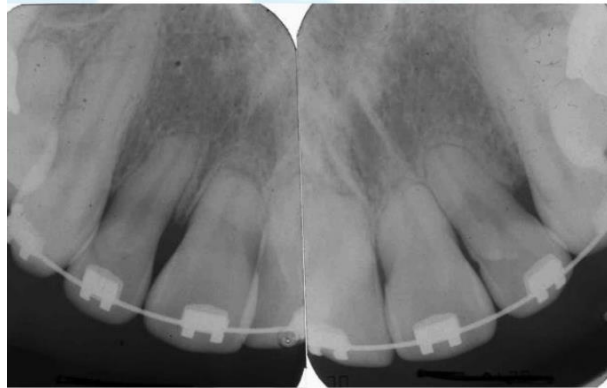Limited root resorption involving a number of teeth can be considered as consequence of orthodontic treatment.

The factors which may be contributing in root disease are hormonal disturbance, dietary deficiency, Periodontal disease and orthodontic treatment variables like duration of treatment. The genetic predisposition makes root resorption associated with orthodontic treatment more predictable.

The risk for root resorption increases with the length of treatment. Treatment of impacted canines can extend treatment time and increase risk for root resorption. Thin, tapered, and dilacerated root morphology, results in roots that are more prone to resorption (ex. maxillary lateral incisor). Additionally, history of trauma associated with the anterior teeth increases the risk for root resorption.

Assessment of the condition through a progress radiograph at 6–12 months after the initiation of orthodontic treatment is recommended.

These could be either periapical or panoramic radiographs. The patient must be informed that if root resorption is observed, then active treatment must be stopped for at least 3 months. The reparative process of root resorption begins two weeks after active treatment is stopped. At this stage, an alternative treatment plan should be considered and treatment should be discontinued when severe root resorption is observed.

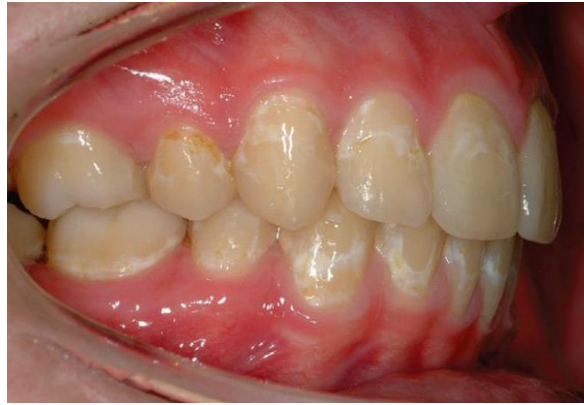

Severe root resorption during orthodontic treatment

#### **5) Decalcification and caries associated with orthodontic treatment:**

Decalcification of enamel (*white spots*) is a common adverse effect of orthodontic treatment. Decalcification is considered to be the first step toward cavitation. Decalcification of enamel occurs in 50% of orthodontic patients and the most affected teeth are the maxillary incisors. Additionally, these lesions can develop within four weeks, which is the typical time span for orthodontic follow-up.

The prevention protocol for decalcification includes plaque control through brushing of the teeth with fluoridated tooth paste. Daily rinsing with a 0.02% or 0.05% sodium fluoride solution can also minimize decalcification of enamel. Additionally, fluoridated solutions may delay the progression of lesions. Application of fluoride varnish twice a year or a combination of antibacterial and fluoride varnish may reduce the incidence of decalcification.



Generalized demineralization following orthodontic treatment with fixed appliances.

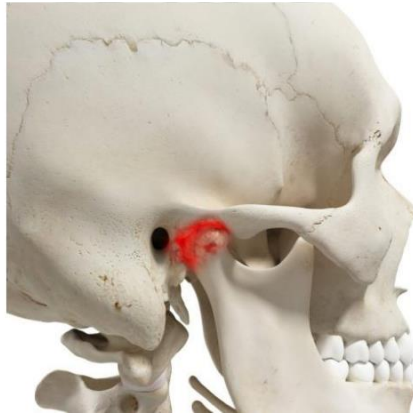
#### **6) TMD and orthodontic treatment:**

TMD is a condition that can include masticatory muscle pain, internal derangement of the temporomandibular joint (TMJ) disc, and degenerative TMJ disorders as separate problems or can be a combination.

The etiology of TMD is complex and cannot be explained on a cause-and-effect basis. Malocclusion may be considered in some cases as a contributing factor, but it is not the only etiological factor.

Orthodontic treatment during adolescence does not increase the risk for TMD, and it should not be started in patients with acute signs and symptoms of TMD. The orthodontic treatment should be postponed after the attack is controlled.

If the patient develops signs and symptoms during the orthodontic treatment, then all active forces must be discontinued without the need for the removal of the fixed orthodontic appliances. Then, the signs and symptoms of TMD must be controlled using a conservative approach. Once the signs and symptoms are under control, then the practitioner must reevaluate the objectives of treatment. In some cases, the orthodontic treatment must be terminated if the signs and symptoms cannot be controlled.



### **Accelerated tooth movement:**

Methods to accelerate orthodontic tooth movement can be broadly studied under the following categories:

1. Drugs.
2. Surgical Methods.
3. Physical/ Mechanical stimulation methods.

#### **I. Drugs:**

Various drugs have been used since long to accelerate orthodontic tooth movement, and have achieved successful results. These include vitamin D, prostaglandin, interleukins, parathyroid hormone, misoprostol etc. But, all of these drugs have some or the other unwanted adverse effect, and as of today, no drug exists that can safely accelerate orthodontic tooth movement.

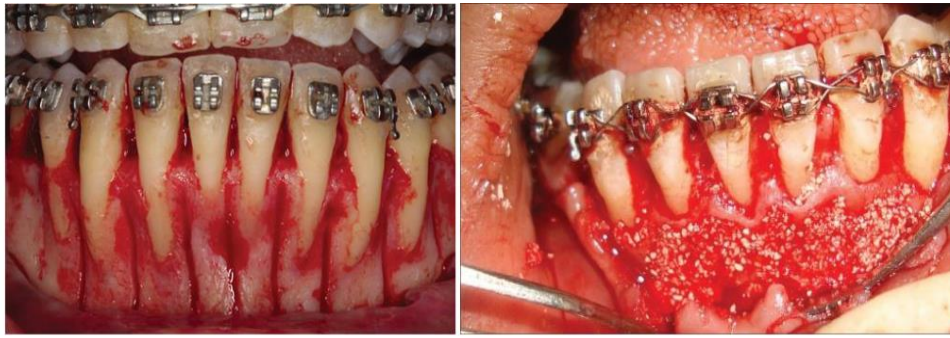#### **II. Surgical Methods:**

The various surgical methods available are:

##### **1. Corticotomy:**

The conventional corticotomy procedure involves elevation of full thickness mucoperiosteal flaps, buccally and/or lingually, followed by placing the corticotomy cuts using either micromotor under irrigation, or piezosurgical instruments. This can be followed by placement of a graft

material, wherever required, to augment thickness of bone.



***Advantages:***

- a. It has been proven successfully by many authors, to accelerate tooth movement.
- b. Bone can be augmented, thereby preventing periodontal defects, which might arise, as a result of thin alveolar bone.

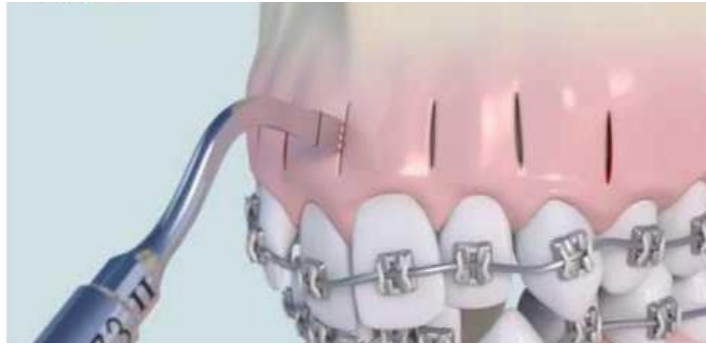
***Disadvantages:***

- a. High morbidity associated with the procedure.
- b. Invasive procedure.
- c. Chances of damage to adjacent vital structures.
- d. Post-operative pain, swelling, chances of infection, avascular necrosis.
- e. Low acceptance by the patient.

**2. Piezocision:**

The surgery was performed 1 week after placement of orthodontic appliance, under local anaesthesia. Gingival vertical incisions, only buccally, were made below the interdental papilla, as far as possible, in the attached gingival using a No.15 scalpel. These incisions need to be deep enough so as to pass through the periosteum, and contact the cortical bone. No suturing is required, except for the areas, where the graft material needs to be stabilized. Patient is placed on an antibiotic, mouthwash regimen.





### ***Advantages***

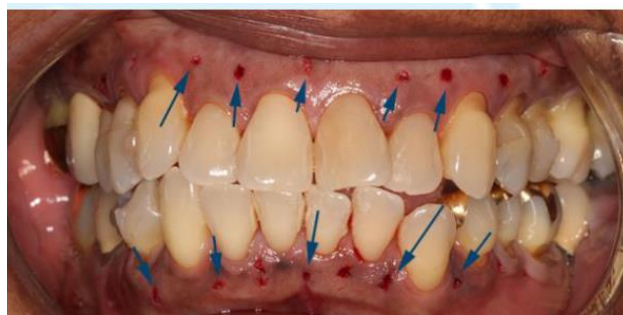- a. Minimally invasive.
- b. Better patient acceptance.

### ***Disadvantages***

Risk of root damage, as incisions and corticotomies are “blindly” done.

### **3. Micro-Osteoperforations (MOP):**

This based on microperforation in which screw like those used for skeletal anchorage is placed through the gingiva into interproximal alveolar bone and then removed. It is said that 3 such perforations in each interproximal area are enough to generate a regional acceleration of bone remodeling, and thereby produce faster tooth movement.



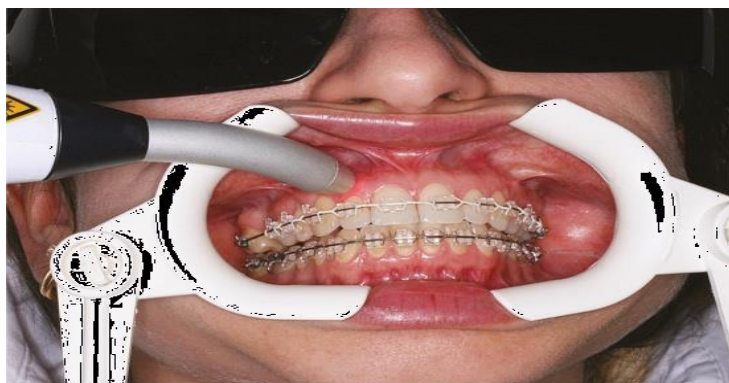
### **III. Physical/Mechanical Stimulation:**

Surgical methods, regardless of technique, are still invasive to some degree, and hence have their associated complications. Hence, noninvasive methods have come to the fore. These modalities include lasers, vibration, direct electric current etc.



### ***1. Laser:***

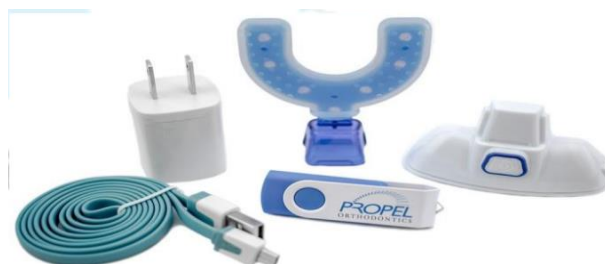In the last decade, many histological studies have attempted to determine the effect of low-intensity laser therapy on the histochemical pathways directly associated with orthodontic tooth movement. Increased osteoblastic and osteoclastic activity after low-level laser therapy was observed. The variations amongst the studies seem to arise from variations in frequency of application of laser, intensity of laser, and method of force application on the tooth.



### ***2. Vibration:***

This device consists of an activator, which is the active part of the appliance that delivers the vibration impulses with a USB interface through which it can be connected to a computer to review the patient usage of the appliance, a mouthpiece that contacts the teeth.

It is a portable device that can be charged similar to any other electronic device; it is based on delivery of high-frequency vibration (30 Hz) to the teeth for approximately 20 minutes per day. Various case studies using this device have shown the treatment times to be reduced by up to 30-40%.



### **3. Tissue-Penetrating Light:**

It provides light with an 800- to 850-nanometer wave length (just above the visible spectrum) adjacent to the alveolar bone. Light in this spectrum does penetrate soft tissue, and the idea is that it “infuses light energy directly into the bone tissue”. This is said to excite intracellular enzymes and increase cellular activity in the PDL and bone, increasing the rate of bone remodeling and tooth movement.



*The intraoral device delivers light at an infrared frequency that penetrates the soft tissue over the alveolar bone*

### **4. Therapeutic Ultrasound:**

It is known that therapeutic ultrasound (which is different from diagnostic ultrasound) increases blood flow in treated areas. The theory is that increased blood flow in the PDL would increase the rate of bone remodeling and tooth movement and also could decrease root resorption.



*My great wishes for my lovely students for success. Thanks*

# Orthodontics

## *Etiology of malocclusion*

### **Classification of etiological factors**

The final form of the occlusion and position of the teeth exhibits a wide range of variation. The main factors responsible for producing this variation can be divided into two groups:

- 1- The general factors which have general effect on the occlusion and play a part in the development of every occlusion.
- 2- The local factors which do not necessarily appear in everyone but they may be the main cause in producing a malocclusion in an individual.

### ***General factors affecting occlusal development:***

- Skeletal factors: the size, shape and relative positions of the upper and lower jaws.
- Muscle factors: the form and function of the muscles which surround the teeth, i.e. the muscles of the lips, cheeks and tongue.
- Dental factors: the size of the dentition in relation to the size of the dental arches.

### **Skeletal factors:**

Excluding any pathological condition, the teeth are supported by the alveolar bone, which in turn is based on the basal bone of the jaws, therefore jaw bone can be subdivided into alveolar bone and basal bone, although both of them are belonged to the same bone.

As the teeth are set in the jaws, the relationship of the jaws to each other will influence the relationship of the dental arches. Jaw relationship can be considered as:

**a) Jaws in relation to the cranial base:**

Jaws are part of the head therefore each jaw may vary in its positional relationship to other structures of the head. Such variation can occur in sagittal, lateral and vertical planes. In orthodontic diagnosis it is usual to relate the position of upper and lower jaws to the anterior cranial base and each jaw can vary independently in its relation to the cranial base.

**b) Jaws in relation to each other:**

The relationship of the jaws to each other can also vary in sagittal, lateral and vertical planes, and variation in any plane can affect the occlusion of the teeth.

The sagittal or antero-posterior relationship of the upper and lower jaws to each other called the skeletal relationship or skeletal pattern which can be:

Skeletal class I: in which the jaws are in ideal antero-posterior relationship in occlusion.

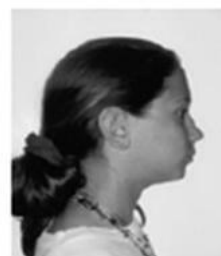Skeletal class II: in which the lower jaw in occlusion is positioned further back in relation to the upper jaw.

Skeletal class III: in which the lower jaw in occlusion is positioned further forward in relation to the upper jaw.

### **Skeletal Patterns**



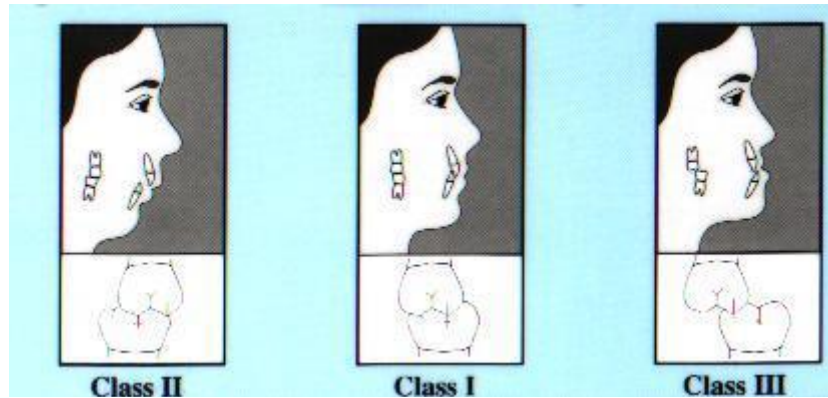
**I**



**II**



**III**



□ Variation in the skeletal relationship results from:

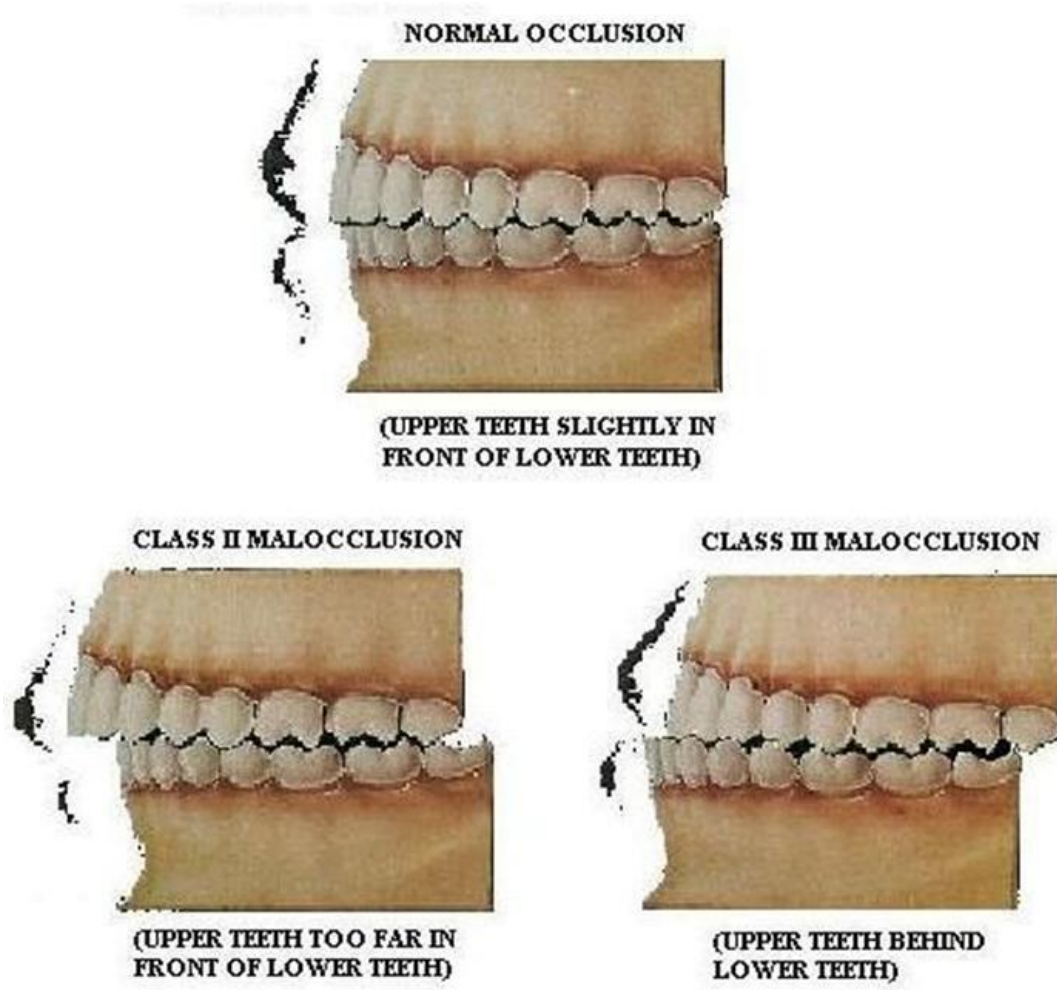
o Variation in the size and position of the jaw: In the sagittal plane if one jaw is excessively small or large in relation to the other in antero-posterior dimension the development of skeletal class II or class III relationship may result.

Also if one jaw is set further back or further forward than the other in relation to the cranial base, again skeletal class II or class III relationship may result.

In lateral plane, if the jaws match in size then the occlusion of buccal teeth in transverse relation is correct. However, if one jaw is wider than the other it may result in buccal cross bite, when lower jaw wider, or scissor bite, when the upper jaw is wider.

In the vertical plane, the effect is mostly seen with the variation in the shape of the lower jaw at the gonial angle. When this angle increased the vertical dimension of the face increased and vice versa.

c) Alveolar bone in relation to basal bone: although the alveolar bone is supported by the basal bone, the relationship between the upper and lower bones is not necessarily the same as that between the upper and lower basal bones. The alveolar bone supports the teeth and will therefore match tooth position rather than basal bone position.



Antero-posterior skeletal relationship

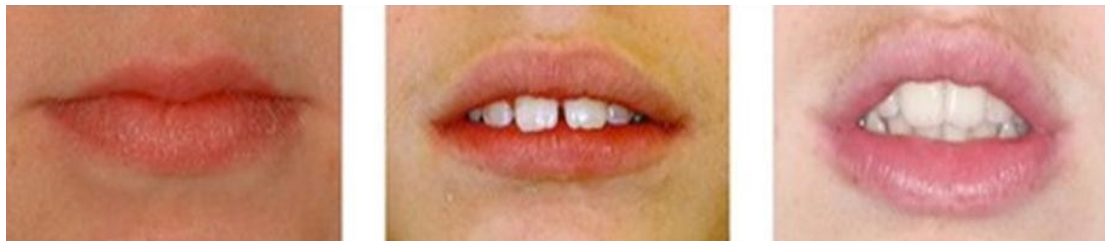**Soft tissue factors:**

The teeth erupt into an environment of functional activity governed by the muscles of face, mastication and tongue. The muscles of tongue, lips and cheeks are of particular importance in guiding the teeth into their final position and variation in muscle form and function can affect the position and occlusion of the teeth. All muscles exert their influence by their sites of origin and insertion. Since the origins of these muscles are mainly on the basal bone therefore the position of the jaws must affect the position and action of the muscles which function on the teeth.

□ **The lips:** the several muscles of the lip work as one functional unit; their effect on occlusion development depends on their form, size and function.



Vertical relationship: In the ideal lip form the lips meet together at rest position this condition called lip competence, if the lips do not meet in rest position a condition due to short upper lip and lips seal achieved only by active contraction of the orbicularis oris and mentalis muscles called lip incompetence sometimes lip seal is prevented due to malocclusion for example the protruding maxillary incisors despite normally developed lips called potentially competent lips.



Competent lips

Potentially competent lips

Incompetent lips

Lips are usually brought together during swallowing and speech movements. If they are of sufficient size to be together at rest then lip closure will not place extra force on the teeth. If the lips at rest are apart, then muscular contraction will be required to bring them together during swallowing and speech, which in turn will impose extra forces on the erupting teeth. The effect of these forces on the erupting teeth depends on the sagittal relationship of the lips.

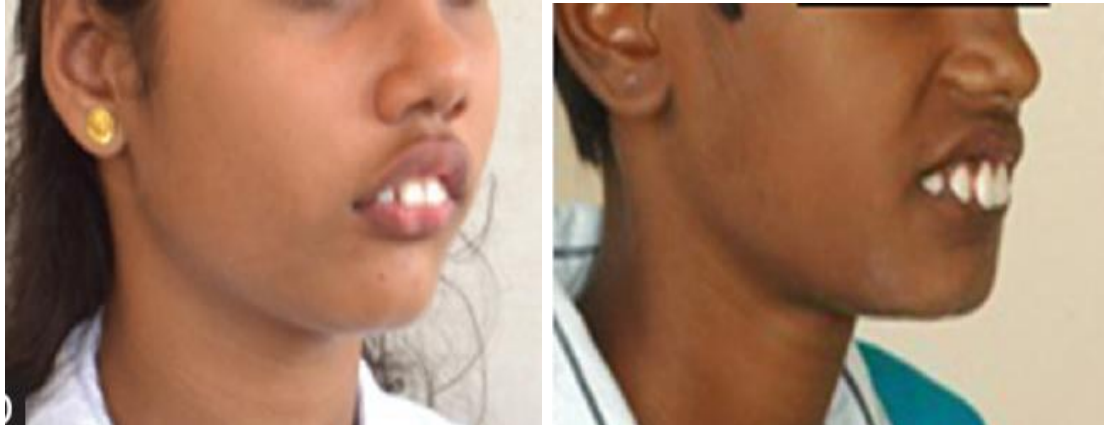The sagittal relationship: it is determined by the relationship of the basal bone of the jaw to which they are attached. For example the lower lip tends to be further back in class II and further forward in class III, which increase the difficulty to put the lips together and may cause the lower lip to modify the eruptive path of the incisors.

----- In skeletal class II the lower lip may function completely or partially behind the upper incisors. For example


-----In not severe case the lower lip may procline the upper incisors resulting in more severe class II than skeletal relationship.



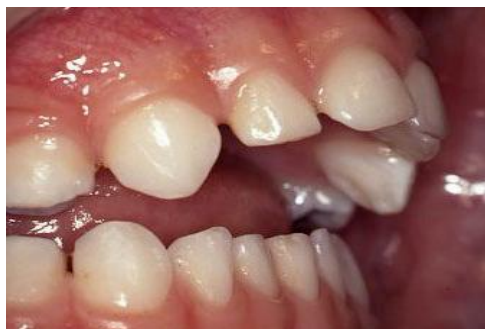-----In more sever skeletal discrepancy the lower lip may function behind the upper incisors without causing them to be proclined.



----- In other skeletal class II the lower lip function entirely in front of upper incisors causing them to be retroclined into the class II division 2 incisor relationship.



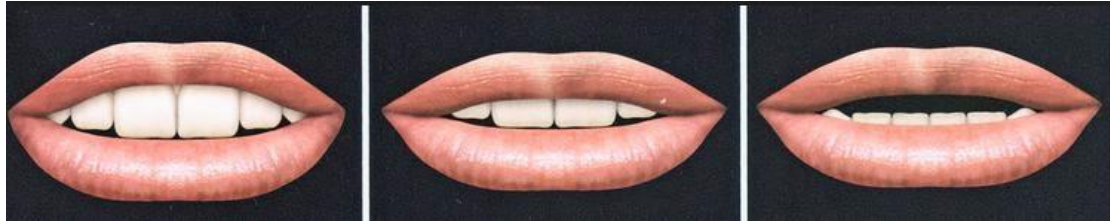----- The lower lip may cause retroclination of the lower incisors during swallowing, speech or smiling activities.



Lip line:

The level at which the lips meet together in normal function. The ideal lip line is approximately at the center of the crowns of the upper incisors with the lower lip in front of the upper incisors. If it is low part of the

lower lip may function behind the upper incisors causing proclination, if it is completely behind upper incisors there will be no lip line as in class II. It is high in class II division 2 causing retroclination of upper incisors.



high lip line

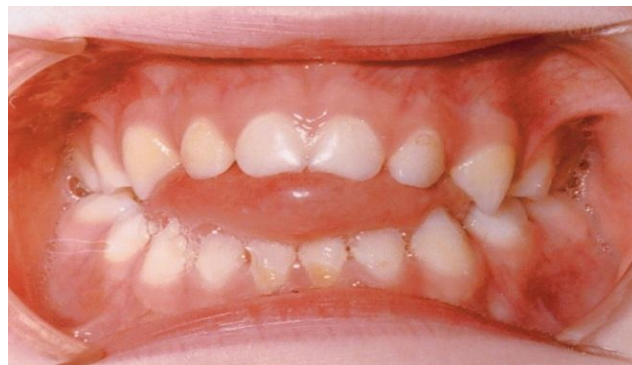normal lip line

low lip line

### **Tongue:**

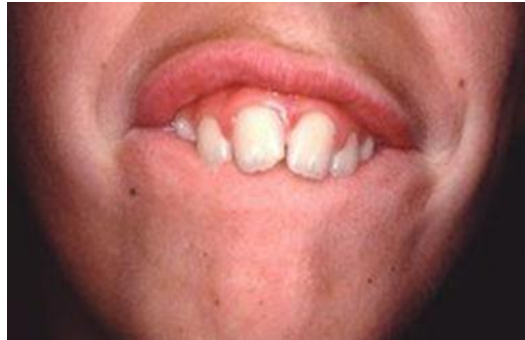The tongue functioning, in conjunction with the lips and cheeks, in guiding the erupting teeth, and this affected by its size, its resting posture and its function.

The size of the tongue is mainly related to the size of the lower jaw. If the lower jaw is larger than the upper jaw, the tongue is too large to fit within the upper arch, therefore tongue finds space between upper and lower arches and prevents full vertical development of the dentoalveolar structures resulting in open bite.



The resting position of the tongue is ideally within the dental arches, filling the space enclosed by the teeth. Sometimes the tongue takes up an adaptive postural position, slightly protruded between teeth to touch the lower lip which will prevent the full vertical development of the incisal segment resulting in incomplete over bite. This is produced to seal the front of the mouth to allow nasal breathing (tongue lower lip anterior oral

seal instead of lips oral seal) when there is difficulty to hold the lips together due to vertical or sagittal lip discrepancy.



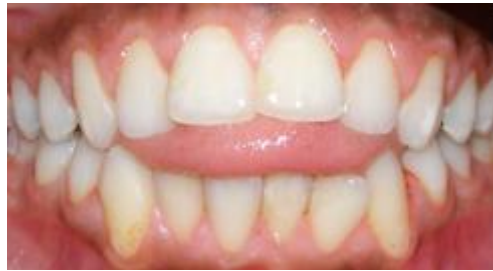The function of the tongue is concerned with mastication, swallowing and speech. Its effect on the dentition is mostly related to swallowing. After the food mastication is completed, the swallowing of food and saliva take place in sequence as: a) closure of the lips; b) teeth in light occlusal contact; c) tongue elevated to the palate, and d) momentary clenching of the teeth as food pass into the pharynx.

Variation of normal swallowing are also seen which may be described as:

1- Adaptive swallowing: involves positioning of the tongue between teeth during swallowing and may be carried out with the buccal teeth apart (tongue positioned between teeth, reduce the muscle and air pressures within the upper arch lead to narrow arch and buccal cross bite also prevents the full vertical development of the anterior dento-alveolar segment result in incomplete over bite), or buccal teeth together (lead to incomplete overbite or anterior open bite due to forward position of tongue)

2- Swallowing with endogenous tongue thrust: swallowing activity is accomplished by an anterior thrust of the tongue which is a basic neuromuscular mechanism. It sometimes associated with anterior lisp during speech. It prevents the full vertical development of the anterior dento-alveolar segments resulting in an incomplete over bite or anterior open bite.

These two variations have somewhat similar effects on developing occlusion however, they respond differently to orthodontic treatment designed to reposition the teeth. The adaptive tongue will be changed if the teeth are moved but the endogenous tongue not and will reproduce the original tooth position if these are altered.

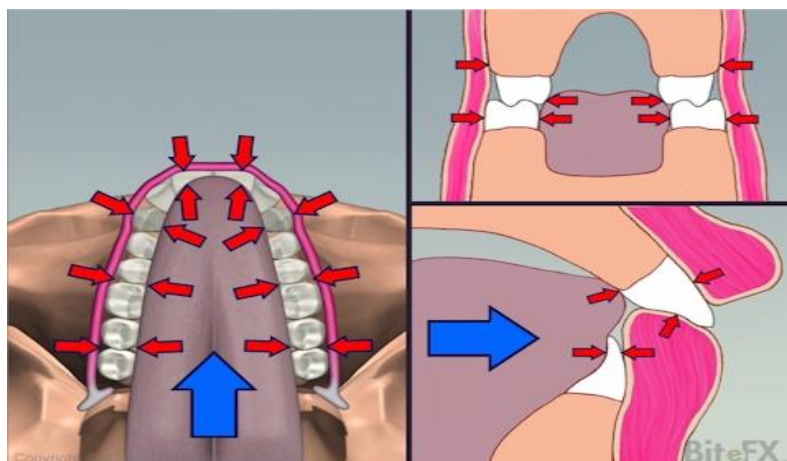


### **Neutral zone**

The fact that the lips and cheeks function outside and the tongue within the dental arches has led to the concept of a neutral zone existing between the inner and outer perimeters of the dental arches, where the forces of lips and cheeks on one hand and of the tongue on the other are balanced and within which the teeth are positioned.

This zone should be considered not only in relation to muscle forces but also in relation to intra oral air pressures which are induced by mandibular positions and movements, and to occlusal contacts and the periodontal ligament.

It is important to keep the teeth in the neutral zone at the end of the orthodontic treatment otherwise they will move to take up other positions.



**Dental factors:**

The third general factor affecting the occlusion of the teeth is the relationship between the size of the dentition and the size of the jaws. Ideally, there should be adequate space for the teeth to erupt into the mouth without crowding or spacing. In primary dentition the ideal situation exists when there is spacing between the anterior teeth that will give better chance for permanent incisors to erupt without overlapping.

The disproportion between teeth size and arch size can be:

- Excessive dentition size in relation to dental arch size which can have:

----- Overlapping and displacement: when the dental arch is too small for the dentition or teeth too large for the dental arch or both, the teeth will be displaced. The most affected teeth are the last teeth in each group i.e. lateral incisors, second premolars, canines and third molars.

----- Impaction of the teeth: occurs when eruption of teeth is completely blocked by other teeth due to crowding, also it affects the last tooth in each segment.

-----Mesial movement of the teeth: either associated with alveolar growth as part of dentoalveolar forward development also called mesial migration, or movement of individual tooth into space created by interproximal attrition or loss of the teeth, this can occur any time during or after growth period.

-- Excessive dental arch size in relation to dentition size: it is less common, occur when there is too small teeth in relation to the size of the dental arch or too large dental arch in relation to the size of the dentition or both which will result in spacing. The size of the dental arch may not be the same as the size of the basal bone because skeletal relationship and muscular factors can produce a dental arch which is larger or smaller than the basal bone; therefore dentition size should be considered in relation to dental arch rather than jaw size.

**Local factors:**

Local factors can be classified as follow:

*1- Anomalies of number*

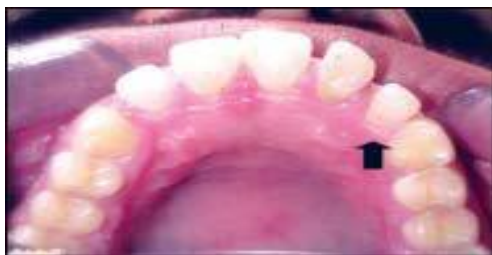Each jaw is designed to hold only a specific number of teeth at a particular age. The anomalies in the number of teeth can be of two types:

**(i) Increased number of teeth or supernumerary teeth:**

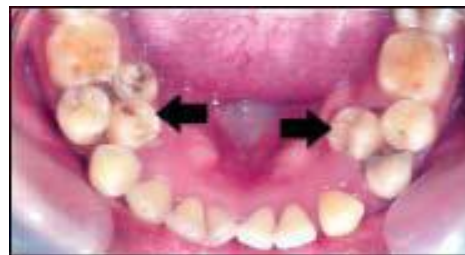Supernumerary teeth can vary remarkably in size, shape and location.

They may be:

----- Supplemental teeth: which bear a close resemblance to a particular group of teeth and erupt close to the original sight of these teeth, i.e. incisors, premolars or molars, etc.

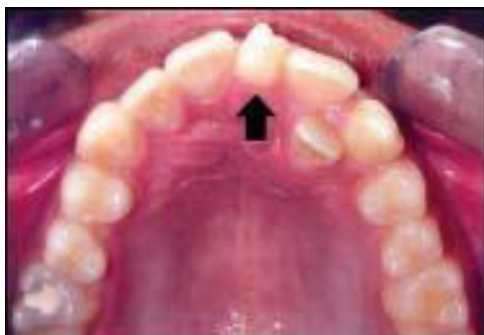

Supplemental tooth in the maxillary lateral

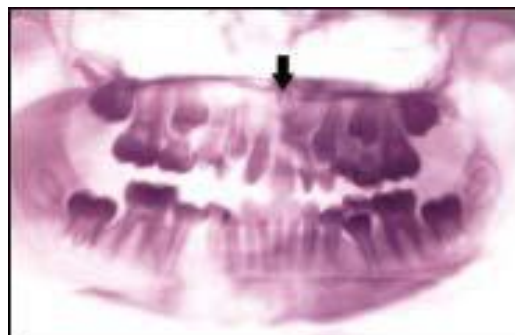


Supplemental teeth in the mandibular pre-molar

----- Mesiodens: it is the most commonly seen supernumerary tooth. It is usually conical in shape with a short root and crown, situated between the maxillary central incisors and can vary considerably in shape. It can be seen erupted or impacted, singular or in parts. It can occur in the maxilla or in mandible.



Erupted mesiodens

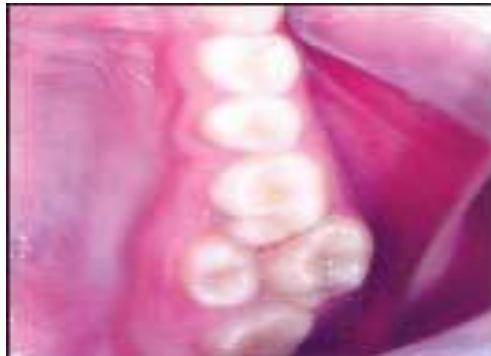

An impacted inverted maxillary



Supernumerary teeth can cause

- a. Non-eruption of adjacent teeth.
- b. Delay the eruption of adjacent teeth.
- c. Deflect the erupting adjacent teeth into abnormal locations.



Supernumerary tooth on the maxillary molar region has deflected the second permanent molar

- d. Increase the arch perimeter (increasing the over jet if in the maxillary arch or decreasing the over jet if seen in the mandibular arch).
- e. Crowding in the dental arch.

(ii) Less number of teeth or missing teeth

Congenitally missing teeth are more commonly seen in comparison to supernumerary teeth. It can be anodontia or hypodontia or oligodontia.

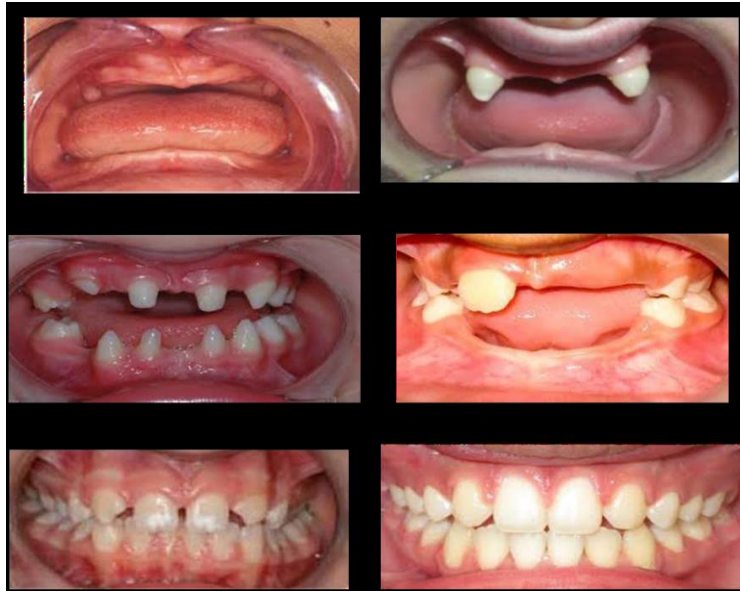Anodontia: characterized by the congenital absence of all primary or permanent teeth. It is divided into 2 subsections, complete absence of teeth or partial absence of teeth

Hypodontia, usually missing 1 or 2 permanent teeth,

Oligodontia is the congenital absence of 6 or more teeth.

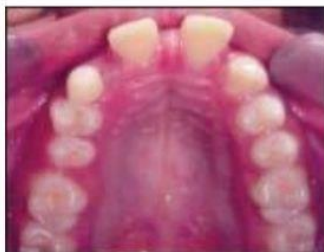The most commonly congenitally missing teeth are the third molars, followed by the maxillary lateral incisors.



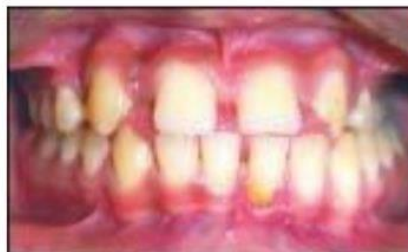

Congenitally missing teeth can lead to:

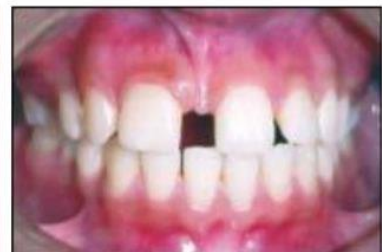- a. Gaps between teeth.
- b. Aberrant swallowing patterns.
- c. Abnormal tilting/axial inclination or location of adjacent teeth.
- d. Multiple missing teeth can cause a multitude of problems.



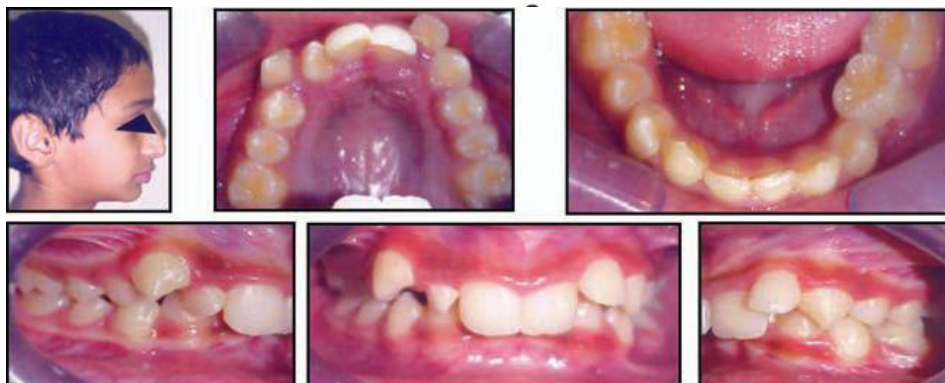Spacing between teeth due to missing maxillary lateral incisors



Tongue thrust habit developing due to the congenital absence of the maxillary lateral incisors



Abnormal position of the maxillary right central incisor in contact with the right canine due to the absence of the right lateral incisor



Multitude of problems caused due to missing mandibular central incisors. Retrognathic mandible, convex profile, anterior deep bite, maxillary anterior crowding and end-on molar relationship

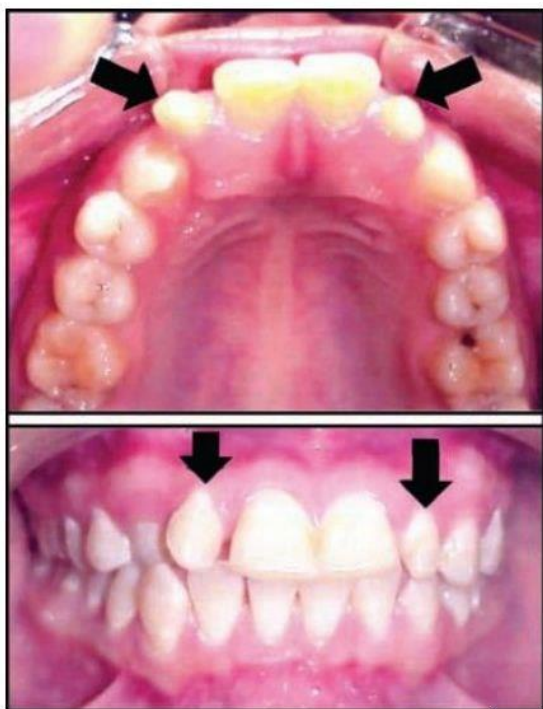
## 2- Anomalies of tooth size

It includes macrodontia and microdontia, which can be localized or generalized.

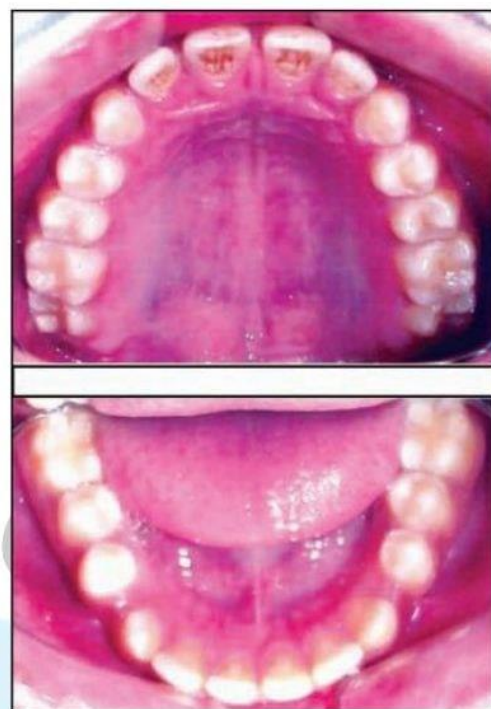----- The true generalized macrodontia, where all the teeth are larger than normal is seen in cases of pituitary gigantism.

----- The true generalized form of microdontia, where all the teeth are small is rarely seen. It is usually associated with cases of pituitary dwarfism.

The most commonly seen *localized microdontia* involves the maxillary lateral incisors. The tooth is called a ‘peg lateral’ and exhibits a peg shaped crown with the mesial and distal sides converging incisally. The root may be shorter and more cylindrical than normally seen. *Relative generalized microdontia* may also be seen, but should be considered as an illusion of the true condition.



Peg-shaped maxillary lateral incisors



Relative generalized microdontia. Here the jaws are too big for normal sized teeth

***My great wishes for my lovely students for success. Thanks***

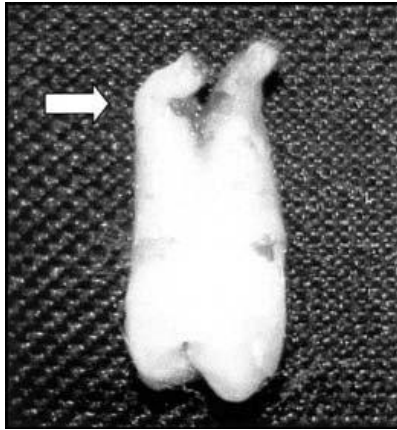
# Orthodontics

## *Etiology of malocclusion*

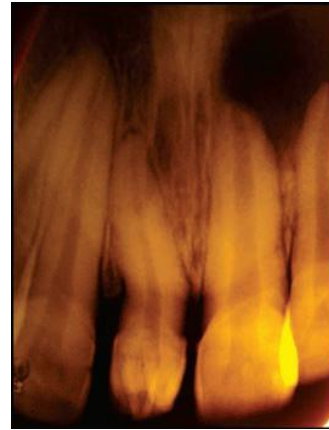### *3- Anomalies of tooth shape*

Anomalies of tooth shape include dilacerations, true fusion, gemination, concrescence, talon cusp, and 'dens in dente'.

□ Dilaceration is an anomaly of the tooth shape in which there is a sharp bend or curve in the root or crown. It generally does not affect

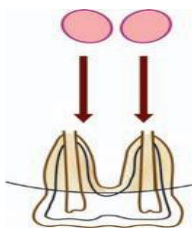


Dilacerated roots of a maxillary first pre-molar

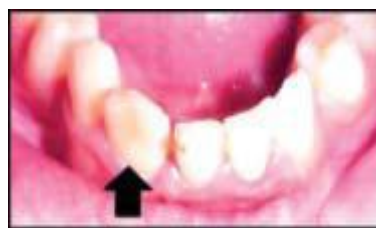

Dilacerated roots might also create problems when they have to be aligned

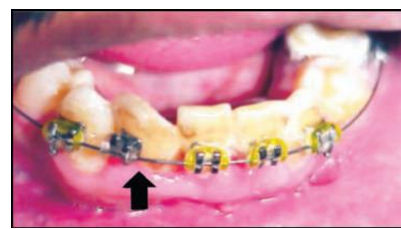
□ True fusion is seen when the tooth arises through the union of two normally separated tooth germs. It might lead to spacing or sometimes it might complicate its movement by orthodontic means.



Fusion



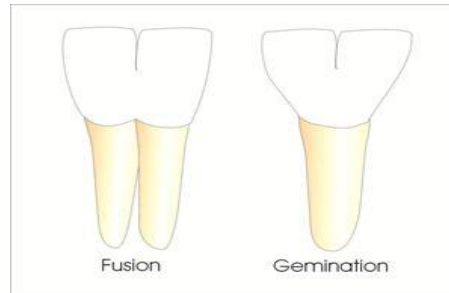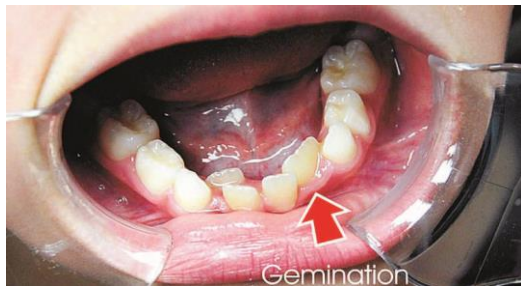True fusion



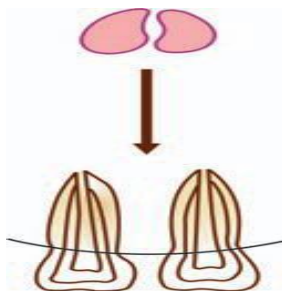
A larger bracket is required to attain proper rotational control of the tooth



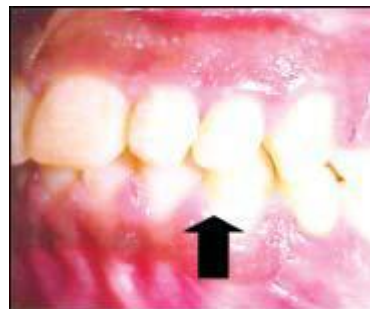□ Geminated teeth are anomalies, which arise from division of a single germ by an invagination, leading to the formation of two incomplete teeth.



The term 'twinning' has been used to designate the production of equivalent structures.

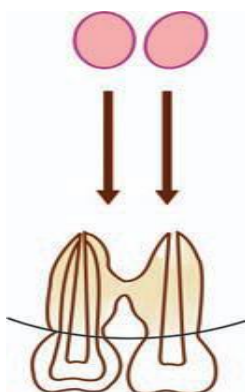


Twinning

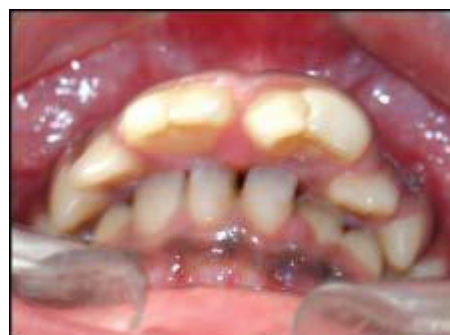

Two near equal sized teeth in place of the maxillary left lateral incisor

Concrescence refers to fusion of cementum of teeth which occurs after root formation has been completed.



Concrescence

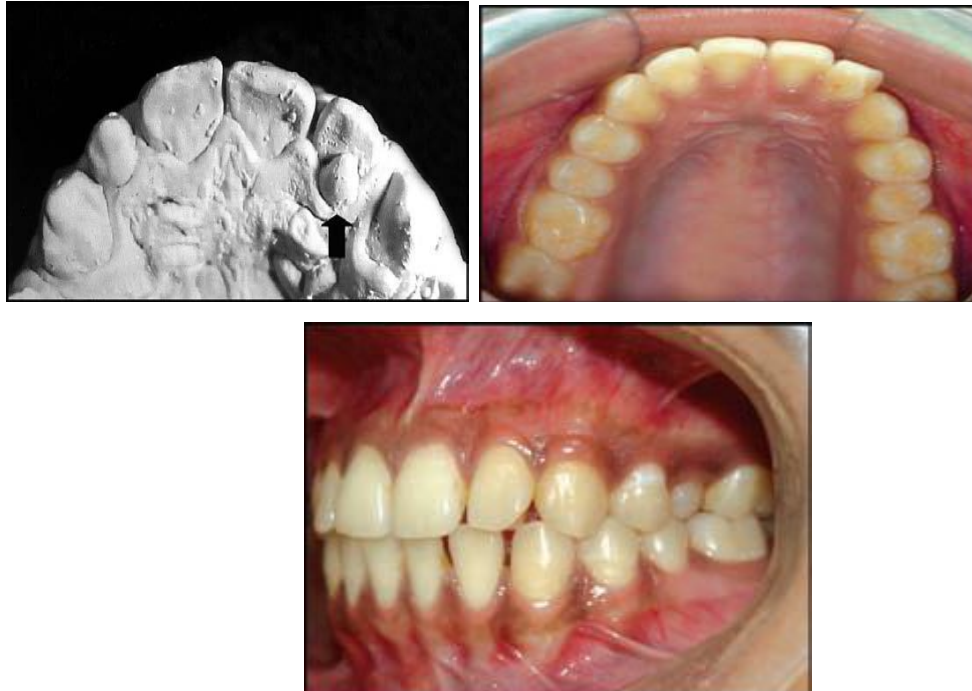


Concrescence following root complete

The talon cusp is an anomalous structure projecting lingually from the cingulum area of a maxillary or mandibular permanent incisor. It might interfere in proper occlusion. It's grinding invariably leads to pulpal

exposure necessitating root canal treatment.

The term 'Dens in Dente' is used to denote a developmental variation which radiographically may resemble a tooth within a tooth.



Talon's cusp on the right lateral incisor preventing its ideal alignment in the arch, it appears to be rotated mesio-palatally.

#### *4- Abnormal labial frenum*

At birth the labial frenum is attached to the alveolar ridge with some fibers crossing over and attaching with the lingual dental papilla. As the teeth erupt, bone is deposited and the frenal attachment migrates superiorly with respect to the alveolar ridge. Some fibers may persist between the maxillary central incisors. These fibers which persist between these teeth are capable of preventing the two contralateral central incisors from coming into close approximation. This space called a midline diastema which may occur due to various causes:

1. Deciduous dentition
2. Ugly duckling stage
3. Racial predisposition, Negroids
4. Microdontia

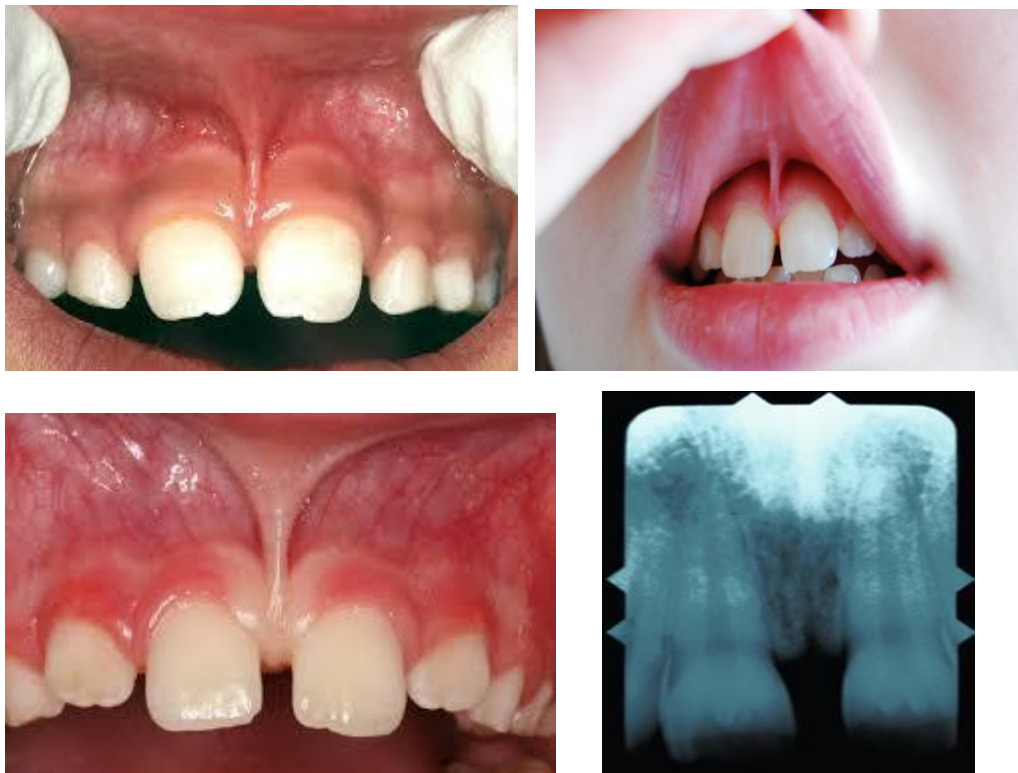5. Congenital absence of lateral incisors
6. Supernumerary tooth in the midline
7. Abnormal frenal attachment
8. Abnormal pressure habits (digit sucking and tongue thrust habit)
9. Trauma
10. Impacted tooth in the midline

A specific test used to determine the role of frenum as a causative factor called the 'blanch test' which can be done as follow:

Step 1: The lip is pulled superiorly and anteriorly

Step 2: Any blanching in the interdental region is indicative of the fibers of the frenum crossing the alveolar ridge

Step 3: The blanch test can be collaborated with an IOPA of the region which shows a slight radiolucent wedging/notching in the interdental alveolar ridge region



Labial frenum, blanch test, intraoral periapical radiograph

### *5- Premature loss of deciduous teeth*

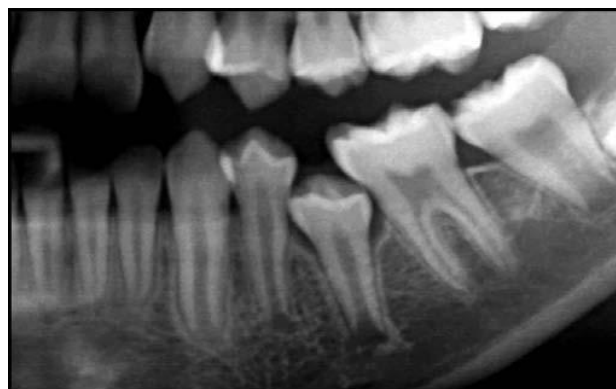The premature loss of a deciduous tooth can lead to malocclusion only if the succedaneous tooth is not close enough to the point of eruption.

When the permanent tooth does not erupt following the loss of the deciduous tooth, the adjacent teeth get time to migrate in its space. This can lead to the mesial migration of the posterior teeth result in a decrease in the overall arch length. This might cause the permanent successor to erupt malpositioned or get impacted or cause a shift in the midline (in case of anterior teeth).

In case an anterior deciduous is lost prematurely; there is a tendency for spacing to occur between the erupted anterior teeth. It might also lead to a shift in the midline, towards the side where the deciduous tooth has been lost.

If one of the posterior deciduous teeth is lost, especially the deciduous second molars, the first permanent molars erupt mesially. This might lead to a loss in the arch length. This is seemed most commonly in the maxillary arch where there is lesser space for the canine to erupt; therefore it may erupt labially.

Mesially tilting of the erupted mandibular first molars may cause the second premolars to remain impacted



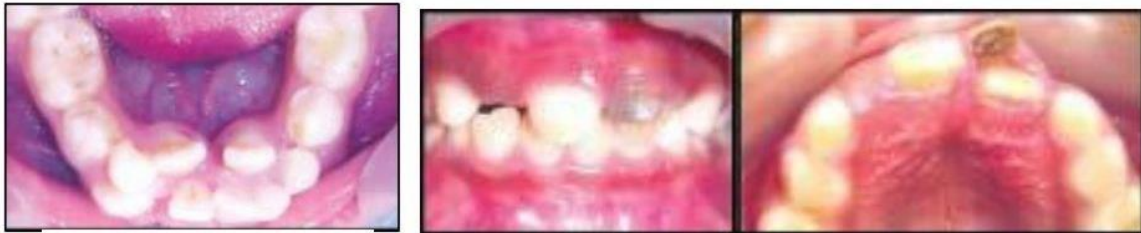Mesial tilting of the mandibular 1st permanent molars leading to a decreased space for the eruption of the 2nd premolars



### *6- Prolonged retention of deciduous teeth*

Any deciduous tooth may be retained beyond the usual eruption age of their permanent successor, this may cause:

- i. Buccal/labial or palatal/lingual deflection in its path of eruption;
- ii. Impaction of the permanent tooth



Lingually erupting mandibular lateral incisors, due to over retained deciduous teeth

Left maxillary central incisor deflected palatally into cross-bite

Most commonly impacted tooth is the maxillary canine (third molars not taken into account). The reasons for this include:

- i. It is the last anterior tooth to erupt
- ii. Space occupied by the deciduous canine is less than the mesiodistal width of the permanent canines
- iii. The premolars might migrate mesially leaving limited space for the canines to erupt
- iv. It has the longest path of eruption
- v. Controversially, as it may seem, it is the only tooth to erupt after root completion.

### *7- Delayed eruption of permanent teeth*

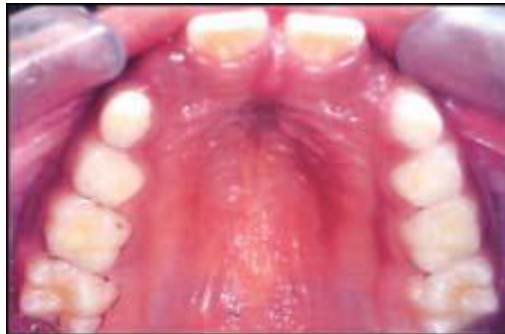The sequence of eruption has a certain amount of flexibility; but if one of the teeth does not occupy its designated place in this sequence there is a likelihood of migration of other teeth into the available space.

As a result the tooth whose eruption has been delayed might get displaced or impacted. Various reasons have been attributed for the delay eruption of the permanent teeth:

1. Early loss adjacent primary teeth with a consequential flaring or

spacing between erupted permanent teeth. This may lead to decreased space availability for eruption of the succedaneous teeth.

2. Early loss of primary tooth leading to mucosal thickening over the succedaneous tooth. The mucosa might have to be incised to accelerate eruption.



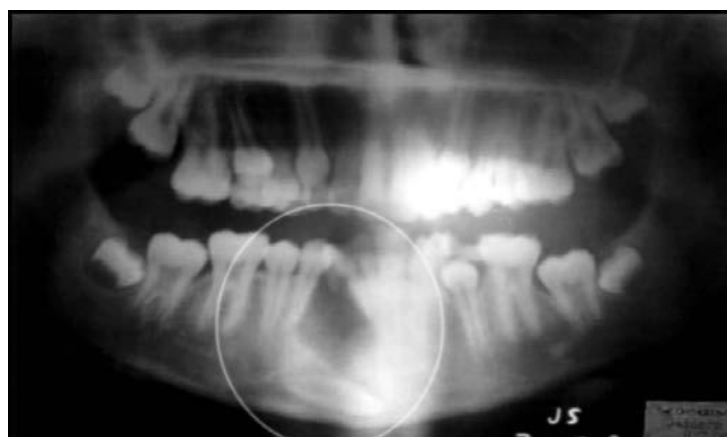Mucosal thickening over the lateral incisors preventing their eruption

3. Early loss of the primary tooth might cause excessive bone deposition over the succedaneous tooth

4. Hereditary, in certain children teeth erupt much later than established norms

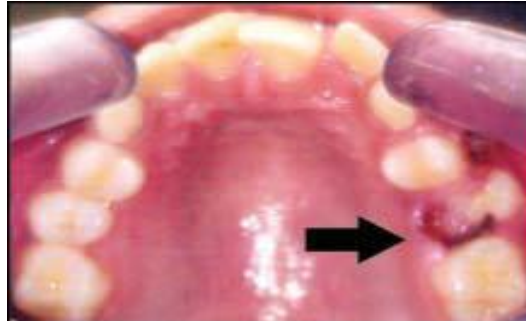5. Presence of supernumerary tooth can block the erupting permanent tooth.

6. Presence of odontomas or other cysts and tumors (in the path of eruption) might prevent the permanent tooth from erupting



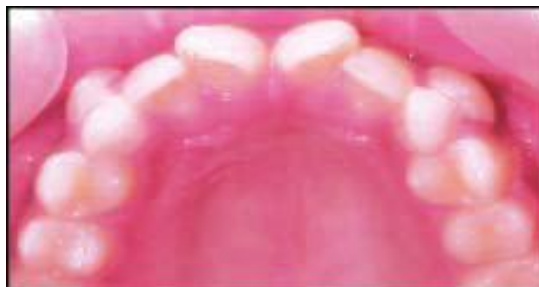Impacted canine and destruction associated with a cystic growth in the mandible

7. Presence of deciduous root fragment that are not absorbed can block the erupting tooth or may deflect it preventing its eruption in an ideal location.



Retained roots of the deciduous 2nd molar deflected the erupting 2nd pre-molar buccally

8. Presence of ankylosed deciduous teeth. These might not get absorbed causing a delay in the eruption of the permanent tooth.



Ankylosed deciduous canines, which did not exfoliate on time, resulted in labially erupting permanent canines

9. The succedaneous tooth might be congenitally missing, delaying the loss of the primary tooth

10. In certain endocrine disorders the eruption of permanent teeth might be delayed, e.g. hypothyroidism.

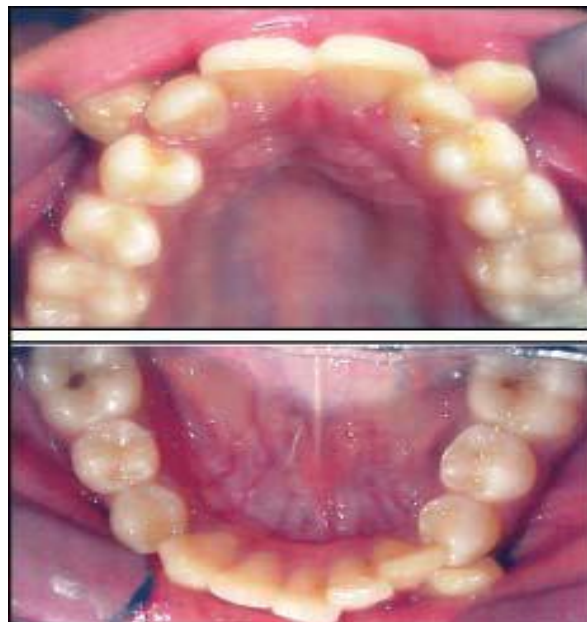Whatever the reasons for the delay in eruption, it is important to maintain and if required to create space for its eruption.

Proper knowledge of preventive and interceptive orthodontics can definitely reduce the occurrence of malocclusions, if not prevent them from occurring; this can significantly reduce the severity of the malocclusion.

### *8- Abnormal eruptive path*

Each tooth travels on a distinct path from its inception to the location at which it erupts. It can deviate from this eruption path because of many reasons:

1. Tooth bud facing and/or placed or displaced from its ideal location
2. Presence of a supernumerary tooth may divert a tooth from its eruptive path
3. Presence of odontomas or a cyst may divert it if not altogether prevent its eruption.
4. Unresorbed or retained deciduous teeth might force a tooth to erupt along a path of least resistance rather than in place of the deciduous tooth
5. Retained root fragments (especially of deciduous molars) may deflect an erupting permanent tooth
6. A true arch length deficiencies or excess of tooth material may cause one or more teeth to deviate from their eruptive path



A true arch length deficiency

The tooth that most frequently erupts in an abnormal location is the maximally canine. Various reasons have been attributed for this behavior. These include:

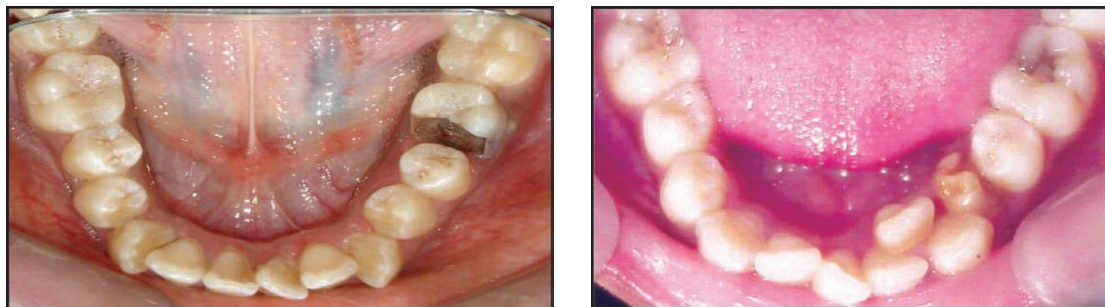
- a. It travels the longest distance, from near the floor of the orbit to the cover of the arch.
- b. It is the last anterior tooth to erupt and loss in arch length— anterior or posterior may impinge on the space required for its eruption.
- c. Abnormal position of the tooth bud. Ideally it should slide along the distal aspect of the root of the lateral incisor. Any problem in the position of the lateral incisor may divert the erupting canine.

*9- Ankylosis*

Ankylosis is a condition which involves the union of the root or part of a root directly to the bone, i.e. without the intervening periodontal membrane. Ankylosis of teeth is seen more commonly associated with certain infection, endocrine disorders and congenital disorders, e.g. Cleidocranial dysostosis, but these are rare occurrences. It should be suspected in cases where there is a past history of trauma, or a mobile tooth has regained stability.

*10- Dental caries*

Proximal caries are especially to blame for the reduction in arch length. This might be brought about by migration of adjacent teeth and/or tilting of adjacent teeth into the space available and/or supra-eruption of the teeth in the opposing arch. A clear reduction in arch length can be expected if several adjacent teeth involved by proximal caries are left unrestored. This is especially true for deciduous molars.



Proximal decay in the 1st molar leading to decreased arch length      Mesial migration of the left posterior segment due to the presence of a grossly decayed deciduous 1st molar

Also caries can lead to the premature loss of deciduous or permanent teeth which can by themselves cause malocclusion.

### *11- Improper dental restorations*

Improper dental restorations can cause malocclusion. How?

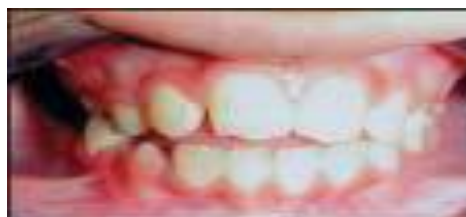- Under contoured proximal restoration can lead to a significant decrease in the arch length especially in the deciduous molars.
- Over contoured proximal restorations might bulge into the space to be occupied by a succedaneous tooth and result in a reduction of this space.
- Overhang or poor proximal contacts may predispose to periodontal breakdown around these teeth.
- Premature contacts on over contoured occlusal restoration can cause a functional shift of the mandible during jaw closure,
- Under-contoured occlusal restorations can lead to the supra-eruption of the opposing dentition.

### *Abnormal pressure habits and functional aberrations*

These are possibly the most frequently encountered causes of malocclusion.

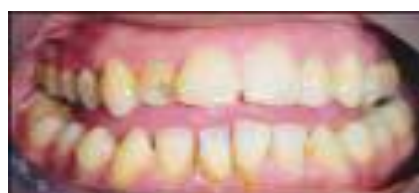These include:

- a. Abnormal sucking
- b. Thumb and finger sucking.



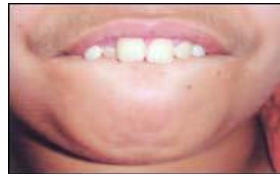Patient with a thumb sucking habit

- c. Tongue thrust and tongue sucking.





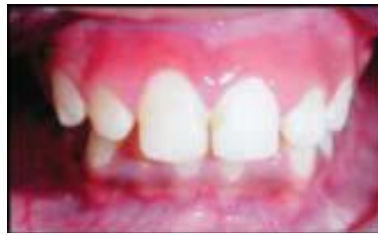d. Lip and nail biting.



e. Abnormal swallowing habits (improper deglutition)

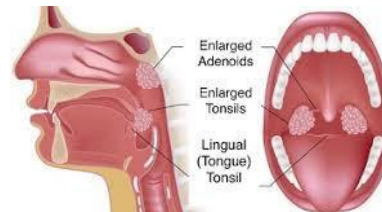
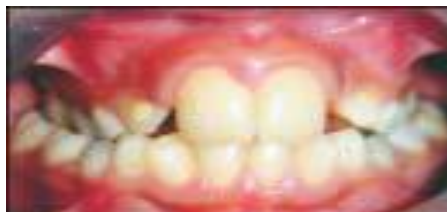f. Speech defects

g. Respiratory abnormalities (mouth breathing, etc.).



Typical features of a mouth breather. Note the gingival inflammation in the maxillary anterior region

h. Tonsils and adenoids



Patient suffering from enlarged adenoids

i. Psychogenic habits and bruxism.

All of these habits are functional abrasions which produce forces that are abnormal. Since these forces are produced repeatedly over time they are capable of bringing about a permanent deformity in the developing musculoskeletal unit.

The deformity produced depends upon the intensity, duration and frequency of the habit. The effect of habits basically follows the functional matrix theory of growth as proposed by Moss—in its simplest form it says that—“function creates form and normal function creates normal form”.

*My great wishes for my lovely students for success. Thanks*

# Orthodontics

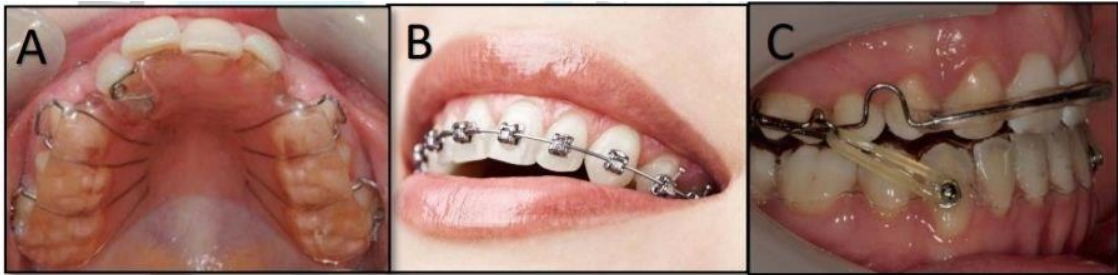
## Orthodontic Appliances: An overview

Orthodontic Appliances can be defined as ‘devices, which create and/or transmit forces to individual teeth/a group of teeth and/or maxillo-facial skeletal units so as to bring about changes within the bone with or/without tooth movement which will help to achieve the treatment goals of functional efficiency, structural balance and esthetic harmony’.

**Orthodontic appliances can be classified:**

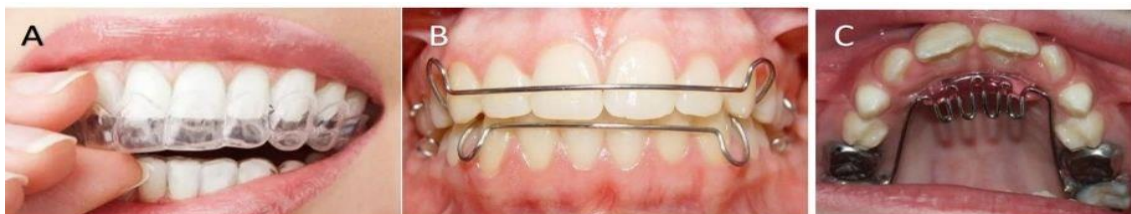### 1. According to the mode of action into:

**A. Active appliances:** is one that uses some kind of force to move teeth into the desired position for example removable, fixed, orthopedic and myofunctional, combination, space regainer, and clear aligner.



Active Orthodontic appliances. A: Removable; B: Fixed Active orthodontic appliance. C: Combination (fixed and removable) appliance.

**B. Passive Appliances:** is one that holds the teeth in place mostly after active treatment has been completed, for examples retainers, habit breaker and space maintainer.



Passive Orthodontic appliances. A: Essix retainer; B: Hawley retainers; C: Fixed Habit breaker

## 2. According to the patient's ability to remove the orthodontic appliance into:

**A. Removable appliances:** are those that can be removed by the patient.

**B. Fixed appliances:** includes those appliances fixed to the teeth and the patient cannot remove.

**C. Combination:** have some part of the appliance fixed on to the tooth surfaces which the patient cannot remove but the rest of the appliance can be removed.

### Mechanical Orthodontic Appliances

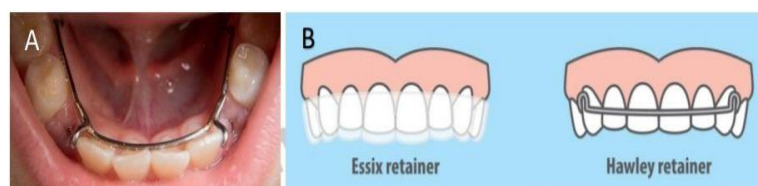
Mechanical orthodontic appliances possess active components, which are themselves capable of generating forces. These appliances are capable of generating forces that can move individual teeth, group of teeth and /or the jaws. Mechanical appliances may be fixed or removable.

#### I. Removable Appliances

As the name suggests, these appliances can be removed from the mouth by the patient. The patient can insert and remove these appliances without the intervention of a clinician. They may be active or passive, depending upon their capability to exert/ generate forces.

□ **Active removable appliances:** are designed to achieve tooth movement (mainly tipping) by means of active components, e.g. wire springs, screws etc. They are capable of generating tooth moving forces.

□ **Passive removable appliances:** are designed to maintain teeth in their designated or present position, e.g. space maintainers, retainers etc.

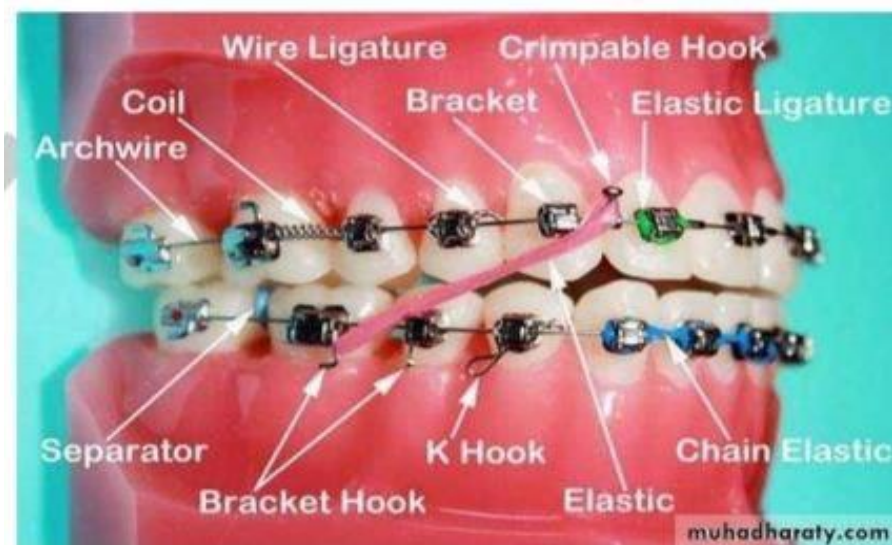

Passive Removable appliances. A: Removable space maintainer; B: Removable retainers (Essix, Hawley).

## II. Fixed Appliances

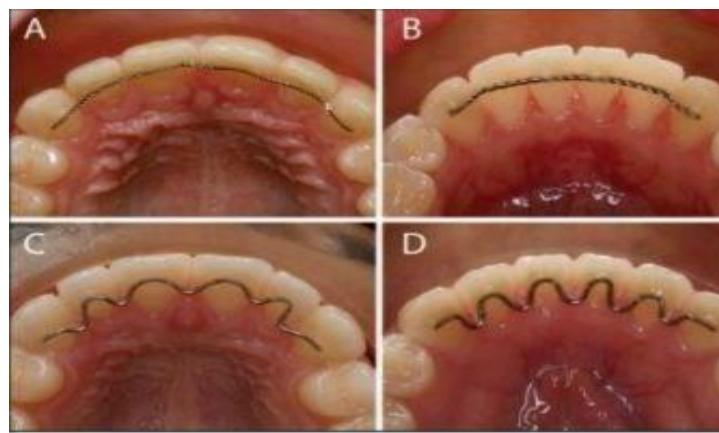
Fixed appliances are orthodontic devices in which attachments are fixed to the teeth and forces are applied by arch wires or other auxiliaries via these attachments. These can be further classified as active and passive, depending upon their ability to generate forces.

□ **Active fixed appliances:** are attached (fixed) onto the tooth surface and are capable of generating forces which are capable of bringing about tooth movements.



Active Fixed appliances and its components.

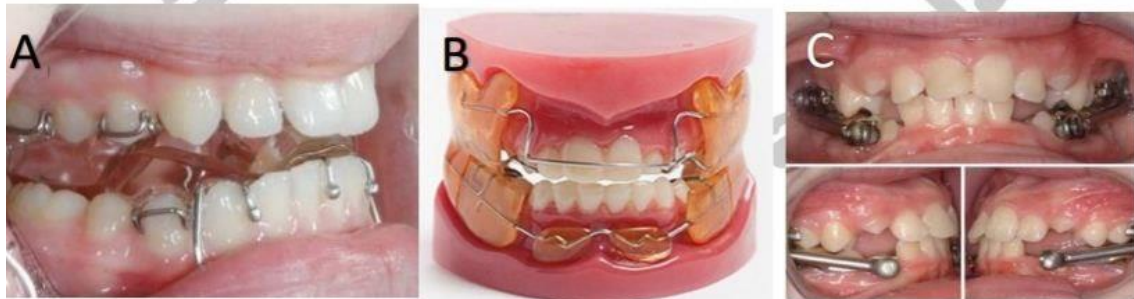
Passive fixed appliances: do not generate forces and are responsible for maintaining the attained position of the teeth, e.g. fixed retainers, fixed space maintainers, etc.



Passive Fixed appliances. Types of Fixed retainers.

## **Functional Orthodontic Appliances**

These are appliances which engage both arches and act principally by holding the mandible away from its resting position, they harness and transmit the natural forces of the circum oral musculature to the teeth and/or alveolar bone. These appliances generally cause a change in the surrounding soft tissue envelope of the teeth thereby leading to a more harmonious relationship of the jaws to each other and to the other bones of the facial skeleton, e.g. the Frankel appliance. They can be either fixed or removable.



Functional appliances. A: Twin block appliance (removable). B: Frankel Appliance (removable). C: Herbst appliance (fixed).

## **IDEAL REQUIREMENT OF AN ORTHODONTIC APPLIANCE**

All appliances, which are used with the purpose of bringing about orthodontic tooth movement, should fulfill certain requirements. The appliances should try to fulfill most of these requirements even though no single appliance till date has managed to fulfill all of these. These requirements can be considered under the following three headings:

- Biologic requirements
- Mechanical requirements
- Esthetic requirements.



## □ **BIOLOGIC REQUIREMENTS**

1. Bringing the desired tooth movement.
2. It should not have a detrimental impact on the teeth, and/or periodontium. For ex: it should not lead to root resorption or non-vitality of teeth etc.
3. It should move only those teeth that it is designed to move. In other words, the anchor units should remain in their original position.
4. The appliance should not hamper normal growth.
5. It should not interfere or inhibit normal functions.
6. The appliance should allow for proper oral hygiene maintenance. It should be easy to clean the appliance as well as continue with all and hygienic maintenance regimes continuity.
7. The material used in its fabrication should be biocompatible and not produce any allergic or toxic reactions.
8. The appliance should not disintegrate in the oral environment and should be able to sustain its functions in the rugged environment of the oral cavity without breakage.

## □ **MECHANICAL REQUIREMENTS**

1. The appliance should be able to deliver continuous controlled forces of the desired intensity in the desired direction.
2. The appliance should be able to withstand the routine masticatory forces and not get damaged easily.
3. The appliance should be easy to fabricate and activate.
4. It should not be bulky and uncomfortable for the patient to wear.
5. The appliance should be universally applicable and accepted, i.e. it must be able to correct various malocclusions and different orthodontists should be able to activate it similarly.

## □ **ESTHETIC REQUIREMENTS**

The appliance should be esthetically acceptable to the patient. In other



words, it should be as inconspicuous as possible. The above requirements are very stringent and no single appliance has yet been designed which incorporates all these requirements. For example- the lingual appliance fulfills the esthetic requirements most completely, yet it may interfere with proper speech, violating a biologic requirement, of not interfering with normal functions.

## **Removable Orthodontic Appliances**

### ***Mode of action of removable orthodontic appliances (ROA)***

Removable appliances are capable of the following types of OTM:

- Tipping movements.
- Movements of blocks of teeth.
- Influencing the eruption of opposing teeth.

### **Indications for the use of ROA**

In spite of the limitations of the ROA, their role has changed and it is now widely used including:

1. As an adjunct to fixed appliance treatment by an extra-oral traction to segments of teeth, or an entire arch, to help achieve intrusion and/or distal movement.
2. Arch expansion results in moving blocks of teeth.
3. A flat anterior/posterior bite-plane to influence development of the segment of teeth and/or to free the occlusion with the lower arch.
4. In a passive role, as space maintainers following permanent tooth extractions and also as retaining appliances following fixed appliance treatment.
5. Lower ROA are less well tolerated by patients due to their encroachment upon tongue space, also the lingual tilt of the lower molars makes retentive clasping difficult.

## **Advantages of ROA**

1. Removed for tooth-brushing.
2. Palatal coverage increases anchorage.
3. Easy to adjust.
4. Less risk of iatrogenic damage (e.g. root resorption) than fixed appliances.
5. Acrylic can be thickened to form flat anterior/posterior bite-plane.
6. Useful as passive retainer or space maintainer.
7. Can be used to transmit forces to blocks of teeth.

## **Disadvantages of ROA**

- 1-The key word in ROA therapy is patient compliance.
- 2- Only tipping movements possible.
- 3- Good technician required.
- 4- Affects speech.
- 5- Intermaxillary traction more difficult.
- 6- Lower removable appliances are difficult to tolerate.
- 7- Inefficient for multiple individual OTMs.

## **Designing ROA**

### **General principles**

The design of an appliance should never be delegated to a laboratory as they are only able to utilize the information provided by the plaster casts.

Success depends upon designing an appliance that is easy for the patient to insert and wear, and is relevant to the occlusal aims of treatment.

### **Steps in designing a ROA:**

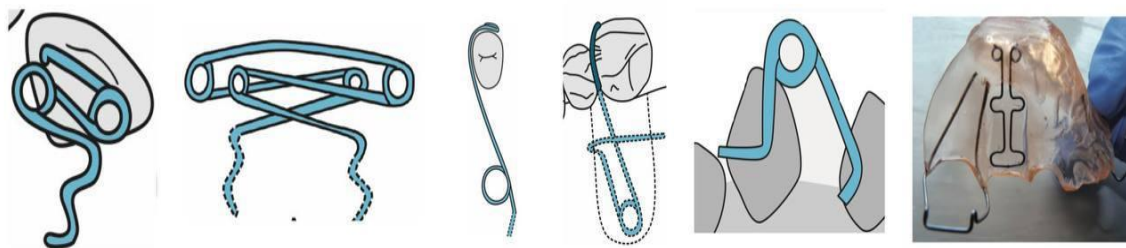
Three components need to be considered for every removable appliance:

- Active component(s);
- Retentive component(s);
- Baseplate.

## 1. Active components:

### Springs

Springs are most commonly used active component. In designing a ROA, it is essential to know the uses of each spring, mode of action, mode of activation (including time interval) and if available its modification. There are several types of active springs like z-spring, recurved z-spring, finger spring, buccal canine retractors and T-springs. Each has its uses, indications, fabrication and mode of activation.



**Types of active springs like z-spring, recurved z-spring, finger spring, Guarded finger spring, buccal canine retractors and T-springs.**

A spring is adjusted to ensure that the point of application will give the desired direction of movement. The further the spring is from the center of resistance of the tooth, the greater the degree of tilting. Therefore, a spring should be adjusted so that it is as near the gingival margin as possible without causing gingival trauma.

### Screws

Screws are active components that are used to provide intermittent forces in ROA. Screws can be used to bring about various kinds of OTM.

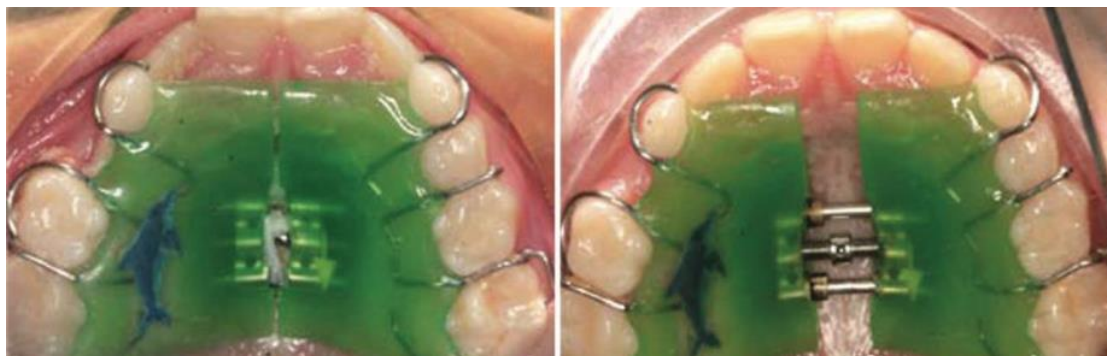A screw consists of a rod with left and right hand threads at both ends and a nut in the center, which is turned for activation. The threads turn in metal blocks that are embedded in the baseplate, which is split at right

angles to the screw.



**screw used in Removable orthodontic appliance.**

When the screw is turned, the two parts of the base plate separate and put pressure on the teeth. This causes the teeth to get slightly displaced and over time teeth move to new positions by remodeling of the overlying bone



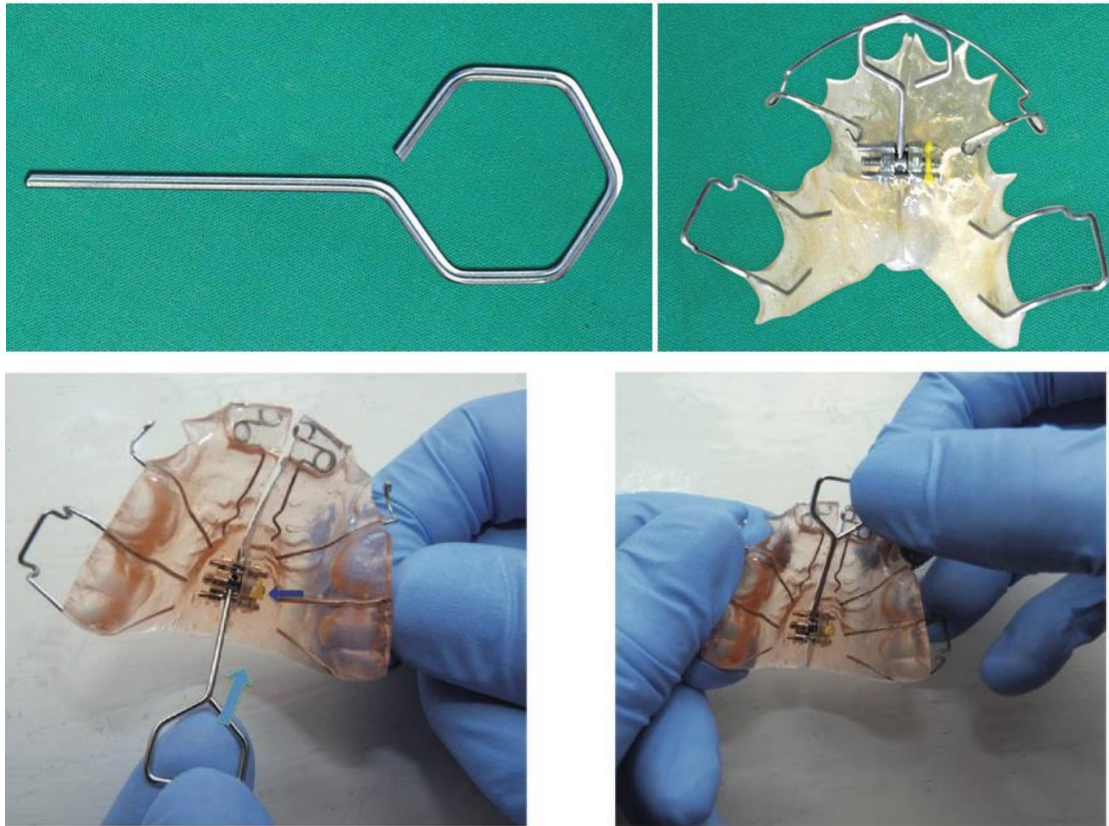
**An activated screw used in ROA, the two parts of the base plate separate and put pressure on the teeth and resulted in tooth movement and arch expansion.**

Therefore, a wide variety of OTMs are possible based on the location of the screw, number of screws and location of the split in the plate.

**Advantage of Screw over Springs:**

1. Easier to manage than those with springs.
2. Activated by the patient at regular intervals using a key, therefore, they are more valuable in patients who cannot visit the dentist frequently.
3. Fewer tendencies to get dislodged than those with springs.

4. Forces generated can be controlled, based on the amount of activation done. The patient or parent using a key activates the screw,



**A key for screw activation used in ROA. The key turned for activation.**

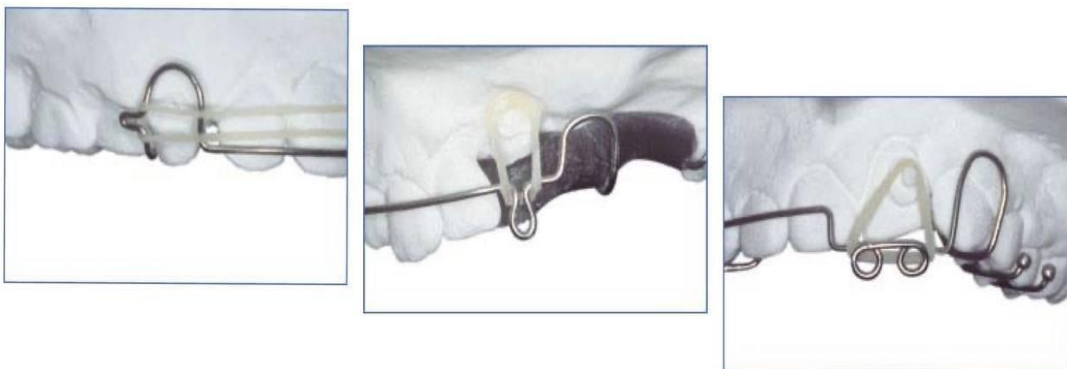Activations may be done either once or twice a week or more frequently, depending on the type and amount of OTM required. Ideal OTM is achieved by turning the screw a quarter turn every 3-7 days. Most screws produce 0.2-0.25mm movement per quarter turn. The movement produced is a direct function of the thread height.

Based on the location of the screw and the acrylic split, three types of OTMs can be brought about by screw appliances:

- a. Arch expansion: screw placed in the center of the arch.
- b. Labial/buccal movement of one or a group of teeth.
- c. Mesial/distal movement of one or more teeth.

## Elastics

Special intra-oral elastics are manufactured for orthodontic use. These elastics are usually classified by their size, ranging from  $\frac{1}{8}$  inch to  $\frac{3}{4}$  inch, and the force that they are designed to deliver, usually 2, 3.5, or 4.5 ounces. Selection of the appropriate size and force is based upon the root surface area of the teeth to be moved and the distance over which the elastic is to be stretched. The elastics should be changed every day. Elastics are routinely used in conjunction with fixed appliances but can provide the force component in ROA in suitable circumstances such as it used for retraction of anterior teeth.

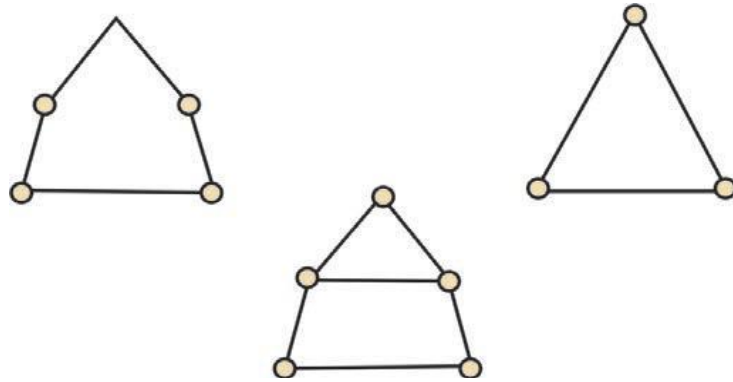


**A key for screw activation used in ROA. The key turned for activation.**

## **2. Retentive components:**

These components help to retain the appliance in place and resist displacement due to active components. Good retention will help patient compliance, anchorage and OTM. Tammoscheit (1969) described three types of anchorage systems for active removable plates. His description was based on geometric designs, depending upon the placement of the retentive units.





Schematic representation of intramaxillary anchorage in active plates:  
 (1) trapezoidal anchorage, (2) triangular anchorage, (3) triangular-trapezoidal (ideal) anchorage.

Retentive components are a very important part of a ROA for the following reasons:

1. Active forces from bows, springs, screws and elastics can displace the appliance and make it ill fitting.
2. A loose-fitting appliance is uncomfortable and if it is continually moving in the mouth, it can lead to metal fatigue and failure.
3. Because of the above reasons, patient compliance will be poor and necessary OTMs will not take place.

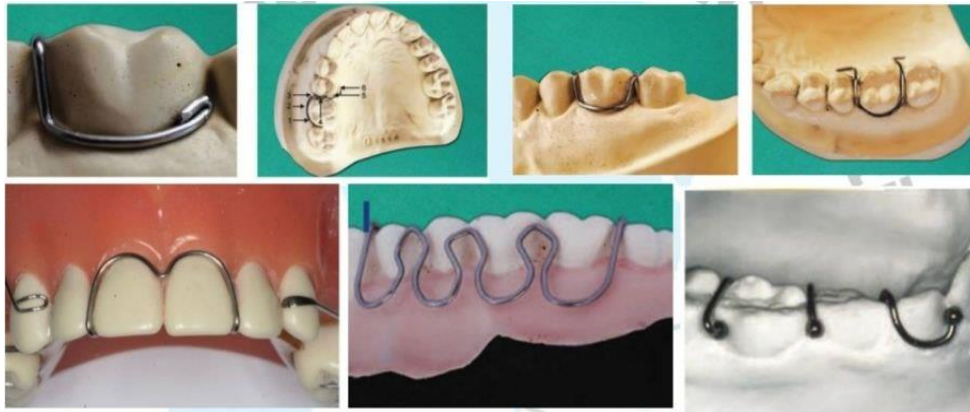
Adequate retention in a ROA is aided by wire components, which are known as clasps. They hold the teeth in such a manner so as to resist the displacement of the appliance.

□ **Requirements of an ideal clasp:**

1. Easy to fabricate.
2. Provide adequate retention.
3. No interference with occlusion.
4. Should not apply active force.
5. Able to use on both fully and partially erupted teeth.
6. No impingement on soft tissues.

Different types of clasps used includes Circumferential / C-clasp, Jacksons / Full Clasp, Schwarz Clasp, Southend clasp and most

commonly used clasp is Adams' Clasp.



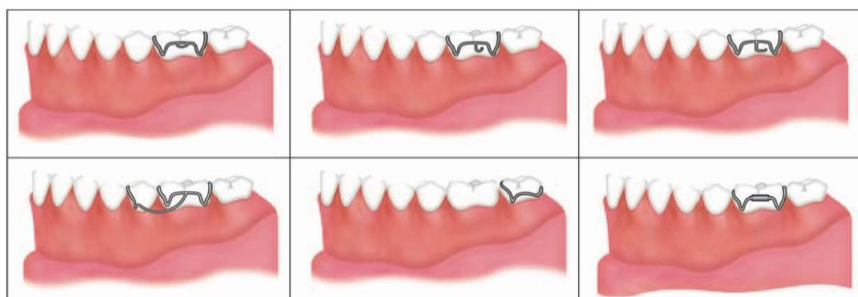
**Different types of clasps used includes Circumferential / C-clasp, Jacksons / Full Clasp, Schwarz Clasp, Southend clasp and most commonly used clasp is Adams' Clasp.**

### **Adams clasp**

It was designed to engage the undercuts present on a fully erupted first permanent molar at the junctions of the mesial and distal surfaces with the buccal aspect of the tooth. It is usually fabricated in hard 0.7mm stainless steel wire and should engage about 1 mm of undercut.

It can also be used for retention on premolars, canines, central incisors, and deciduous molars. However, it is advisable to use 0.6mm wire for these teeth. The reason for the popularity of the Adams clasp is its versatility as it can be easily adapted.

- Extra-oral traction tubes, labial bows, or buccal springs can be soldered onto the bridge of the clasp.
- Hooks or coils can be fabricated in the bridge of the clasp during construction.
- Double clasps can be constructed which straddle two teeth.



The Adams' clasp has a lot of advantages over other clasps, which are:

1. It is simple, strong and easily constructed.
2. It offers excellent retention.
3. It can be used on any tooth be it incisor, premolars or molars.
4. It is neat and unobtrusive and it makes an appliance easy to insert and remove using the bridges of the clasp.
5. Good patient compliance as it is comfortable to wear and resistant to breakage.
6. It can be used on both deciduous and permanent teeth.
7. A number of modifications enable its use in a wide variety of appliances.
8. No special instrument is required for its fabrication.

Other types of clasps are ball-ended clasps are designed to engage the undercut interproximally. This design affords minimal retention and can have the effect of prising the teeth apart.

On the other hand, different methods for anterior retention including Labial bows (like Hawley arch), fitted labial arch and Southend clasp are used. The latter is designed to utilize the undercut beneath the contact point between two incisors. It is usually fabricated in 0.7mm hard stainless steel wire. All are useful for anterior retention.

### **3. Baseplate (BP):**

The individual components of a ROA are connected by means of an acrylic BP, which can be a passive or active component of the appliance.

1. It acts a support for pressure sources and distributes the reaction of these forces to the anchorage areas.
2. It is fabricated either from self-cure or heat-cure acrylic.
3. It should be of minimum thickness to be comfortable to the patient. A single thickness of wax (1.5-2 mm) is sufficient in upper BP. If it is thick,

it will fill up the mouth, interferes with speech and will not be tolerated by the patient.

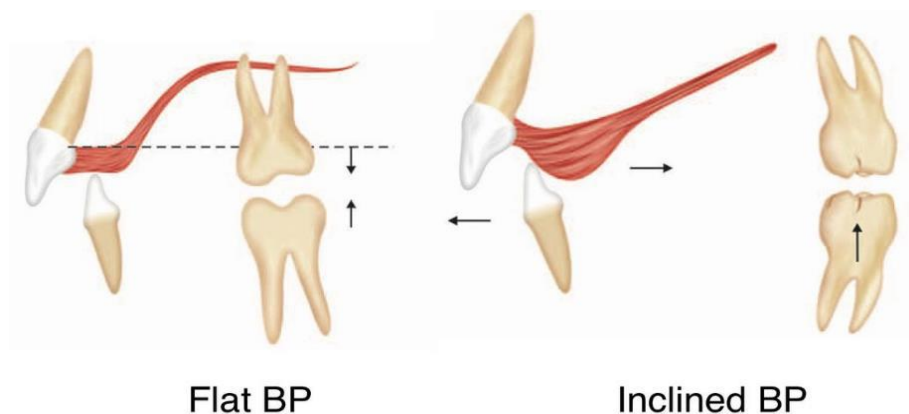
4. In maxillary arch, it extends till the distal of the first molar and slightly cutting it forward in the midline. This ensures adequate strength and gains maximum anchorage at the same time. While, lower BP is not extended too deep to avoid irritation to the sulcus and displacement by the tongue.

### **Modification of BP**

#### **□ Anterior bite-plane**

Increasing the thickness of acrylic behind the upper incisors forms a bite-plane onto which the lower incisors occlude. It should open the bite of molars no more than 1-2mm. It is prescribed when either the overbite needs to be reduced by eruption of the lower buccal segment teeth or elimination of possible occlusal interferences is necessary to allow OTM to occur.

They are usually flat. Inclined bite-planes may lead to proclination or retroclination of the lower incisors, depending upon their angulation.



### **Modifications of base plate. Flat and Inclined bite-planes.**

#### **Posterior bite-plane (Buccal capping)**

It is prescribed when occlusal interferences need to be eliminated to allow OTM in anterior segment to be accomplished and reduction of the overbite is undesirable. It is produced by adding the acrylic over the

occlusal surface of the buccal segment teeth and has the effect of propping the incisors apart. The acrylic should be as thin as practicably possible to aid patient tolerance.

### **Delivery of a removable appliance**

At the time of appliance delivery, the following should be checked:

1. Prior to placing, any minute pimples due to blow holes in the cast could irritate the mucosa and the free edges should be rounded and smooth.
2. Trimming base plate may be needed while fitting ROA in the mouth.
3. Post-insertion, check for the position of the active and retentive components.
4. The patient should be called for a recall visit every 2-3 weeks.

### **Instructions to the patient**

The success of any ROA is certain if the patient follows the instructions carefully.

1. Show in a mirror the insertion and removal of the appliance. Insist that the appliance be maneuvered by the bridges of the clasp only.
2. Wear the appliance for 24 hours a day and to remove it only while brushing and eating.
3. A high standard of oral hygiene should be insisted upon to avoid the possibility of enamel decalcification. Clean ROA by brushing it with soap and water.
4. In case of pain or appliance damage, patient must be told to report immediately to the clinic.

### **Common problems during treatment**

#### **1. Slow rate of OTM**

Normally, OTM should proceed at approximately 1 mm per month in children, and slightly less in adults. If progress is slow, check the following:

- Is the patient wearing the appliance full-time?
- If the active element is a spring—is this correctly positioned and optimally activated?
- If the active element is a screw—is the patient adjusting this correctly, at the frequency requested?
- Is OTM obstructed by the acrylic or wires of the appliance? If this is the case, these should be removed or adjusted.
- Is OTM prevented by occlusion with the opposing arch?

## **2. Frequent breakage of the appliance**

The main reasons are:

- The appliance is not being worn full-time.
- The patient has a habit of clicking the appliance in and out and it rapidly becomes loose.
- The patient is eating inappropriate foods while wearing the appliance.

## **3. Anchorage loss**

This can be increased by the following:

- Part-time appliance wear, thus allowing the anchor teeth to drift forwards.
- The forces being applied by the active elements exceed the anchorage resistance of the appliance. Care is required to ensure that any springs are not being overactivated.

## **4. Palatal inflammation**

This can occur for two reasons:

1. Poor oral hygiene.
2. Entrapment of the gingivae between the acrylic and the tooth/teeth being moved.

*My great wishes for my lovely students for success. Thanks*



# Orthodontics

## *Fixed orthodontic Appliances*

They are devices which have attachments that are fixed onto the tooth surface, and forces are exerted via these attachments using archwires and /or other auxiliaries. The appliances cannot and should not be adjusted or removed by the patient.

### **ADVANTAGES OF FIXED ORTHODONTIC APPLIANCES**

1. Precise tooth control is possible.
2. Multiple tooth movements are possible.
3. Patient cooperation is reduced in comparison to removable appliance
4. All types of tooth movements are possible.

### **DISADVANTAGES OF FIXED ORTHODONTIC APPLIANCES**

1. Oral hygiene requirement.
2. Esthetics.
3. Special training for operator.
4. Increased cost of treatment.
5. Increased chair side time.
6. Anchorage control is more difficult.
7. The possibility of producing adverse tooth movement.

### **INDICATIONS FOR THE USE OF FIXED APPLIANCES**

1. Correction of mild to moderate skeletal discrepancies. As fixed appliances can be used to achieve bodily movement it is possible, within limits, to compensate for skeletal discrepancies and treat a greater range of malocclusions.
2. Intrusion/extrusion of teeth.

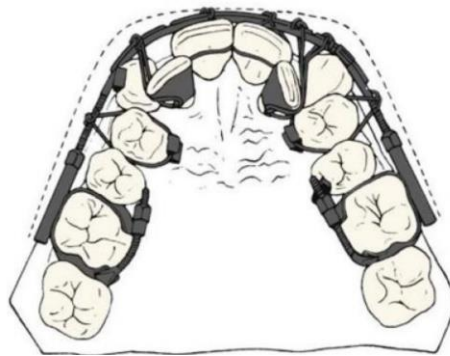3. Correction of rotations.
4. Overbite reduction by intrusion of incisors.
5. Multiple tooth movements required in one arch.
6. Active closure of extraction spaces, or spaces due to hypodontia

### **The development of contemporary Fixed Appliances**

Edward Angle's position as the “father of modern orthodontics” is based not only on his contributions to classification and diagnosis but also on his creativity in developing new orthodontic appliances.

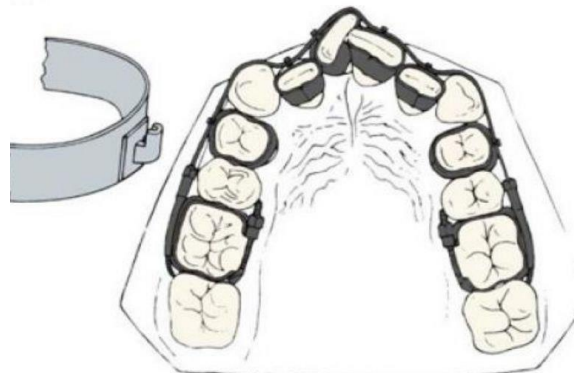
#### **E-Arch:**

Edward Angle's E-arch from the early 1900s. Ligatures from a heavy labial arch were used to bring malposed teeth to the line of occlusion.



#### **Ribbon Arch**

Angle's ribbon arch appliance, introduced about 1910, was well-adapted to bring teeth into alignment but was too flexible to allow precise positioning of roots. It was the first introduction of brackets. Used a gold wire of 10x20.



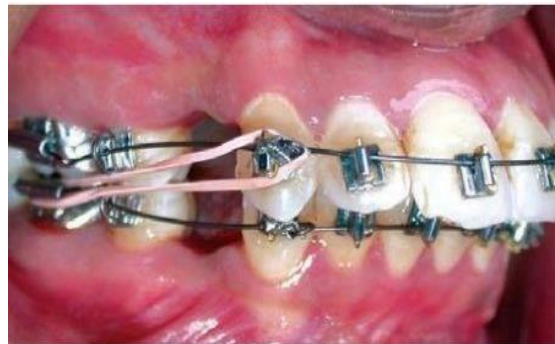## **Edgewise**

To overcome the deficiencies of the ribbon arch, Angle reoriented the slot from vertical to horizontal and inserted a rectangular wire rotated at 90 degrees to the orientation it had with the ribbon arch, thus the name “edgewise”



## **Begg Appliance**

The Begg appliance used a modification of the ribbon arch attachment, into which round archwires were pinned. A variety of auxiliary archwires were used in this system to obtain control of root position.



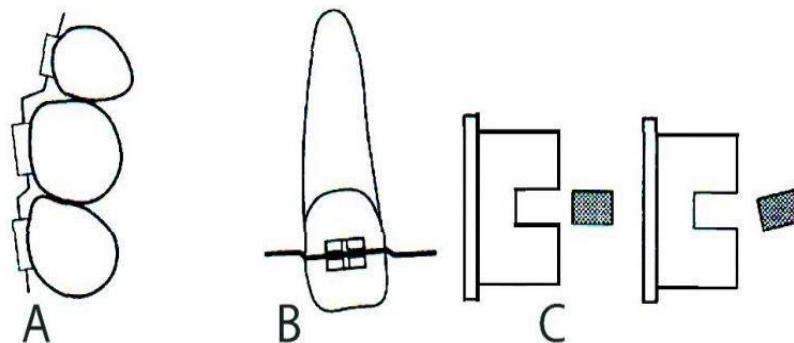
## **Contemporary Edgewise**

The Begg appliance became widely popular in the 1960s because it was more efficient than the edgewise appliance of that era, in the sense that equivalent results could be produced with less investment of the clinician's time. Developments since then have reversed the balance; the contemporary edgewise appliance has evolved far beyond the original design while retaining the basic principle of a rectangular wire in a rectangular slot, and now is more efficient than the Begg appliance,

which is the reason for its almost universal use now, known as:

### **Straight-Wire Appliance**

Angle used the same bracket on all teeth, as did the other appliance systems. In the 1980s, Andrews developed bracket modifications for specific teeth to eliminate the many repetitive bends (first, second and third order bends) in archwires that were necessary to compensate for differences in tooth anatomy, and bonding made it much easier to have different brackets for each tooth. The result was the “straight-wire” appliance. This was the key step in improving the efficiency of the edgewise appliance.

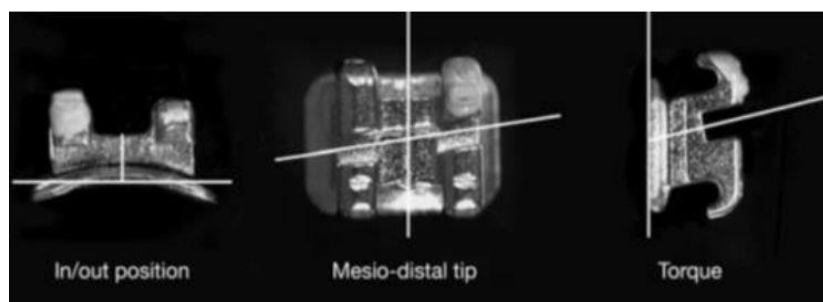


### **Basic bends with standard edgewise appliance**

**A: First order bends:** made in the horizontal direction, and are required to make the wire conform anatomically to the labial & buccal contours of teeth.

**B: Second order bends:** made in the vertical plane, used for uprighting teeth and paralleling of the roots.

**C: Third order bends:** made for torque.



### **Features of the brackets of straight wire appliance:**

- Variable distance from base of slot to base of bracket for correct in/out position.
- Pre-angulated slots for correct mesiodistal tooth angulation or tip;
- Bracket bases inclined for correct inclination or torque

### **Components of Fixed orthodontic Appliance:**

they can be broadly classified into:

#### ***I. Attachments***

#### ***II. Archwire.***

#### ***III. Auxiliaries.***

### **I- Attachments:**

These include:

A. Bands

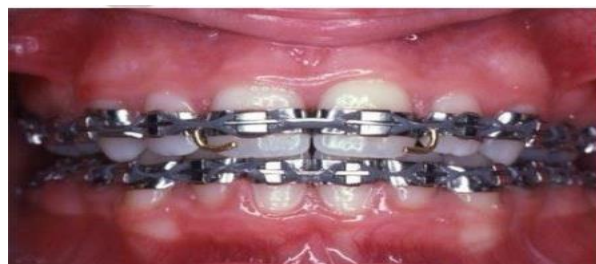B. Brackets.

C. Other attachments: Buccal tubes, Buttons, eyelet, sheath, cleat, ....etc.

The attachments may be welded to bands, or directly placed on the tooth surface.

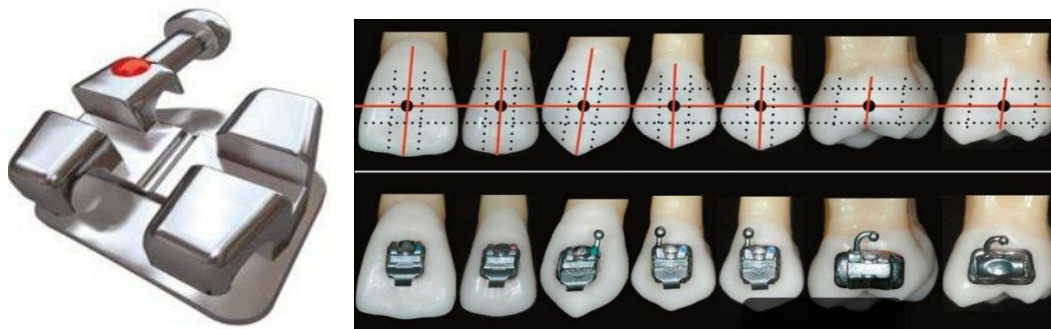
#### **A. Bands:**

These are rings encircling the tooth to which buccal, and as required, lingual attachments are soldered or welded. Until the 1980s, the only practical way to place a fixed attachment was to put it on a band that could be cemented to a tooth.



## B. Brackets:

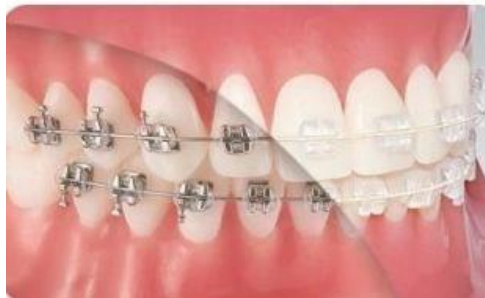Each bracket is made up of a bracket base, stem with bracket slot, tie wings to retain the ligature as it secures the arch wire into the slot, and some form of hook used for intramaxillary or intermaxillary attachment of elastics or coils.



There are many bracket types, the basic ways to classify brackets are:

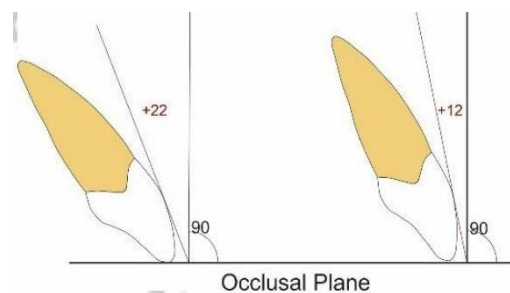
1- According to material:

- a. Metallic: e.g. Stainless-steel.
- b. Non-Metallic (Esthetic): Composite, Ceramic, Sapphire.



2- According to prescription (the amount of built-in tip and torque):

- a. Standard edgewise (zero tip and torque).
- b. Roth prescription
- c. McLaughlin, Bennett, & Trevisi (MBT) prescription, ....etc.





3- According to slot size:

- a. 18 mil (milli-inch) slot. (0.018 x 0.025 inch, where 0.018 is the width, and 0.025 is the slot depth)
- b. 22 mil slot (0.022 x 0.028 inch, where 0.022 is the width, and 0.028 is the slot depth)



4- According to ligation method

- a) Conventional ligation.
- b) Self-ligating brackets (which utilize a permanently installed, moveable component to entrap the arch wire).



**C. Other attachments:** including but not limited to:

- Buccal Tubes: Used on molars.
- Buttons: Small, mushroom-shaped orthodontic attachments that can be bonded directly onto a tooth or welded on a band. They are usually used on the palatal surface of the teeth (to provide a couple force), or on a partially erupted tooth.
- Eyelets: mostly on partially erupted teeth.



## II- Archwires:

The amount and type of force applied to an individual tooth can be controlled by varying the cross-sectional dimension and form of the archwire, and/ or the material of its construction.

In the initial stages of treatment, a wire which is flexible with good resistance to permanent deformation is desirable (e.g. Nickel-titanium archwires), so that displaced teeth can be aligned without the application of excessive forces.

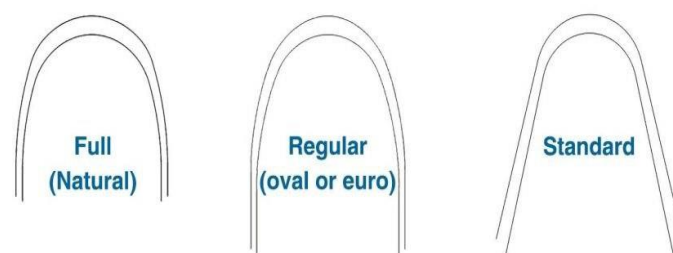
In contrast, in the later stages of treatment rigid arch wires are required to engage the archwire slot fully and to provide fine control over tooth position while resisting the unwanted effects of other forces, such as elastic traction (e.g. stainless-steel).

Archwires can be described according to their material, dimensions, and form.

**Material:** e.g. stainless-steel, Nickel titanium, Beta Titanium, Etc.

**Dimensions:** Usually archwire dimension is expressed in milli-inches (= 0.025 mm). A 16 milli-inch (0.016") is a round 0.4 mm wire, and a 16x22 is a rectangular 0.4x0.55 mm wire.

**Form:** It may be a full form, regular (or oval) form, or standard form.



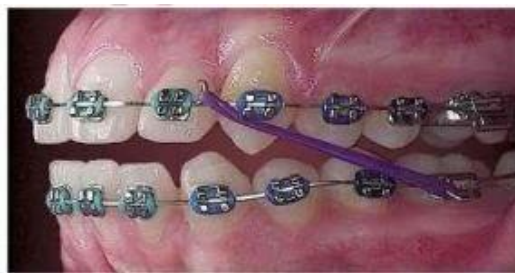
## III- Auxiliaries

There are many auxiliaries used with fixed orthodontic appliance, among them are:

**Ligatures:** these are used to secure the archwire into the bracket. They include elastomeric modules and ligature wires.

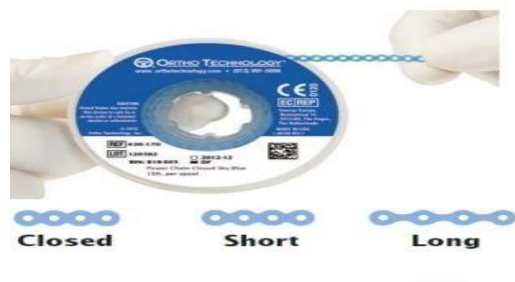

**Intra-oral elastics:** available in different sizes and strength to provide intra and interarch traction. For most purposes they must be changed daily. Class II and Class III elastics are ways to describe these elastics according to their use.



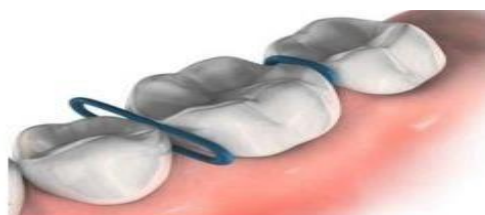
**Elastomeric modules (Elastomeric chain, or Power chain)**

A chain of connected elastomeric rings used as a force-producing mechanism for orthodontic tooth movement. Elastomeric chains can be long, short, or closed, depending on whether or not there is a distance between the rings at its passive state.



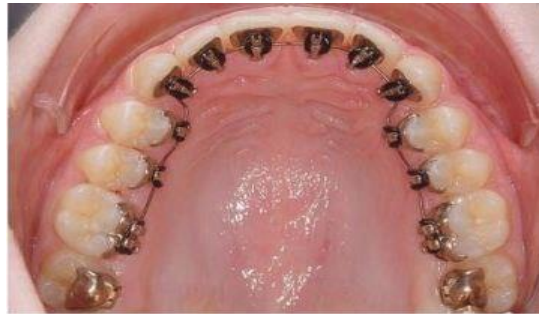**Separators (Elastic separator)**

Elastomeric rings of varying thickness that are placed around the interproximal contact point to create the necessary separation over time.



### **Lingual Appliances:**

These are secured to the lingual surfaces of the teeth. There are some problems associated with them including some pronunciations difficulties that occur after insertion, the technique is difficult and time consuming, and the working position is awkward.



### **Fixing attachments**

Attachments can be fixed to the teeth surfaces by either banding or bonding. The procedure of cementing a band to the tooth is called “banding”. The method of fixing attachment directly to enamel using resins is called bonding. It greatly enhances esthetics, and maintenance of oral hygiene as compared to banding.

### **Banding involves:**

- a. Separation of teeth.
- b. Selection of proper band size with close fit.
- c. Cementation of the band preferably using glass ionomer cement.

A number of indications still exist for use of a band rather than a bonded attachment, including:

- a. Teeth that will receive heavy intermittent forces against the attachments, e.g., an upper first molar against which extraoral force is placed via a headgear.
- b. Teeth that will need both buccal and lingual attachments such as a molar with both headgear tube and transpalatal bar.
- c. Teeth with short clinical crowns, so that bonded brackets are difficult

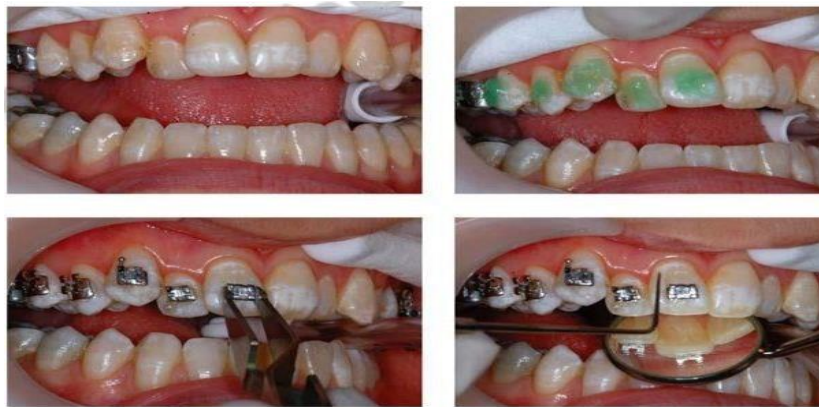to place correctly.

d. Teeth with extensive restorations.

Bonding may be made directly in the office, or indirectly through a lab.

**Direct bonding involves:**

- Cleaning the tooth surface, to remove any pellicle using a slow hand piece and prophy brush or cup;
- Acid-etching the enamel surface using 35-37% phosphoric acid for 15–30 seconds;
- Washing and drying the tooth surface;
- Placing unfilled primer on the etched area of the tooth



**Direct Bonding**

Placing composite resin on the bracket base;

- Positioning the bracket on the tooth crown;
- Cleaning up excess composite from around the bracket base; and
- Curing the composite, either chemically or with a blue light source.

It is very important to clean up excess composite or ‘flash’ as this can create problems in maintaining high levels of oral hygiene and result in demineralization around the bracket, a major risk of fixed appliance therapy.

In indirect bonding, the brackets are glued with a temporary material to the teeth on the patient’s models, transferred to the mouth with some sort of tray into which the brackets become incorporated, and then

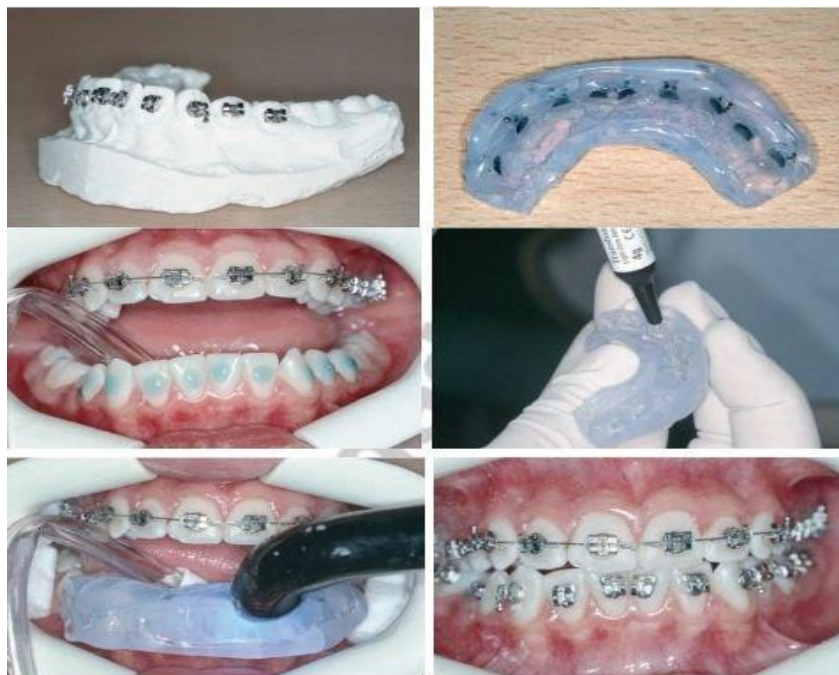bonded simultaneously with adhesives.

**The main advantages of indirect compared to direct bonding are:**

- a. The brackets can be positioned more accurately in the laboratory.
- b. The clinical chair time is decreased.

However, the method is:

1. Technique-sensitive.
2. The procedure requires greater experience.
3. Removal of excess adhesive can be more difficult and more time consuming with some techniques.
4. The risk for adhesive deficiencies under the brackets is greater.
5. The risk for adhesive leakage to interproximal gingival areas can disturb oral hygiene procedures.
6. The failure rates with some methods seem to be slightly higher

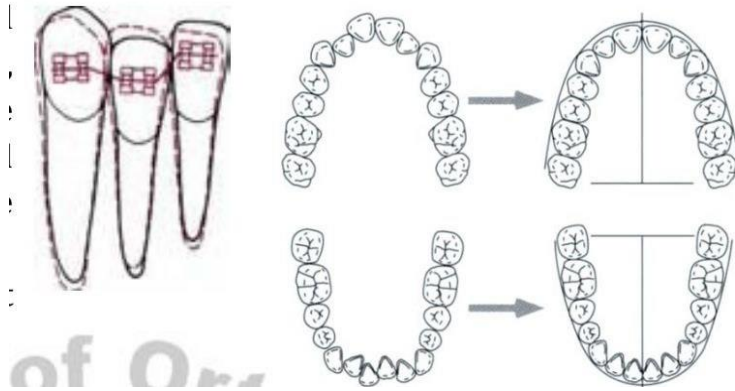


**Indirect Bonding**

**The comprehensive orthodontic treatment with fixed appliance**

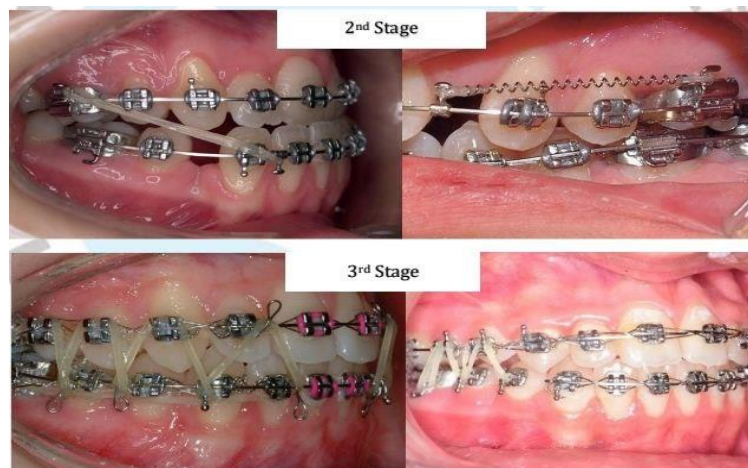**1st stage:** Alignment and leveling: Eliminating rotations, bringing the teeth to one line buccolingually and one level occlusogingivally following the archwire shape. It facilitates future treatment stages.





**2nd stage:** Correction of molar relationship and space closure (e.g. extraction space).

**3rd stage:** Finishing (settling): optimizing occlusal relationship between upper and lower dental arches.



### **Visit frequency**

Following insertion, the patient must be seen regularly to evaluate the progress of treatment and make the necessary adjustments. There is no agreement or evidence to support a specific timeframe. Most orthodontists see their patients every 4 weeks, others see them every 6, 8, or 10 weeks intervals.

These visits are also necessary to avoid or prevent problems during orthodontic treatment. The problems encountered are caries and decalcification, debonded brackets, loose bands and soft tissue problems.

### **Treatment duration**

There is no specific way to estimate duration of treatment. It usually takes

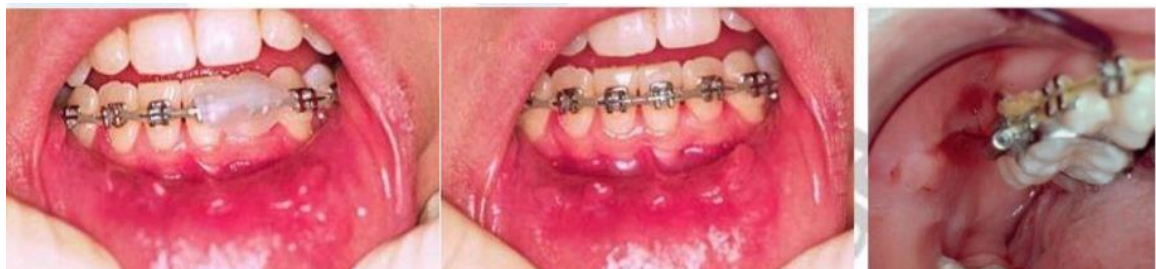12-30 months, depending on the complexity of the case. Missing appointments will lengthen treatment duration.

### **Pain with fixed orthodontic appliances**

Some pain may be felt in the teeth for a period of 3-5 days following each adjustment visit, especially during eating. The pain level is usually mild to moderate. Analgesics like ibuprofen or paracetamol may be used to decrease pain.

Some pain may be felt with salty or sour food because of ulcers. Ulcers often develop as a result of rubbing the cheeks and lips with the appliance during normal function. This usually lasts for few days after insertion, and can be reduced by using orthodontic wax.

Trauma to the cheek may happen because of a protruding wire; it is better to go to the orthodontist to fix it, meanwhile orthodontic wax can be used to reduce irritation.



### **Instructions for patients wearing a fixed appliance:**

#### *1- Teeth cleaning:*

**A.** It is necessary to clean the teeth with a toothbrush using fluoridated toothpaste for three minutes immediately after each time you eat, and before going to bed. It is preferable to have a traveler brush with you all the time to ensure cleaning the teeth after each time you eat.

**B.** You should clean all the surfaces of the teeth thoroughly including the area between the teeth and brackets.

**C.** Cleaning the teeth with a fixed orthodontic appliance in place is more difficult and takes more time than without an appliance

**D.** Fluoridated alcohol-free mouthwash should be used at least once daily after toothbrushing. You should avoid eating or rinsing your mouth for at least 20 minutes after using the mouthwash.

**E.** Having snacks and drinks with a high sugar content without proper cleaning of your teeth will result in permanent damage to the teeth.

*2- Food:*

**A.** Avoid snacks and drinks with a high sugar content between meals and at bedtime.

**B.** Avoid sticky food, especially sweets and chewing gum, as they will stick to the teeth and the appliance, this will increase the accumulation of bacterial plaque around orthodontic brackets, leading to decay

**C.** Avoid hard food like nuts as it can damage the appliance, and requiring repair. Fruits and vegetables that are relatively hard, like apples or carrots should be cut into small pieces.

**D.** Avoid fizzy drinks and consuming large quantities of fruit juice.

**E.** Since it will be necessary to use a tooth brush after eating, most patients find it best to avoid snacks between main meals.

*3- Appliance breakage:*

**A.** In case of appliance breakage, you should contact your orthodontist immediately to schedule an emergency appointment. You should not wait for your regular appointment, as this may result in unfavorable tooth movement, or further damage to the appliance which will eventually increase treatment duration.

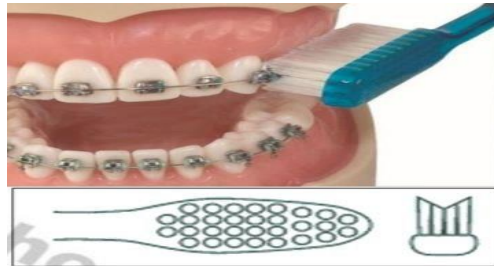
**B.** Repeated breakages of an appliance because of poor care may result in stopping treatment.

**C.** You should wear a protective shield while practicing contact sports, according to your orthodontist's instruction.

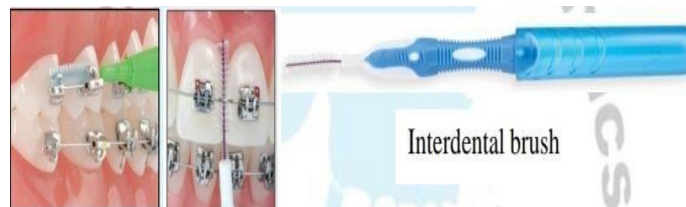*4- Maintain regular visits and follow your orthodontist's instructions.*

**Oral Hygiene measures for patients with fixed orthodontic appliance:**

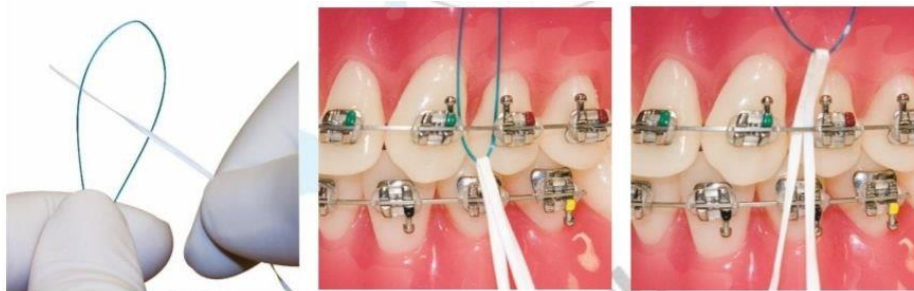- Tooth brushing: preferably using a V trim tooth brush to clean the appliance, and a regular brush to clean the occlusal and lingual/palatal surfaces of the teeth.



- Using interdental brush for interproximal and detailed cleaning.

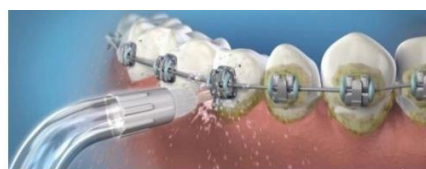

- Flossing: The floss is passed between the archwire and the teeth using a floss threader. A superfloss may also be used without the need for a floss threader. Alternatively, a water flosser may be used.



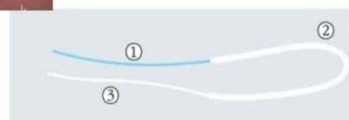Using a floss and a floss threader to clean between the teeth.

- Mouth rinses: Fluoridated mouth rinses are usually used.



Water jet may also be used to clean the teeth

Superfloss parts: 1) plastic threader, 2) spongy part, 3) soft nylon floss.



*My great wishes for my lovely students for success. Thanks*

# Orthodontics

## *Fixed orthodontic Appliances*

### **Risks of orthodontic treatment**

Orthodontic treatment is not without risk. These include:

#### **1- Enamel demineralization**

The incidence of demineralization during fixed appliance therapy is high and can result in the development of enamel opacities on the labial surfaces of the teeth. The main etiological factors are poor oral hygiene and a diet high in refined sugars. In combination and over the long-term, these factors will inevitably result in demineralization and permanent marking of the teeth.

#### **2- Enamel fracture and abrasion**

The removal of a fixed appliance bonded to enamel carries a small risk of fracture at the enamel–dentinal junction if the bracket bond strengths are too high. In reality, bond strengths used are considerably lower than this, and at debond failure usually occurs at the bracket base–adhesive junction. An exception to this proved to be some early ceramic bracket systems; manufacturers were concerned with failure of the bracket bond during treatment and enhanced the mechanical bonding chemically. This resulted in excessive bond strengths and a significant risk of enamel fracture on debonding. Modern ceramic bracket bases are designed with features that facilitate easier debonding, which reduces the risk of enamel fracture. Attrition of teeth occluding against ceramic brackets is the most important disadvantage of the ceramic brackets. The clinician must avoid bracket contact with opposing teeth.

### **3- Root resorption**

External apical root resorption (EARR) is an almost universal finding following orthodontic treatment, but this is usually not clinically significant and has no influence on long-term health of the teeth. Severe root resorption, when more than one-third of the root length is lost, has been reported to occur in between 1% and 5% of orthodontically treated teeth.

### **4-Damage to the pulp**

The use of excessive force or pushing the apex of teeth through the cortical plate can result in a loss of vitality. Teeth with a history of trauma are more susceptible to vitality loss during treatment, but in most cases, there is no obvious cause. Fortunately, loss of vitality is a rare complication of orthodontics.

### **5- Gingivitis**

Gingival irritation is inevitable with the use of fixed appliances, especially when bands are used, and this is exacerbated by poor oral hygiene that can result in gingival hyperplasia. Gingival health improves significantly following the removal of appliances, with a reduction in probing depths mainly due to shrinkage of hyperplastic tissues.

### **6- Alveolar bone loss**

A small loss of alveolar bone height following orthodontic treatment has been reported in relation to teeth adjacent to extraction sites, but there appears to be no long-term effect on periodontal health from orthodontic treatment. An exception to this is orthodontic treatment in patients with active periodontal disease because this can rapidly increase bone loss. Periodontal disease should be treated, stable and well maintained in these patients prior to commencing orthodontic treatment. Orthodontic treatment can also result in recession when teeth are moved excessively in a labial or buccal direction during treatment, resulting in a bony



dehiscence and gingival recession.

### **7- Oral ulceration**

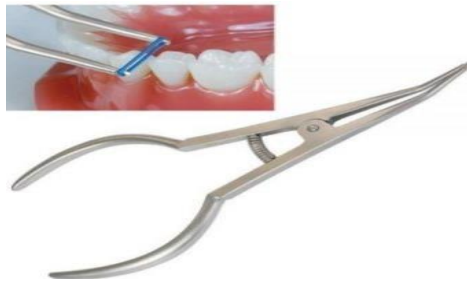Traumatic ulceration in susceptible individuals is common particularly during the early stages of treatment.

### **8- Allergic reaction**

Orthodontic wires and brackets contain nickel and patients allergic to nickel could have non-specific intraoral signs including erythematous areas and severe gingivitis despite good oral hygiene.

### **Instruments commonly used with fixed orthodontic appliance**

**Separating pliers**: used for the placement of elastic separators.



### **Bracket holding tweezers or bracket positioning**

tweezer is used in orthodontics, for holding and positioning the brackets.



**Mathieu Hemostat** a multipurpose instrument used to place elastic and steel ligatures on orthodontic brackets.



**Howe pliers** is a utility pliers which has serrated tips for gripping wires.

It is useful for placement and removal of archwires as well as placement of pins and other auxiliaries



**Cutters:** there are hard and ligature wire cutters



**Distal end cutter:** it cuts and holds the wire distally to the buccal tube or bracket



**Height gauge** it is used to check the height of bracket placement from the incisal edge.



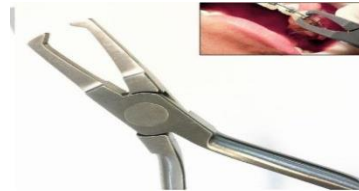**Band seater** is used to place and adjust orthodontic band



**Band removing pliers:** As the name implies, it helps removing bands



**Bracket debonding pliers:** may be straight or angulated, used to remove bonded brackets.



### **Anchorage**

The movement of teeth occurs through the application of forces. In order to make a change in tooth position, adequate support (“anchorage”) must be available from which to apply these forces. This support can be derived from multiple structures including teeth.



These forces act reciprocally on the teeth that are intended for movement and upon those structures used for support. According to Newton’s third law, which states that for every action there is an equal and opposite reaction, remains the basis of all orthodontic tooth movement.

If the supporting structures were teeth, then there may be unintentional or adverse changes in anchorage support.

**Definition:** It is the site of delivery from which a force is exerted.

Others defined it as the resistance to reaction forces that is provided usually by other teeth, occasionally by the palate, sometimes by the head or neck, and by anchors screwed to the jaws.

## **Classification of anchorage**

For understanding anchorage, it is convenient to divide anchorage into intraoral and extraoral anchorage. Further, intraoral anchorage can be subdivided into intramaxillary and intermaxillary anchorage. Both can be of three types-simple, stationary or reciprocal.

1. Anchorage classified according to the site where the anchorage units as:

- a. Intraoral
- b. Extraoral

2. Anchorage classified according to the jaws involved as:

- a. Intramaxillary
- b. Intermaxillary.

3. Anchorage classified according to the manner of force application as:

- a. Simple
- b. Stationary
- c. Reciprocal.

4. Anchorage classified according to space requirements:

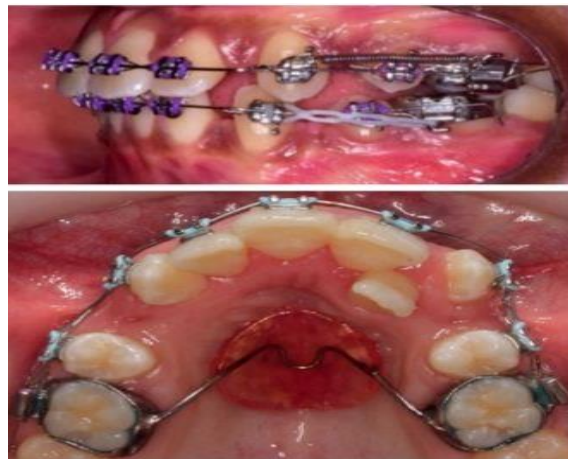
- a. Maximum (Type A).
- b. Moderate (Type B).
- c. Minimum (Type C).

## **Intraoral anchorage**

This type of anchorage is said to exist when and only when all the anchorage units are present within the oral cavity. Anchorage from all the intraoral sources of anchorage including the teeth, palate, etc. can form part of this type of anchorage. Mucosa and bone—the palatal vault can be used as a source of anchorage via the acrylic base plate of removable appliance or acrylic button attached to palatal arches.

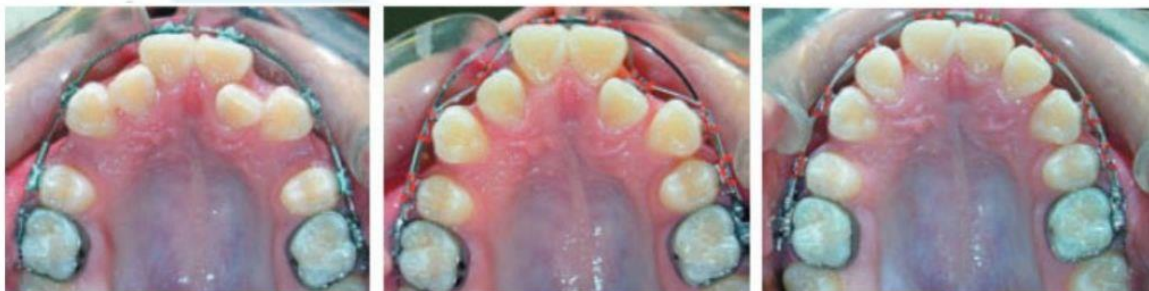Intraoral anchorage can be further divided into intramaxillary or intermaxillary anchorage depending upon the location of anchorage-

providing elements between the two jaws.



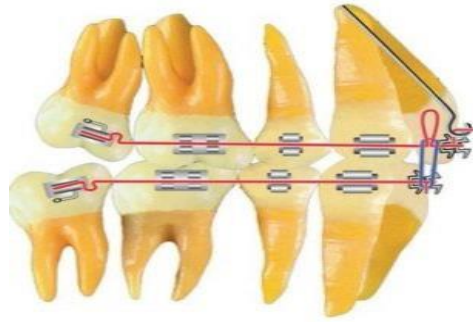
### **Simple anchorage**

It is said to exist when the manner and application of force is such that it tends to change the axial inclination of the tooth or teeth that form the anchorage unit in the plane of space in which the force is being applied. Thus, resistance to tipping of the anchorage units might be utilized to retract certain other teeth, which is better obtained by engaging a greater number of teeth than are to be moved. The root surface area of the anchorage units should be at least double that of the units to be moved. e.g., the movement of a single tooth using a screw appliance.



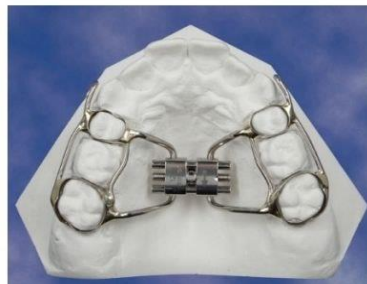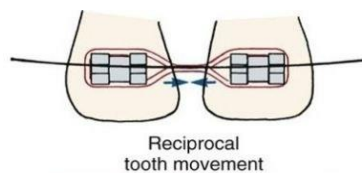
### **STATIONARY ANCHORAGE**

Stationary anchorage is said to exist when the application of force tends to displace the anchorage units bodily in the plane of space in which the force is being applied. The anchorage potential of teeth being moved bodily is considerably greater as compared to teeth being tipped.



## **RECIPROCAL ANCHORAGE**

Reciprocal anchorage is said to exist when two teeth or two sets of teeth move to an equal extent in an opposite direction. Here the root surface area of the so-called anchorage units is equal to that of the teeth to be moved. The effect of the forces exerted is equal, i.e. the two sets of teeth are displaced in the opposing direction but by the same amount. e.g., arch expansion using a midline screw, closure of median diastema.



### **Maximum anchorage (type A):**

Anchor unit should not move, or at least must not move more than  $\frac{1}{3}$  of the available space.

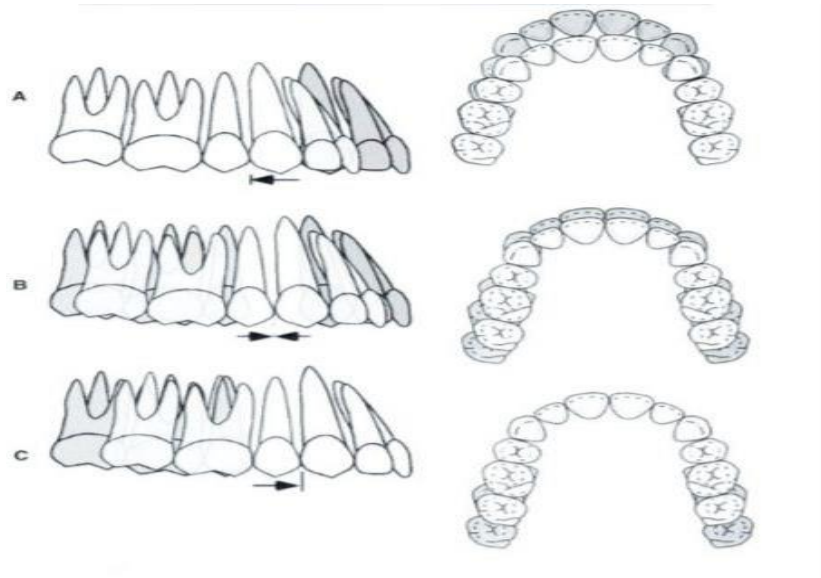
### **Moderate anchorage (type B):**

About  $\frac{1}{2}$  of the space available is utilized by movement of the anchor unit.

### **Minimum anchorage (type C):**

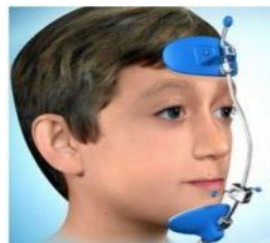The anchor unit should consume more than the majority or at least  $\frac{2}{3}$  of the space available.





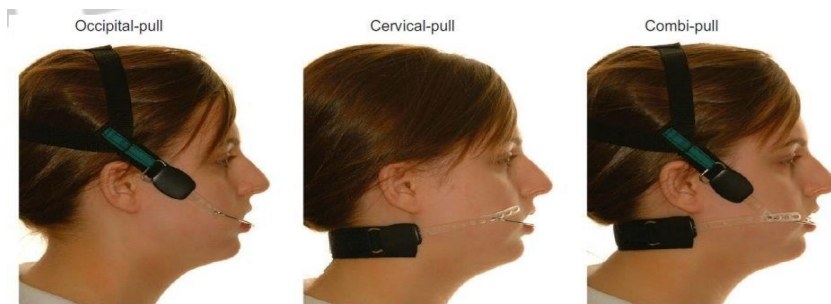
### Extraoral anchorage (EOA)

As the name implies, here the anchorage units are situated outside the oral cavity or extraorally. The extraoral structures most frequently used at the cervical region (as with the use of the cervical pull headgear, the occiput (as with the occipital pull headgear, the forehead and the chin (e.g. the face mask).



With the use of extraoral anchorage there is hardly any chance of any changes taking place in the anchorage units.

The biggest disadvantage of extraoral anchorage is the apparent lack of patient cooperation.



## ANCHORAGE PLANNING

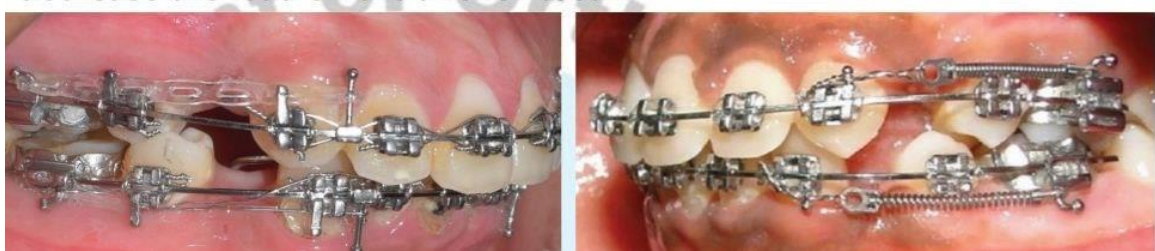It is very essential to carefully assess the anchorage demands of the individual case and select the most appropriate treatment plan. The anchorage

requirement depends on:

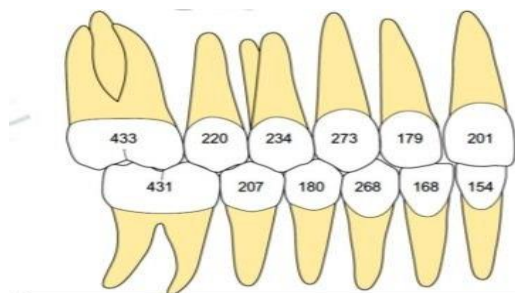
- a. The number of teeth to be moved the greater the number of teeth being moved the greater is the anchorage demand.




Moving teeth in segments as in retracting the canine separately rather than retracting the complete anterior segment together will decrease the load on the anchor teeth.



- b. The type of teeth to be moved: teeth with large flat roots and/or more than one root exert more load on the anchor teeth. Hence, it is more difficult to move a canine as compared to an incisor or a molar as compared to a premolar.



**Root surface area (mm<sup>2</sup>) of the permanent dentition, giving an indication of the relative anchorage value of each tooth**



- c. Type of tooth movement-moving teeth bodily requires more force as compared to tipping the same teeth.
- d. Periodontal condition-teeth with decreased bone support or periodontally compromised teeth are easier to move as compared to healthy teeth attached to a strong periodontium.
- e. Duration of tooth movement-prolonged treatment time places more strain on the anchor teeth. Short-term treatment might bring about a negligible amount of change in the anchor teeth whereas the same teeth might not be able to withstand the same forces adequately if the treatment becomes prolonged

### **Anchorage loss**

Tooth movement of the anchoring unit during orthodontic treatment is termed anchorage loss. It is undesirable in most instances.

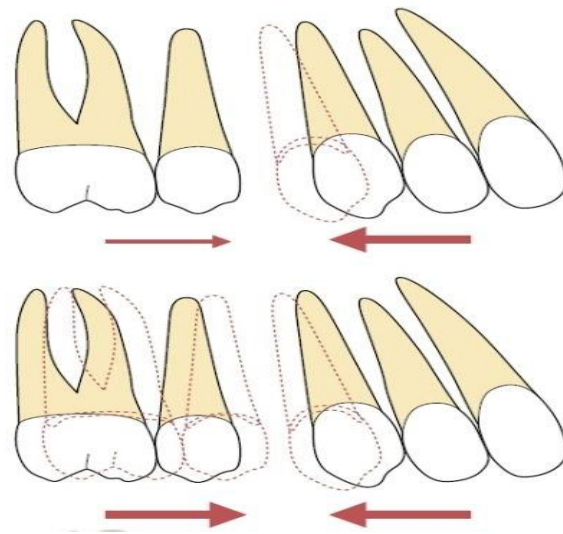
A common example is during overjet reduction, where teeth in the buccal segments move forward rather than those in the labial segments being retracted.

If severe, too much space is lost and a residual overjet results, this is called Mesial anchorage loss. There is vertical and transverse anchorage loss as well, depending on the direction of unwanted tooth movement. A number of factors can contribute to anchorage loss including:

#### **i. Heavy forces**

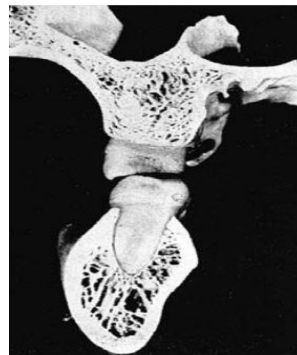Forces should be kept light to reduce anchorage loss. All orthodontic forces will produce some reciprocal force on the anchorage unit. If this is small, there will be minimal movement of these teeth. Forces should be light enough to exceed the threshold for tooth movement where planned but below the threshold for movement of the anchorage unit. With greater force, there is no increase in tooth movement. By increasing forces, there is no greater amount of tooth movement where it is wanted, greater force is applied to the teeth in the anchorage unit and they are more likely to

move.



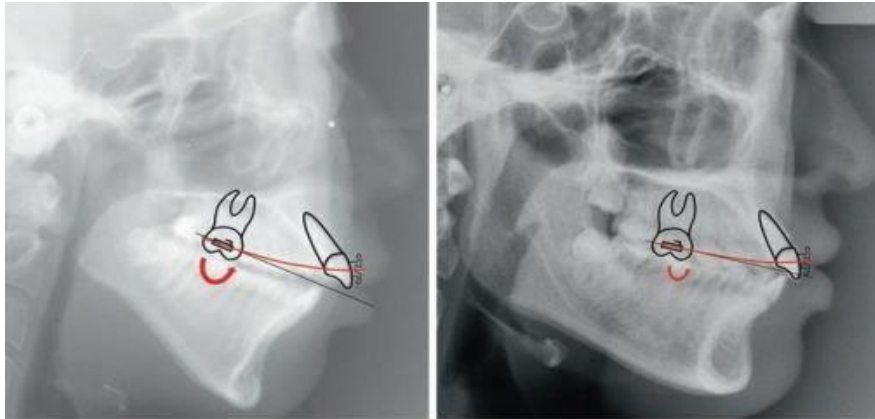
### **ii. Maxillary arch**

The maxillary arch is particularly susceptible to anchorage loss. This is probably due to a combination of factors, particularly the density of bone.



### **iii. Vertical growth pattern**

Anchorage loss and space closure occur more readily in patients with an increased vertical proportion. This is possibly due to lower bite forces and less occlusal interference that occurs in cases with a reduced overbite. In addition, more distally tipped molars would tip forward with the insertion of the straight wire appliance more likely than other skeletal patterns with a relatively upright molar.



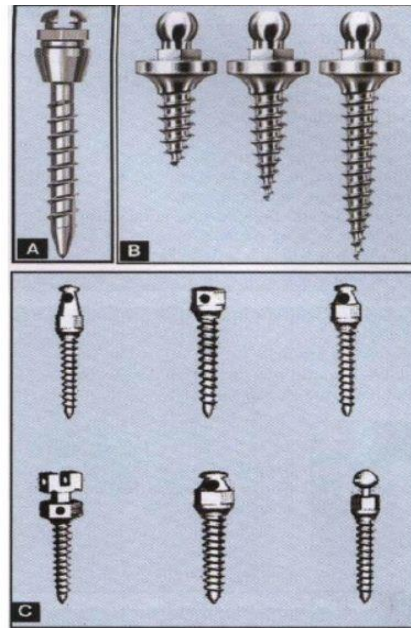
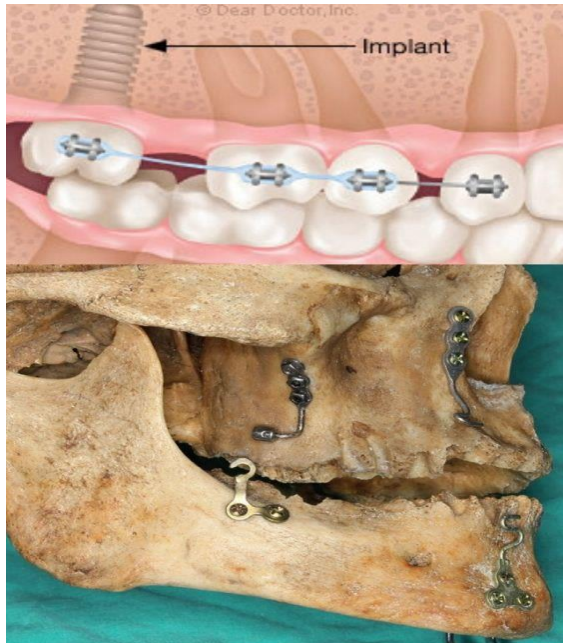
### **Skeletal/ Absolute anchorage**

Skeletal anchorage may be considered as an entity of its own or may be considered as a part of intraoral anchorage. It is described as absolute anchorage as there is no tooth movement except what was desired i.e., no unwanted tooth movement.

Although endosseous implants and miniplates have been used successfully for orthodontic anchorage and reinforcing anchorage in comparison with extraoral anchorage, their clinical applications are limited because of the comprehensive surgical procedures required and difficult removal after treatment which may make the patient uncooperative during treatment.

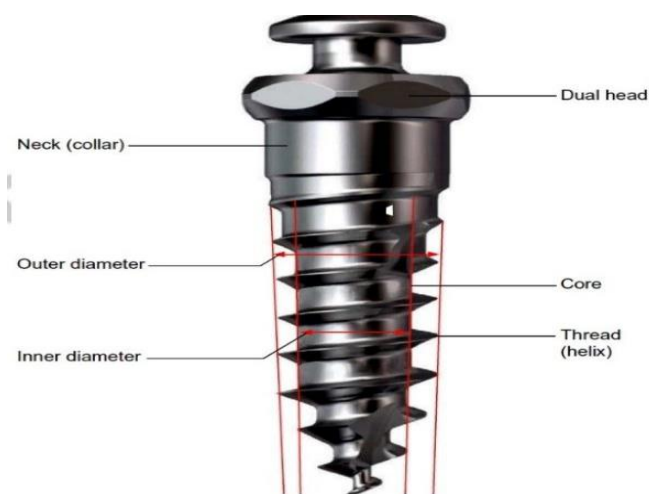
On the other hand, temporary anchorage devices (TADs) are simpler alternatives to endosseous implants. Their advantages include smaller size, simpler surgical placement, immediate loading without the need for lab work, easier removal after treatment, and lower cost.



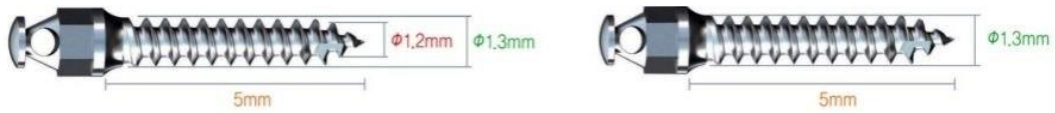

### Components of miniscrew

The commonly used screw has three parts: head, core, and thread (helix). Some manufacturers supply miniscrews with a longer neck for use in sites such as the palate or retromolar areas where the overlying gingiva is thicker. Most manufacturers give the outer diameter, which includes the width of the screw threads in the measurement. The diameter and thread length of the miniscrew are the main features to consider when selecting a miniscrew. Some miniscrews require drilling and they are referred to as predrilling miniscrews (cylindrical). Most of the current orthodontic miniscrews are drill-free or self-drilling type (tapered).







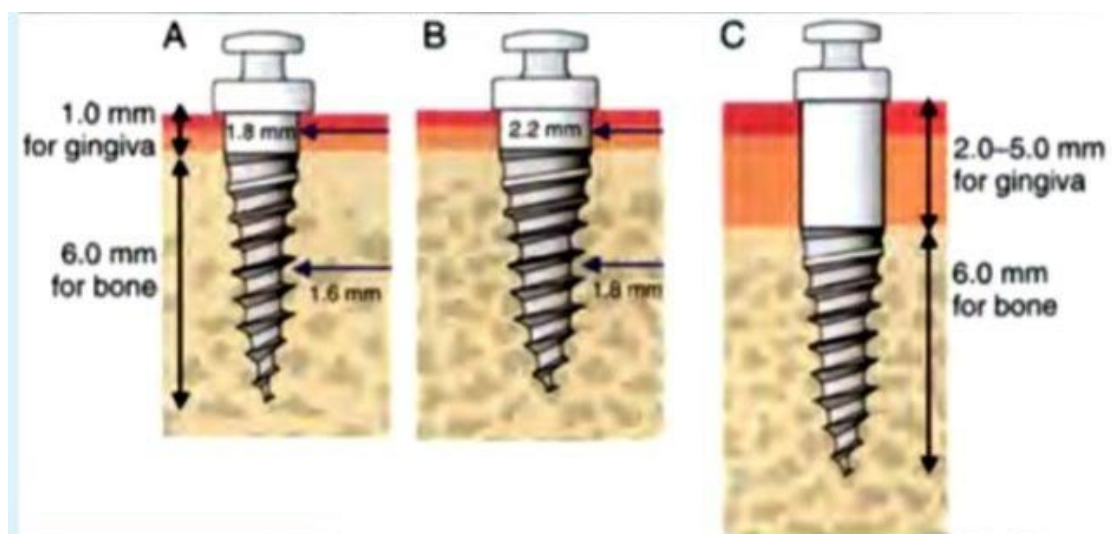
## Selection of miniscrews

### 1) Depending on the length;

The length of the screw portion is ranging from 5 mm to 12 mm. Longer miniscrews lead to better mechanical stability like dental prosthetic implants, but more possibilities of invading adjacent anatomical structures, such as roots, maxillary sinus, and nerve, etc. Usually, **6mm** of screw depth is enough for the maxilla, and 5mm is enough for the mandible. However, always we should consider the depth of soft tissue when choosing the proper length of miniscrews.

### 2) Depending on the diameter;

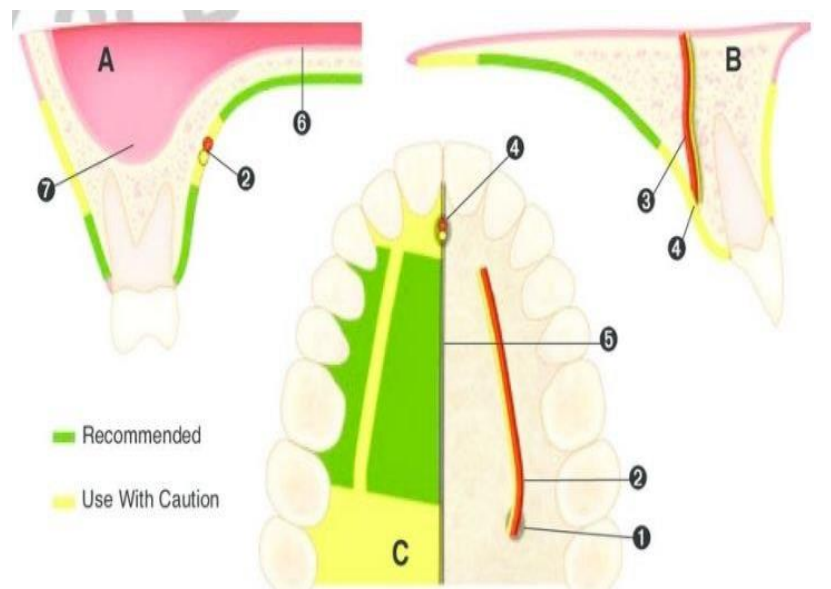
There are various diameters of miniscrews which range from 1.2 mm to 2.7 mm, so they can be placed anywhere in the mouth. The choice depends on the inter-radicular distance, quality of bone (the mandible is of better quality) and site of placement. Thicker the miniscrew, the greater becomes mechanical retention, but also the greater possibility for root contact.



## **Anatomic structures that need to be considered at the site of placement**

1. The roots of the teeth.
2. Nerves and blood vessels (ex. greater palatine neurovascular bundle)
3. The bone and sinuses in the vicinity of the intended site of placement are all vulnerable to perforation.

Particular care needs to be taken when considering placing implants in the buccal and lingual alveolar bone and the paramedian areas of the palate.

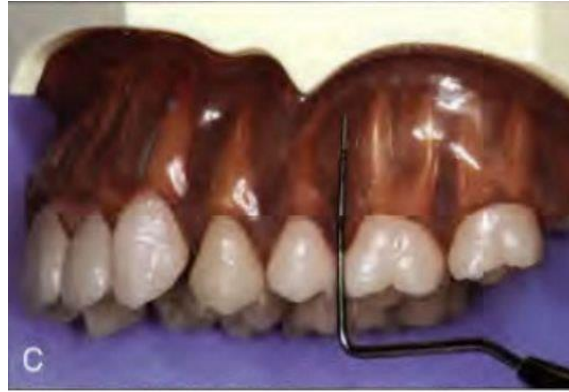

In contrast, there are no critical anatomic structures in the midpalatal region, the maxillary tuberosity and the retromolar pad area, except for the incisive canal in the palate.

## **General guidelines for placement**

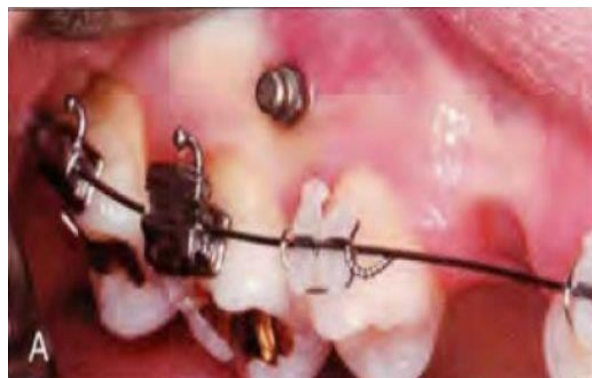### 1) Horizontal position:

Proper assessment of the interdental distance must be done both clinically and radiographically to avoid root damage.



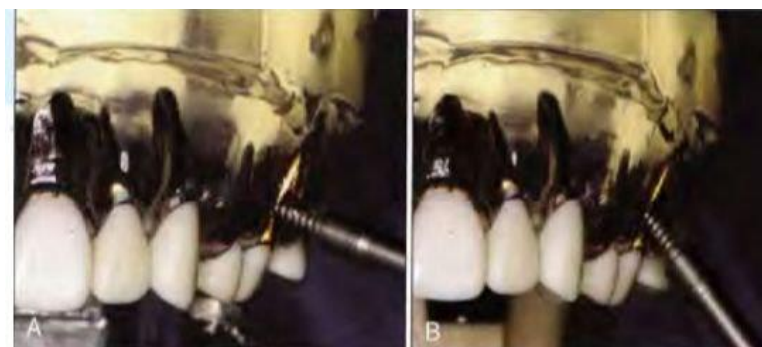
## 2) Vertical position:

A coronally placed miniscrew is likely to be on the firm attached gingiva, but the risk of root damage increases because of the conical shape of the roots. A compromised insertion point is therefore the mucogingival junction, where the clinician can minimize possible root damage while preventing soft tissue irritation.



## 3) Insertion Angle (Occlusogingival)

It is generally recommended to apically incline the insertion path to avoid possible root injuries and increase cortical bone support. A 45 degree angulation relative to the occlusal plane is considered acceptable.

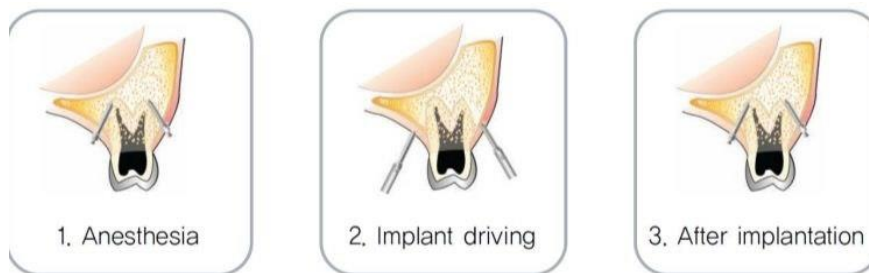

## Surgical procedures:

### A. Self-drilling:

a. One step:

- i. Anesthesia.
- ii. Driving of implant.

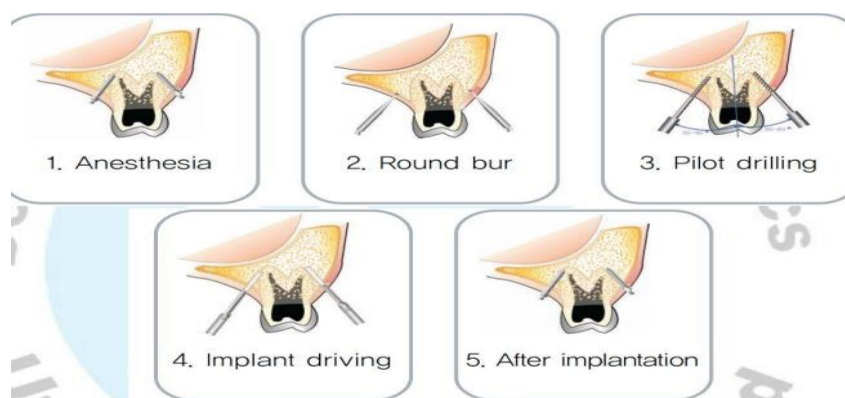


b. Two steps:

- i. Anesthesia.
- ii. Penetration with a round bur.
- iii. Driving of implant.

### B. Predrilling method:


- i. Anesthesia.
- ii. Penetration with a round bur.
- iii. Pilot drilling.
- iv. Driving of implant.



### Miniscrew driving

This is done either by engine driver or a hand driver. it is safer to use hand driver to feel resistance of miniscrew driving torque. We should never give excessive force, because if miniscrew is broken during

driving, it may be a little troublesome to remove



### **Explanation for the possibility of failure**

Miniscrews have a failure rate of up to 40% due to miniscrew-related factors, patient-related factors, and management-related factors. The patients should be fully noticed of the possibility of failure before starting miniscrew treatment.

### **Possible Complications:**

#### 1) Soft tissue inflammation, ulceration, abscess, and coverage

Inflammation or an abscess is relatively rare if the miniscrew is placed on the firm attached gingiva. Ulceration or soft tissue coverage is associated with miniscrews placed on or near the buccal frenum.

#### 2) Root damage

Usually with the predrilling method. Root damage can be managed depending on the severity of the injury. Serious injury, including root perforation or fracture, is extremely rare in the drill-free system. Minor injuries on the cementum area can undergo spontaneous healing after the removal of the miniscrew.

#### 3) Root contact during tooth movement

Adjacent tooth movement toward the miniscrew can result in miniscrew root contact. Root contact by the orthodontic tooth movement remains

largely asymptomatic, thus, probable root contact should be diagnosed clinically with no movement of the tooth, excessive crown tipping toward the miniscrew, and (rarely) miniscrew loosening.

#### 4) Miniscrew fracture

Fracture of a miniscrew is rare if the diameter is greater than 1.5 mm and especially if the miniscrew is tapered. With miniscrew fracture, removal of the bone around the miniscrew thread is indicated.

#### 5) Pain

Pain is a relatively common sequela but usually it is not serious. The pain related to miniscrew operation comes from the nerve endings in the soft tissue and periosteum, not necessarily from the bone proper. Non-steroidal anti-inflammatory drug (NSAID) for 2 days following the procedure is sufficient to manage the postoperative pain in most patients.

#### 6) Bleeding and numbness

Excessive bleeding or numbness is not associated with miniscrew implantation on the tooth-bearing area or midpalate region. However, care should be taken not to injure the palatine neurovascular bundle.

***My great wishes for my lovely students for success. Thanks***



## **Orthodontics**

### **Orthopedic and functional appliances**

There are essentially three alternatives for treating any skeletal malocclusions—growth modification, dental camouflage, and orthognathic surgery. The first two options are used in growing patients, and the latter two can be used in adults.

#### **Orthodontic force vs orthopedic force**

There are two types of forces used in orthodontics. One is “orthodontic force,” which when applied brings about dental change; the other is “orthopedic force,” that brings about skeletal change. Unlike orthodontic forces which are light forces (50–100 gm) bringing about tooth movement, orthopedic forces are heavy forces, generally in the range of 300–500 gm (over 400 gm) per side, that bring about changes in the magnitude and direction of bone growth.

The appliances that produce skeletal changes by applying orthopedic forces are known as “orthopedic appliances.”

#### **Rationale of orthopedic appliance therapy**

Orthopedic appliances generally use teeth as “handles” to transmit forces to the underlying skeletal structures. The basis of orthopedic appliance therapy resides in the use of intermittent forces of very high magnitude. Such heavy forces when directed to the basal bones via teeth, tend to alter the magnitude and direction of the growth of the jaws by modifying the pattern of bone apposition at periosteal sutures and growth sites.

Immediate tooth movement does not occur since hyalinized zones in periodontal ligament caused by heavy forces prevent direct frontal resorption of the socket wall. Orthopedic appliances are worn

intermittently for only about 10–14 hours a day. Tooth movement is also reduced significantly by replenishment of normal circulation when the appliance is not worn.

Thus, skeletal changes rather than tooth movement occur during orthopedic appliance therapy, although some tooth movement is inevitable.

### **Age of the Patient**

It is advisable to start with patients in the mixed dentition period, to make most of the active growth occurring during prepubertal growth spurt -Treatment may have to be continued until the completion of adolescent growth, so as to prevent relapse caused by the re-expression of patient's fundamental growth pattern after the cessation of orthopedic therapy.

### **Timing of Force Application**

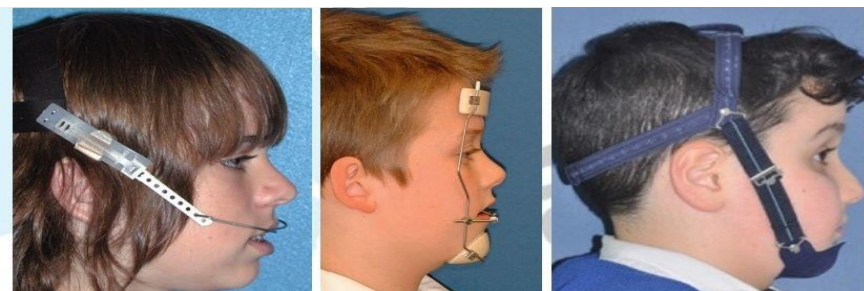
- Optimum timing of extraoral force application is considered to be during evening and night. This is because an increased release of growth hormone and other growth-promoting endocrine factors has been observed to occur during the evening and night rather than during the day. Thus, patients are advised to wear the appliance in the evening after school hours and throughout the night, which is also advantageous in the terms of patient compliance.

The following are the commonly used orthopedic appliances:

I. Headgear

II. Protraction face mask

III. Chin cup appliance



## Headgear

Headgears are mainly used in the management of skeletal class II malocclusion caused by a prognathic maxilla via growth modification. Apart from their orthopedic use, they are also used for the distalization of maxillary molars, as well as for reinforcing intraoral anchorage.

### Components

#### 1. Force-delivering Unit

Face bow: it consists of an outer and an inner bow. The length of the outer bow can be adjusted to produce the desired force vector/line of force. It is contoured to fit around the face. The inner bow is contoured to follow the shape of the dental arch. The anterior portion of the bow should be placed about 4–5 mm away from the maxillary incisors fitting comfortably between the lips at rest.

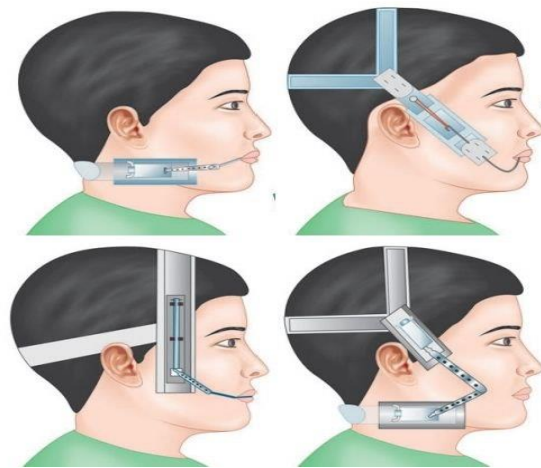


**2. Force generating- unit:** It connects the face bow to the anchor unit. It may be in the form of springs, elastics, or other stretchable material. The force is delivered to the teeth through the face bow and then to the underlying skeletal structures via teeth



**3. Anchor unit:** The extraoral attachments that provide anchorage for headgear can be:

- a. Cervical attachment/neck strap
- b. Occipital attachment/head cap
- c. Combination pull headgear
- d. High pull headgear



### **Mode of Action**

The forces are delivered to the sutures of the maxilla, which compress them and modify the pattern of bone apposition at these sites which will result in changing the magnitude and direction of growth of the maxilla. This restriction of the maxillary growth will allow the mandible to catch up with the maxillary growth as it continues to grow, and eventually correcting the anteroposterior jaw relations.

### **Amount, Duration and Timing of Force**

- Headgears should apply extraoral forces in the magnitude of 400–600 gm per side, intermittently for a duration of 12 to 14 hours a day to bring about the desired skeletal effects.
- Headgear treatment is usually given at 8.5 to 10.5 years in females and 9.5 to 11.5 years in males.
- Excessive force greater than 1,000 gm will result in trauma to the teeth

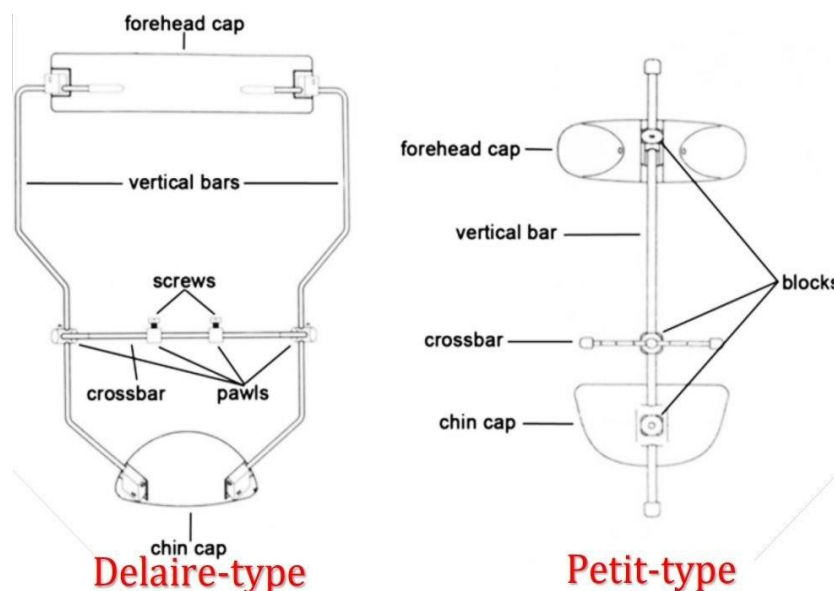
periodontium, while a force of less than 300 gm may produce dental changes rather than skeletal changes.

### **Facemask (protraction face mask)**

Facemask is also called as “reverse pull headgear” or “protraction headgear.” Facemask has been used in the treatment of patients with a mild to moderate skeletal class III malocclusions and a maxillary deficiency and a hypodivergent growth pattern.

### **Components of Face Mask**

The face mask is made of two pads that contact the soft tissue in forehead and chin region. The pads are connected by a midline framework and are adjustable through loosening and tightening of a set screw.



Face mask consists of the following parts:

- a. Forehead cap
- b. Chin cup
- c. Metal framework
- d. Slots for intraoral elastics.

Elastics are used to apply forward pulling force on the upper arch, which are stretched from the intraoral attachment to the slots on the anterior part of the framework, which brings about downward and forward pull of the

maxilla. The most commonly used types are Delaire type and Petit type of face mask.

### **Timing and duration**

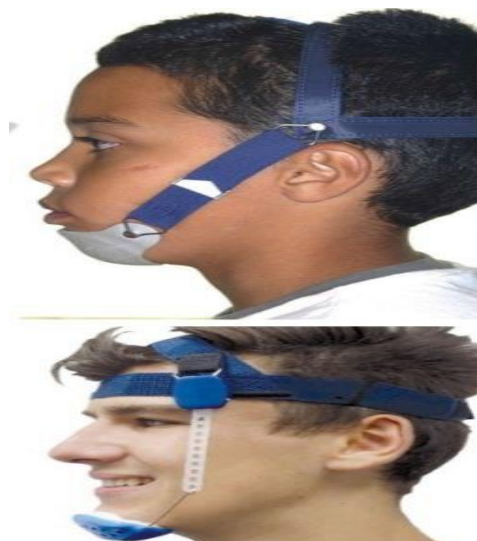There is an increasing body of evidence that orthopedic correction treatment is more likely to be successful if it is carried out prior to the pubertal growth spurt, with the optimal time to intervene at the time of the initial eruption of upper central incisors. The facemask can be attached to transpalatal arches to rapid maxillary expansion appliances. For successful maxillary protraction a force of 300–500 gm/side with 12–14 hours per day wear is required. The treatment time varies from 3 to 16 months.

### **CHIN CUP**

Chin cup is an extraoral orthopedic orthodontic appliance used to treat skeletal class III malocclusions due to mandibular prognathism. It covers the chin and is connected to a headgear. Chin cup appliance is aimed at restraining the forward growth of the mandible.

#### **Chin Cup Assembly :**

- i. Chin cup—covers chin
- ii. Head cap—covers the head
- iii. Elastic strap—connects the chin cup with the head cap.





## **Types of Chin Cup**

Chin cups are available in the following types:

1. Occipital pull chin cup: indicated in patients with:
  - i. A mild skeletal prognathism of the mandible.
  - ii. A decreased facial height.
  - iii. A well-aligned or protrusive, but not retroclined mandibular incisors.
2. Vertical pull chin cup: indicated in patient with open bite.

A force of 150–300 grams is used at the time of the appliance delivery and over the next two months, the force is gradually increased to 450–700 grams per side. The patient is asked to wear the chin cup appliance for 12–16 hours/day to have the desired results.

## **Direction of Force**

- Orthopedic force should be applied in the appropriate direction to have a maximum skeletal effect.
- The desired changes are best achieved when the line of force passes through the center of resistance of the skeletal structures to be moved.

The force direction or force vector should be decided depending on the clinical needs. For example, while treating class II malocclusion with headgear therapy, the selection of cervical attachment produces a force vector that is below the center of resistance of maxillary molars resulting in distalization as well as the extrusion of the molars; while an occipital attachment produces the intrusion of molar

- An appropriate site of anchorage should be selected based on what type of skeletal and tooth movement would be beneficial in a given case.

## **Functional appliances**

They are appliances that utilize, or eliminate the forces of muscles of mastication to modify growth in order to correct a malocclusion.

There are many different types of functional appliances, but most work by the principle of posturing the mandible forwards in growing patients.

They are most effective at changing the anteroposterior occlusion between the upper and lower arches, usually in patients with a mild to moderate Class II skeletal discrepancy. They are not as effective at correcting tooth irregularities and improving arch alignment, so treatment often involves a phase of fixed appliances.

### **How do functional appliances work?**

The mode of action of functional appliances is one of the most controversial areas in orthodontics. When the mandible is postured, pressures are created by stretching of the muscles and soft tissues. These pressures are then transmitted to the dental arches and skeletal structures. However, it is not clear whether the changes are dentoalveolar or skeletal and at what proportions.

Randomized controlled clinical trials show that changes caused by functional appliances are principally dentoalveolar. There are some minor skeletal changes, with some degree of maxillary restraint as well as mandibular growth. These changes, although clinically welcome, are on average too small (1–2 mm) to predictably replace the need for orthognathic surgery in severe skeletal discrepancies. The results of trials have also shown a large variability of response between individuals, with some patients showing more extensive skeletal changes. This may explain why some cases seem to progress extremely well with obvious facial changes, while others show limited facial improvement.

In some cases, even with minimal skeletal change, the patient's facial appearance can be improved. This is because the patient's incisor relationship has been corrected, often allowing the patient to comfortably obtain competent lips at rest.

Functional appliances have often been prescribed to cause 'growth modification'. The results of high-quality studies suggest that on average, growth changes achieved are smaller than was once initially hoped. This

does not mean that total correction is impossible, but total correction of a severe deformity with growth modification alone rarely occurs. It is more likely that functional appliances improve the malocclusion, in many cases perhaps to a point where orthodontic camouflage rather than orthognathic surgery can be used to complete the treatment.

One area of difficulty for the clinician is whether to attempt growth modification for a child with a severe mandibular deficiency. However, if the child, parents, and clinician understand that the chance of major improvement is only about 20–30% then the treatment can be undertaken. If the growth modification fails, or is insufficient to fully correct the problem, then camouflage or orthognathic surgery when the patient is older may need to be considered.

### **Timing of treatment**

Functional appliances are most effective when the patient is growing, and can be used a little later in boys as girls complete their growth slightly earlier. It has been suggested that treatment should, if possible, coincide with the pubertal growth spurt. There have been many attempts to predict this growth spurt, including using maturation changes seen on the cervical vertebrae visible on lateral skull radiographs. However, it can be difficult to predict the pubertal growth spurt accurately regardless the used technique. Fortunately, studies have shown that favorable changes with functional appliances can occur outside this growth spurt. The key factor is that the patient is still actively growing.

One area of controversy is whether to provide early treatment (in the early mixed dentition when the patient is under 10 years old) or wait until the late mixed dentition. Early treatment usually involves two phases of treatment: an initial phase with the functional appliance, followed by a pause while the adult dentition erupts, and then a second phase of fixed appliances. In contrast to this, if functional appliance treatment is started

in the late mixed dentition, then by the end of the functional stage of treatment the adult dentition is usually erupted sufficiently to proceed straight onto the fixed appliances.

High-quality research has shown that both approaches successfully corrected the increased overjet, and there was no difference in the amount of skeletal change achieved, the need for extractions, or the quality of the final occlusal alignment.

Early treatment does, however, provide a transient improvement in self esteem and there is some evidence that it reduces the risk of incisal trauma by up to 40%. However, when patients had their functional appliance fitted earlier, their treatment lasted longer and they needed to attend more appointments. This means that early treatment is more expensive and more importantly, the treatment burden is greater for the patient.

Early treatment should therefore be restricted to patients where there is thought to be a particular risk of trauma to the teeth, or if they are experiencing bullying or teasing about their malocclusion.

### **Types of malocclusion treated with functional appliances**

Although functional appliances have been used to treat a whole variety of malocclusions, they are usually used for the treatment of Class II malocclusions.

They are typically used for treatment of Class II division 1, but with minor alterations can be used for the treatment of Class II division 2. Some functional appliances, such as modified twin-block and FR3 Frankel appliances, have been described for the treatment of Class III malocclusions, but there is no evidence of any skeletal correction. These Class III malocclusions are often more simply treated by orthodontic camouflage using fixed appliances, so functionals are less frequently used for the treatment of Class III malocclusions.

### **Treatment of Class II division 1 malocclusions**

Functional appliances are most commonly used for the treatment of Class II division 1 malocclusions. If the arches are well-aligned at the start of treatment, and the only problem is an anteroposterior discrepancy between the arches, then the functional appliance alone may be sufficient. In these cases, it is wise to slightly overcorrect the malocclusion to allow for some relapse and ask the patient to wear the appliance at night until the end of their growth period.

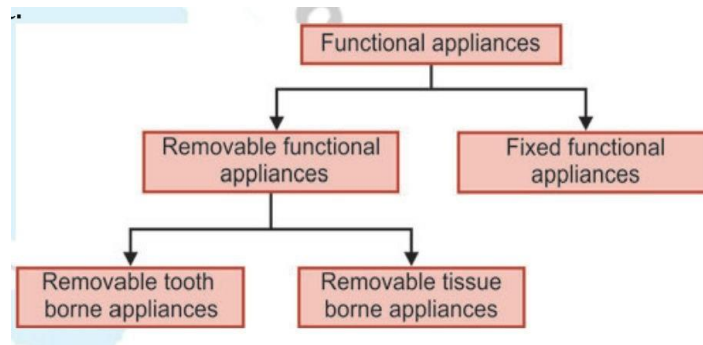
Functional appliances are often used as a first phase of treatment, then the patient is reassessed for the need for a second phase of fixed appliance treatment.

### **Treatment of Class II division 2 malocclusions**

This type of malocclusion can be difficult to treat, partly due to the increased overbite. The use of a functional appliance before fixed appliances may provide a more efficient alternative to treating these malocclusions with fixed appliances alone. The approach to treatment is simple. The Class II division 2 incisor relationship is converted to a Class II division 1 relationship and then treated with a functional appliance. The retroclined upper incisors can be proclined forward using a pre-functional removable appliance, or a sectional fixed appliance on the upper labial segment.

### **Types of functional appliance**

A simple easily understandable classification is to divide them into removable functional appliances or fixed functional appliances. Removable functional appliances can further be classified into removable tooth-borne functional and removable tissue-borne functional appliances. The fixed functional appliances are tooth-borne.



### **Removable Tooth-Borne Appliances**

These appliances depend on the stretch of the soft tissues caused by the mandible being positioned downward and forward, as well as by the muscle activity generated by the mandible attempting to return to its original position. E.g., Activator, Bionator, and Twin block appliance.

### **Removable Tissue-Borne Functional Appliances**

These appliances are used to recontour the facial soft tissue adjacent to the teeth as well as posture the mandible downward and forward. Example: Functional regulator/Frankel appliance.

### **Fixed Tooth-Borne Functional Appliances**

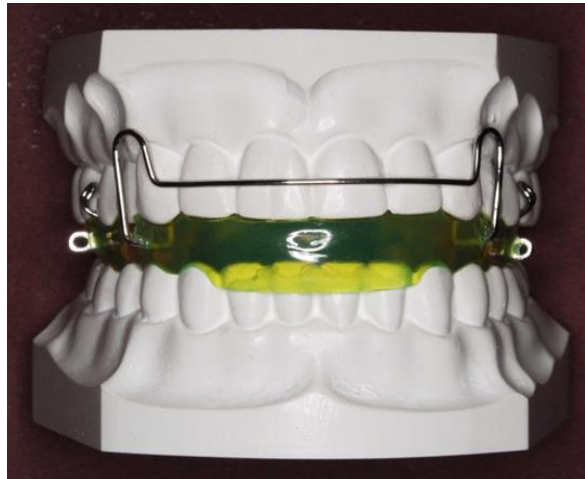The fixed tooth-borne functional appliances are fitted on the teeth and cannot be removed by the patient at will. Example: Herbst appliances.

| <b>Advantages</b>   | <b>Disadvantages</b>   |
|---|--|
| <ul style="list-style-type: none"> <li>- They are effective in vertical control of increased overbite.</li> <li>- They can be used in mixed dentition.</li> <li>- They require minimal chairside adjustment.</li> </ul> | <ul style="list-style-type: none"> <li>- The success of functional appliances therapy solely depends on patient cooperation.</li> <li>- Precise tooth movement is not possible with functional appliances.</li> <li>- Treatment duration of functional appliances is often prolonged.</li> </ul> |



## **ACTIVATOR**

The activator original designs dates back to the late 19th century. It was known as Monobloc and Andresen-Häupl activator. It had been successfully used by many generations of orthodontists. The activator is generally used for the treatment of Class II division I malocclusion.



### **Dental Changes Produced by Activator**

#### ***Incisor Changes***

The activator helps in successful overjet and overbite reduction by retroclination of upper incisors and proclination of lower incisors.

#### ***Vertical Molar Changes***

The design of the activator permits removal of occlusal acrylic above the lower molar and premolars. This facilitates upward and forward eruption of the lower molars and makes the activator a logical choice for low angle class II division 1, where there is a need for the molars to be free to erupt into the freeway space. Lower molar eruption of this kind is assumed to be a favorable factor in correcting the class II molar relationship and reducing the deep incisor overbite.

#### **Changes In Lower Facial Height**

The activator produces an increase in lower facial height by encouraging eruption of lower molars when acrylic is trimmed above the lower molars.

\_ Class II malocclusion with open bite

### **Indications**

- Class I malocclusion with deep bite
- Class II malocclusion with open bite
- Class II division 1 malocclusion
- Class II division 2 malocclusion after aligning the incisors
- Used for treating patients who snore during sleep.

### **Contraindications**

- Crowded arch
- Increased lower facial height
- Extreme vertical mandibular growth
- Severe proclined lower incisors
- Retroclined upper incisors
- Crossbite tendency
- Gross intra-arch irregularities.

| <b>Advantages</b>   | <b>Disadvantages</b>  |
|---|---|
| <ul style="list-style-type: none"><li>- Treating mixed and deciduous dentition is possible</li><li>- Appointments can be delayed over 2 months</li><li>- Tissues not injured</li><li>- Worn at night time only</li><li>- Helps to eliminate abnormal habits</li><li>- Oral hygiene is maintained.</li></ul> | <ul style="list-style-type: none"><li>- Fully rely on patient cooperation</li><li>- Little value in cases with crowding</li><li>- Force on an individual tooth can not be controlled</li><li>- Little or no response in older patients</li><li>- Bulky and uncomfortable.</li></ul> |

## **Clinical Management**

High-quality impressions that record the full extension of the lingual sulci are needed. Bite registration is needed to record the forward posture of the patient. For patients with overjet up to 8 mm, this can be done in one step, while keeping the vertical opening to a minimum of 2-3 mm. This can be performed in one of two ways, either by directly softening a horse-shoe-shaped wax and asking the patient to bite on it or to fabricate two bite plates (upper and lower) then a thin sheet of wax is used in between to record the relation. Either way, the excess wax is trimmed, and the wax is cooled, and checked on the study models and in the mouth whenever possible. During bite registration care should be exercised to maintain the patient's mid-line and to have equal advancement on both sides. The patient should be trained to protrude the mandible and keep it in this position for a few minutes before the actual registration so that the required relation is reproduced without the need to repeat the process.

## **BIONATOR**

The bionator was developed to increase patient's comfort and facilitate daytime wear to increase the functional use of the appliance. Balter accomplished this by drastically reducing acrylic bulk of the appliance.



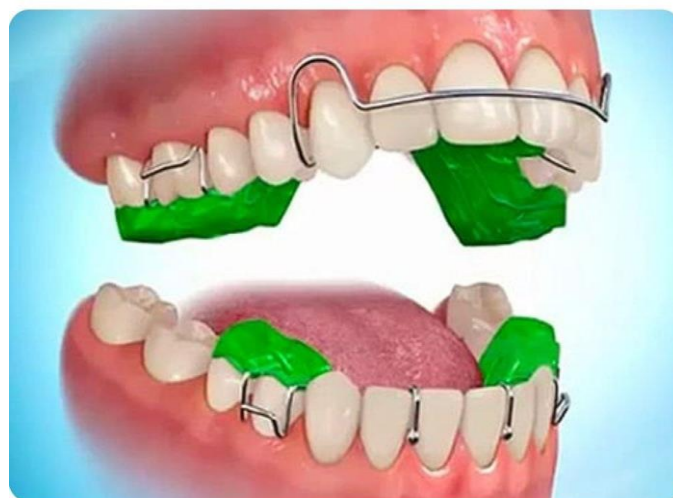## **TWIN-BLOCK APPLIANCE**

The Twin-block appliance is composed of maxillary and mandibular retainers that fit tightly against the teeth, alveolus and adjacent supporting structures. The precise clasp configuration depends on the type of deciduous or permanent teeth and number of teeth present at the time of appliance construction.

The lower part of the twin block appliance consists of a horseshoe of acrylic that extends anteriorly from the mesial of the first permanent molars. The inclines on the upper and lower portions are relatively steep, forcing the patient to advance the mandible in order to close.

The acrylic covers the lingual aspect of the premolar/ deciduous molars and the canines and incisors. There should not be any acrylic material touching the lower molars, this allows the lower molar to erupt vertically when the acrylic on the maxillary block is trimmed to increase the vertical dimension in patients with a deep bite and accentuated curve of Spee. If the patients have a tendency toward an anterior open bite, the blocks are left untouched.

The twin block appliance has been shown to produce an increase in mandibular length, incisor proclination and variations in lower anterior facial height.



### **Indications**

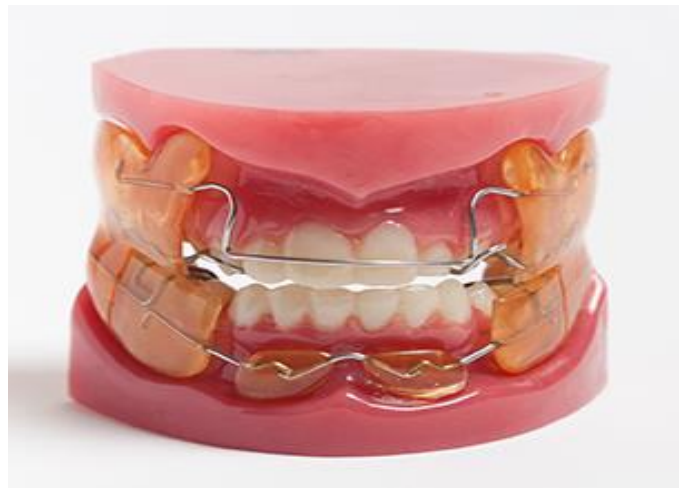Twin-block appliance is most commonly used in the treatment of class II malocclusions.

### **Duration of Treatment**

Full time wearing of twin block appliance is advised including while eating and the duration of treatment usually is about (9–12) months.

### **FRANKEL APPLIANCE**

The Frankel appliance is the only completely tissue-borne appliance. It is named after the inventor, who originally called it the function regulator (or FR). There are different versions designed to treat different types of malocclusions. It also has buccal shields to hold the cheeks away from the teeth and stretch the periosteum, allegedly to cause bone formation, although this has never been proved. It can be difficult to wear, is expensive to make, and is troublesome to repair. As a result, it is now used less frequently.



### **ORAL SCREEN (VESTIBULAR SCREEN)**

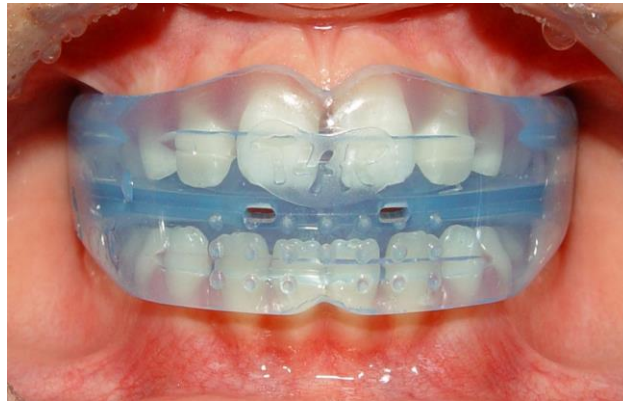It is composed of acrylic base material, which fits in the buccal/labial vestibule of the mouth.

### **Indications**

The oral screen is mostly used for treating oral habits like thumb sucking, mouth breathing, tongue thrusting, and lip biting.

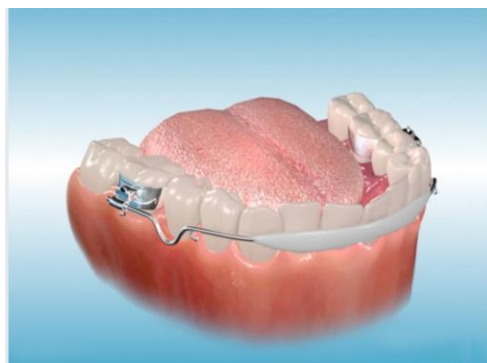### **Mechanism of Action**

Oral screen acts like a mechanical barrier between teeth and lips, tongue, thumb and thereby help in correcting the oral habits, such as mouth breathing, thumb sucking, lip biting and tongue thrusting.



### **LIP BUMPER**

The lip bumper is a fixed functional orthodontic appliance that works by altering the equilibrium between cheeks, lips and tongue and by transmitting forces from perioral muscles to the molars where it is applied.



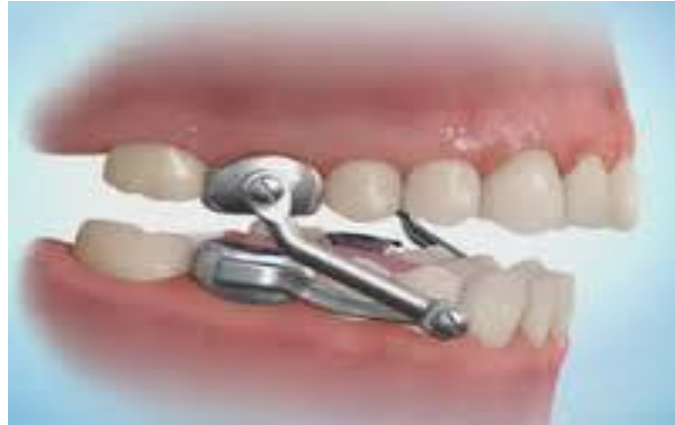### **Uses**

The lip bumper is used to treat the habits of lip suckling and lip biting, provide molar anchorage, and can be used for space gaining in the lower arch.

### **HERBST APPLIANCE**

It is a fixed functional appliance. There is a part attached to the upper buccal segment teeth and a part attached to the lower buccal segment

teeth. These parts are joined by a rigid arm that postures the mandible forwards. As it is a fixed appliance, it removes some (but not all) compliance factors. It is as successful



at reducing overjet. It is, however, slightly better tolerated than the bulkier removable appliance, with patients finding it easier to eat and talk with it in place. The principal disadvantages are the increased breakages and higher cost of the Herbst appliance.

**The functional appliance does not produce an effect:**

If there is no progress, this could be due to a number of factors:

- Poor compliance
- Lack of growth or an unfavorable growth rotation
- Problems with the design or fit of the appliance.

Poor compliance is the most common potential problem with these appliances. Compliance tends to be better with younger patients and those wearing fixed functionals, such as the Herbst appliance.

*My great wishes for my lovely students for success. Thanks*



## Orthodontics

### Retention

Retention is the phase of orthodontic treatment, which maintains the teeth in their orthodontically corrected positions following the cessation of active orthodontic tooth movement.

Relapse is officially defined by the British Standards Institute as the return, following correction, of the features of the original malocclusion.

However, what is more relevant to patients are any post-treatment changes in tooth position, which can be defined as any changes from the final tooth position at the end of treatment. Post-treatment changes may be a return towards the original malocclusion, but may also be movement caused by growth or ageing, unrelated to the orthodontic treatment.

#### **WHY IS RETENTION NECESSARY?**

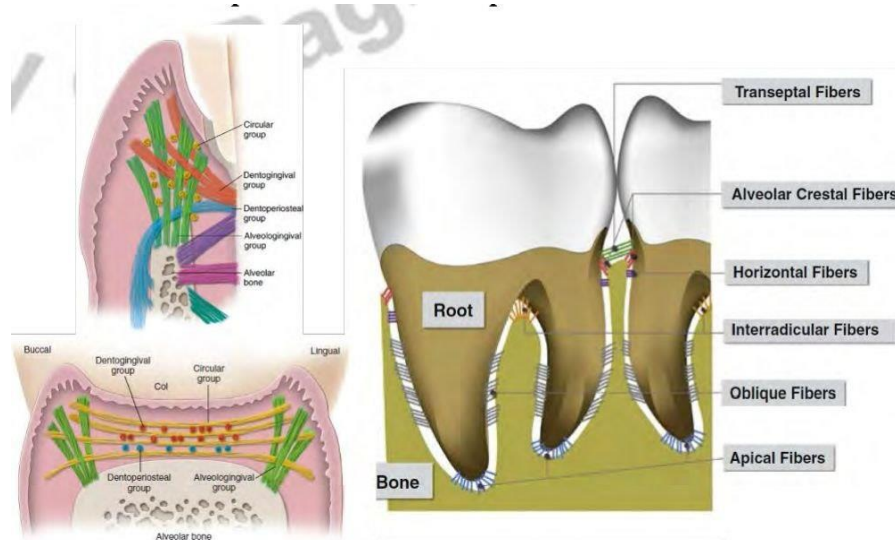
Retention is necessary for the following reasons:

1. The gingival and periodontal tissues are affected by orthodontic tooth movement and require time for reorganization when the appliances are removed.
2. The teeth may be in an inherently unstable position after the treatment so that soft tissue pressures constantly produce a relapse tendency.
3. Changes produced by growth may alter the orthodontic treatment result.

#### **Gingival and periodontal factors**

When the teeth are moved, the periodontal ligament and associated alveolar bone remodels. Until the periodontium adapts to the new position, there is a tendency for the stretched periodontal fibers to pull the tooth back to its original position. Different parts of the periodontal

ligament complex remodel at different rates. The alveolar bone remodels within a month, the principal fibers rearrange in 3–4 months, and the collagen



fibers in the gingivae reorganize after 4–6 months. However, elastic fibers in the dentogingival and interdental fibers, around the neck of the tooth, can take more than a year to remodel. Until the fibers have remodeled there is a tendency for the tooth to be pulled back to its original position.

In practice, this means that teeth need to be held long enough to allow the periodontal fibers to remodel to their new position. Rotated teeth are particularly prone to relapse due to the periodontal fibers around the neck of rotated teeth pulling the teeth back to their original position. During treatment, it is advisable to start derotating them as early as possible in order to give the fibers longer to reorganize and adapt to the new position. Overcorrecting the rotation, before aligning the tooth to the final position, is also advisable. Finally, there is a very minor surgical procedure that can be done under local anesthesia to cut the fibers around the neck of the teeth. This process is called circumferential supracrestal fiberotomy, or pericision.

## **Occlusal factors**

Uneven or deflecting occlusal contacts at the end of treatment may also cause tooth movement, resulting in unwanted post-treatment changes. It is therefore important, where possible, to ensure that a good occlusion is achieved at the end of treatment to increase stability. While theoretically, this sounds sensible, this has not yet been proven clinically, though gross occlusal interferences will predispose to unwanted post-treatment changes. One of the few occasions, when no retainers are required at all, uses the occlusion alone is when a labial crossbite is corrected and the result is maintained by the overbite.

## **Soft tissues**

The teeth lie in an area of balance between the tongue on the lingual aspect and the cheeks and lips on the buccal and labial aspects. This area of balance is sometimes referred to as the neutral zone. Although the forces from the tongue are stronger, the activity of a healthy periodontium will resist proclination of the teeth. However, the further teeth are moved out of this zone of stability, the more unstable they are likely to be. This is particularly true for the lower labial segment. If this is either proclined or retroclined excessively, relapse is more likely. In the same way, if the archform (overall shape of the arch) is markedly changed, it is more likely to relapse due to soft tissue pressures. Changes in a patient's intercanine width are more unstable than changes in the intermolar width, which in turn are more unstable than changes in the interpremolar width. Where possible, the original lower archform is therefore maintained throughout treatment, and the upper archform is then planned around the lower. Although the theory about placing the teeth in the neutral zone is useful, practically there are two major problems for the clinician. Firstly, we do not know exactly where the neutral zone is and how big it is. Secondly, it is likely that due to changes in muscle tone

with age, the neutral zone will change as the patient gets older.

## **Growth**

Although the majority of a patient's growth is complete by the end of puberty, it is now known that small age changes may be occurring throughout life. Subtle changes in the relative positions of the maxilla and the mandible mean that the oral environment and therefore the pressures on the dentition are constantly changing. If the pressures on the teeth are always changing, then it is perhaps not surprising that there is a risk of change in the position of the teeth as the patient gets older. These late, small growth changes may at least partly explain the late lower incisor crowding that is seen in patients who have had, but also in those who have not had, orthodontic treatment.

## **Can the orthodontist prevent post-treatment changes in the long term?**

If a patient has a healthy periodontium, the orthodontist can influence periodontal risk factors for relapse by maintaining the teeth in position for long enough to allow fibers to remodel, or by cutting the supracrestal fibers in a process known as pericision. Occlusal risk factors can also be minimized by the orthodontist, who has the ability to position teeth in the correct occlusal relationships.

The orthodontist, however, cannot prevent long-term growth and soft tissue changes, which perhaps should be regarded as normal age changes. At the present time, we are unable to predict the nature of these late changes, which remain an unpredictable cause of post-treatment changes throughout life. These late changes may have little or nothing to do with the orthodontic treatment, but patients may attribute the unwanted post-treatment changes to their orthodontic treatment. During the consent process for orthodontic treatment, it is important that patients are informed about the effects of these unpredictable late age changes, and

how they can be minimized.

### **How common are post-treatment changes?**

Long-term studies of post-treatment changes following fixed appliances have shown that 10 years after retainers are stopped, up to 70% of patients may need retreatment due to these post-treatment changes. These changes continue to get worse over the following decades.

It is difficult to predict, on an individual basis, what post-treatment changes in tooth position will occur. At the present time we are not able to identify which patients will have teeth that will remain in a reasonably stable position, and which patients will not, so we have to presume every patient has the potential to show post-treatment changes. As a result, a contemporary approach is to recommend long-term retention (in the form of fixed retainers, or long-term wear of removable retainers) for as long as the patient wants to keep their teeth stable. This information must be passed onto the patient as part of the informed consent process.

### **Consent and the responsibilities of retention**

The process of obtaining valid consent requires patients to understand all their options for treatment, including their commitments, and the risks and benefits involved. Post-treatment changes and the need for retention is a vital part of this consent discussion before treatment begins. Arguably the aspect of orthodontics that requires the most commitment from patients is the need to wear and maintain retainers in the long term. A patient who is unwilling, or unable, to commit to retention may not be suitable for treatment.

### **The clinician is responsible for:**

- informing the patient of the need for retainers
- choosing a retention regimen appropriate for each individual patient
- providing advice about how to minimize risks caused by the retainers
- making arrangements for their long-term maintenance, informing the

patient of any costs involved.

**The patient is responsible for:**

- wearing the retainers as advised, including how often to wear the retainers and ensuring they look after them as advised in order to minimize risks
- arranging regular checks of their retainers for as long as they are wearing them, to make sure they are maintained in a condition that ensures they are safe and can successfully reduce relapse. There may be cost implications for the patient for this long-term maintenance.

**Retainers**

Retainers are used to reduce relapse, they can either be removable or fixed. The clinician is faced with a multitude of different options when choosing which retainer to use. When choosing the retention regimen, the following factors should be considered:

- Likely stability of the result
- Initial malocclusion
- Oral hygiene
- Quality of the result (is any settling of the occlusion required?)
- Compliance of patient
- Patient expectations
- Patient preference
- Ease of maintenance.

**Removable retainers**

There are many different types of removable retainers, the most common are Hawley, and clear plastic retainer.

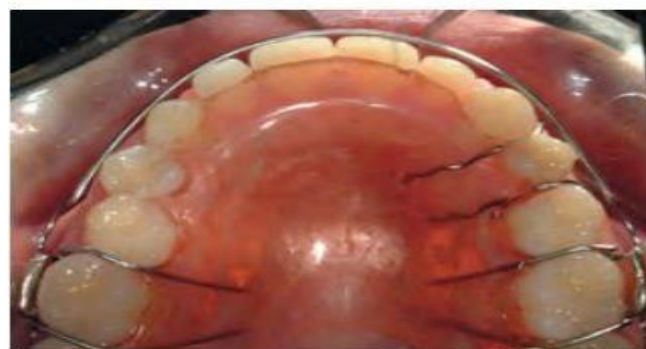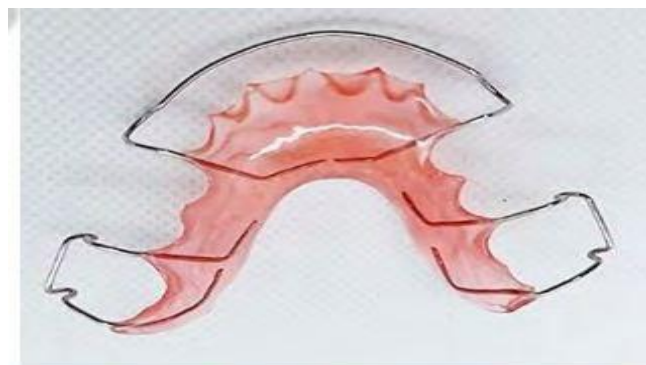
**How often should removable retainers be worn?**

It is already mentioned that due to the unpredictable nature of post-treatment changes, long-term wear is advisable. However, how many hours per day should patients wear removable retainers? The best quality

research evidence suggests that both Hawley and clear plastic retainers only need to be worn at night. This reduces the amount of compliance required from a patient, and helps to extend the longevity of the appliance. This of course excludes cases with a high risk of relapse, when full-time wear using a fixed retainer is indicated.

### **Hawley retainer**

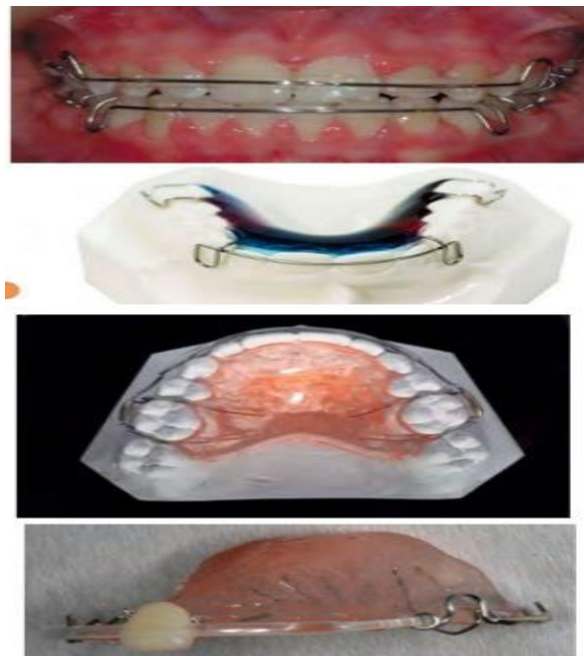
The Hawley retainer is the original removable retainer. It is a simple and robust appliance made from an acrylic baseplate with a metal labial bow. It was originally designed as an active removable appliance, but it became clear that it could be used as a retainer to maintain the teeth in the correct position after treatment. It has the advantages of being simple to construct, reasonably robust, rigid enough to maintain transverse corrections, and it is easy to add a prosthetic tooth. When replacing missing teeth, it is advisable to put rigid metal stops on the retainer mesial and distal to any prosthetic tooth, to prevent relapse. Hawley retainers also allow more rapid vertical settling of teeth than clear plastic retainers, due to the lack of complete occlusal coverage.





There are essentially three alternatives for treating any skeletal Variations. Various adaptations are possible, depending on the case:

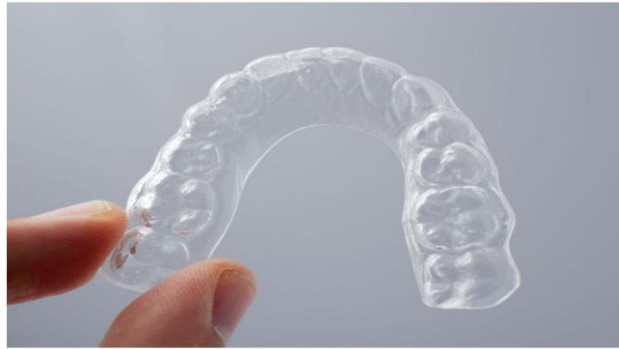- Acrylic facing can be added to the labial bow to help control rotations.
- A reverse U-loop can be used to control the canine position.
- A passive bite-plane can be added to maintain corrections of deep overbites.
- The labial bow can be soldered to the cribs, so there are fewer wires to cross the occlusal surfaces and interfere with the occlusion.
- Clear polyethylene bow to provide improved esthetics.



### **Clear plastic retainers**

They offer a number of potential advantages over traditional Hawley retainers:

- Superior esthetics
- Less interference with speech
- More economical and quicker to make
- Less likely to break
- Ease of fabrication
- Superior retention of the lower incisors.



Both Hawley and clear plastic retainers are equally successful in the upper arch, but the clear plastic retainers are better at preventing relapse in the lower arch. It is important that the patient is instructed never to drink with the clear plastic retainer in situ, particularly cariogenic drinks. The retainer can act like a reservoir, holding the cariogenic drink in contact with the incisal edges and cuspal tips and leading to decalcification.

Clear plastic retainers may be contraindicated in patients with poor oral hygiene. This is because these types of retainers are retained by the plastic engaging the undercut gingival to the contact point. If the oral hygiene is poor, then hyperplastic gingivae can obliterate these areas of undercut, which means the retainer may be loose.

### **Fixed retainers**

Fixed or bonded retainers are usually attached to the palatal aspect of the upper or lower labial segment, using normal acid-etch composite bonding.

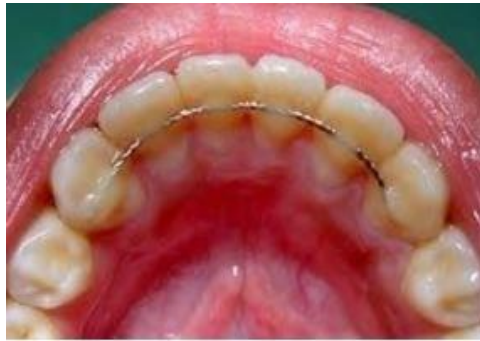#### ***Fixed retainers are advised in the following cases:***

- Closure of spaced dentition (including median diastema).
- Following correction of severely rotated teeth.
- Where there has been substantial movement of the lower labial segment, either excessive proclination or retroclination, or a significant change in the intercanine width.
- Where an overjet has been reduced, but the lips are still incompetent.

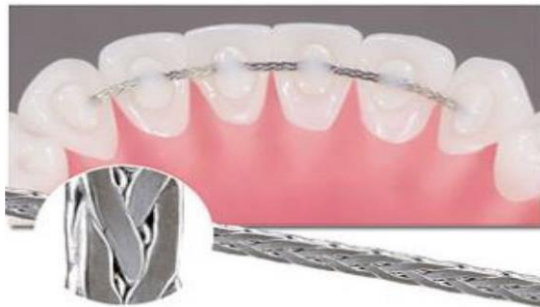- Combined periodontal and orthodontic cases, where reduced periodontal support makes relapse more likely.

There are different types of bonded retainers:

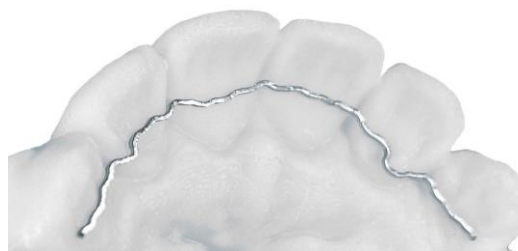- Multistrand retainers bonded to each tooth.



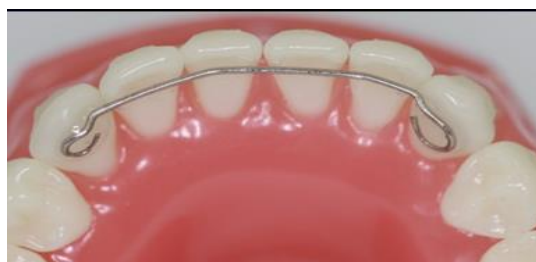- Flexible chain retainers bonded to each tooth



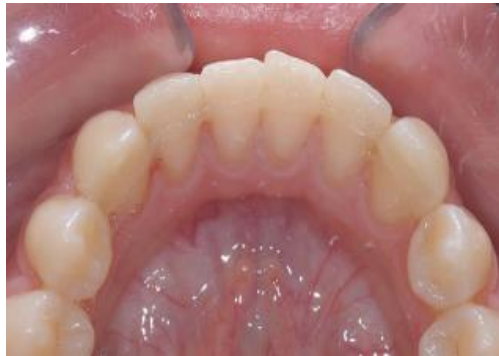- Nickel titanium computer-assisted design/manufacture (CAD/CAM) retainer.



- Rigid canine-and-canine retainers, which are only bonded to the canine teeth.



- Fiber-reinforced retainer.

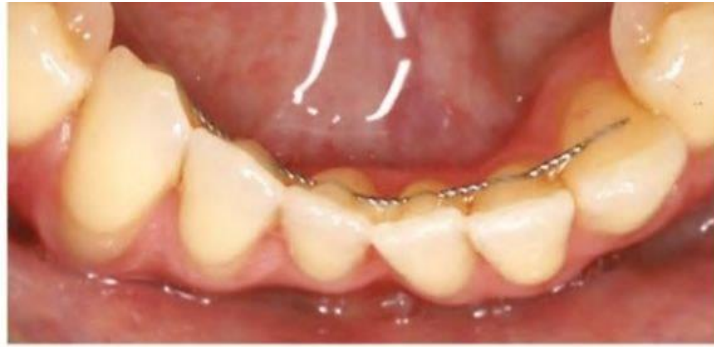

The multistrand ‘twistflex’ wire type, bonded to each tooth in the labial segment, is the commonest type of retainer. In rare situations, activity may develop in these wires, causing unwanted tooth movement, which has led to the development of flexible chain retainers and nickel-titanium CAD/CAM retainers to ensure a passive fit.

Fixed retainers bonded only to the canine teeth allow easier cleaning. These canine-and-canine retainers are more rigid, and are sometimes referred to as ‘fail-safe’. This because if one attachment fails, the patient will immediately know about it and get it repaired. The disadvantage with the canine-and-canine retainers is that they may result in relapse of the incisors, which are not bonded to the wire. The fiber-reinforced retainers are not recommended as they tend to fracture more frequently due to lack of flexibility.

Bonding retainers is a very technique-sensitive process. The tooth surface should be thoroughly cleaned before bonding, in particular removing any calculus lingual to the lower labial segment (etching alone is often not sufficient). A dry field needs to be maintained and the wire held passively in position while being bonded to the teeth with a composite resin using the acid-etch technique.

If the bonded retainer is not passive when bonded, or is distorted in situ, it can cause unwanted tooth movement, which can compromise esthetics and dental health.



The most common problem with bonded retainers is localized relapse if there is partial debond of the retainer. To overcome this, some clinicians use dual retention—using a bonded retainer, backed up with a removable retainer at night. This ‘belt and braces’ approach ensures that if a bonded retainer partially debonds, the teeth can be maintained in position until it can be repaired.

### **Care of retainers**

In the past, patients were asked to wear retainers for only 1–2 years. However, now that we have a better understanding of the risk of relapse, we need to ask our patients to wear them for longer. It is therefore essential that the patients have a clear understanding of how to look after the retainers.

Removable retainers are easier to care for, as they can be removed to allow oral hygiene intra-orally, in addition to easier cleaning of the retainers themselves. Although toothpaste can be used to clean acrylic-based retainers, like the Hawley retainer, many clear plastic retainers need to be cleaned with special cleaning materials that do not degrade the plastic. Some clinicians provide a spare retainer for each arch, in case the original is lost. This is particularly the case with clear plastic retainers, which are cheaper to fabricate.

Fixed retainers have the potential to cause both periodontal disease and caries unless they are well maintained. Fixed retainers can be used safely in the long term, provided patients are properly instructed how to look

after them. They should be shown how to clean interdentally—either by using floss that can be threaded under the wire, or by the gentle use of small interdental brushes or other similar interdental cleaning aids. Fixed retainers need to be reviewed on a regular basis by the orthodontist or dental practitioner to check for any bond failure, or unwanted tooth movement caused by fixed retainers that have become active.

It is the orthodontist's responsibility to ensure that the patient is fully informed on how to look after their retainers in the long term to avoid any adverse effects.

### **Adjunctive techniques used to reduce post-treatment changes**

Adjunctive techniques are additional soft and hard tissue procedures, usually used in addition to retainers, to help enhance stability:

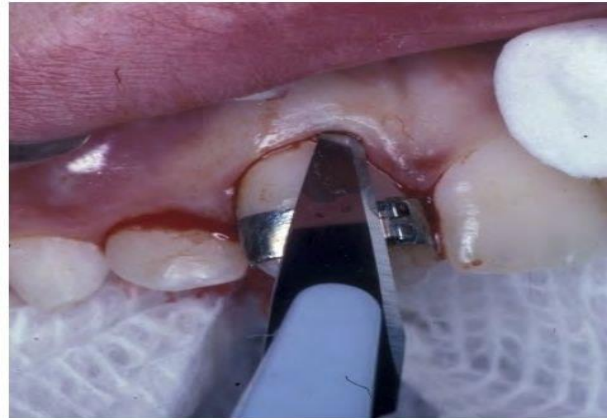- Pericision
- Interproximal reduction.

### **Pericision**

This is also known as circumferential supracrestal fibreotomy. The principle is to cut the interdental and dento-gingival fibers above the level of the alveolar bone. The elastic fibers within the interdental and dentogingival fibers have a tendency to pull the teeth back towards their original position. This is particularly true with teeth that have been derotated.

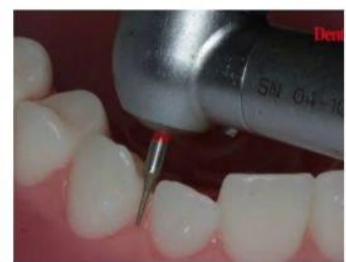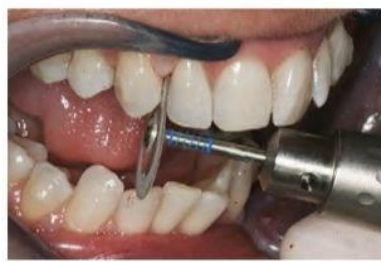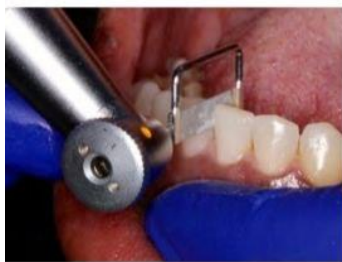Pericision is a simple procedure undertaken under local anesthetic and requires no periodontal dressing afterwards. The cuts are made vertically into the periodontal pocket, severing the supra-alveolar fibers around the neck of the teeth, but taking care not to touch the alveolar bone. The technique has been shown to reduce rotational relapse by up to 30% and is most effective in the maxilla. There are no adverse effects on the

periodontal health, provided there is no evidence of inflammation or periodontal disease before the pericision.



### **Interproximal reduction**

This is also known as reproximation or enamel stripping. The removal of small amounts of enamel mesiodistally has been used to reshape teeth and to create small amounts of space. It has been suggested that by flattening the interdental contacts, this will increase the stability between adjacent teeth. It may also be the case that by removing small amounts of tooth tissue any minor crowding is relieved, avoiding possible proclination of the lower labial segment and increase in the intercanine width, both of which are potentially unstable movements.



*My great wishes for my lovely students for success. Thanks*