

# Endodontics

## Lecture 1

### **Introduction and Scope of Endodontics**

Endo is a Greek word for "Inside" and Odont is Greek word for "Tooth". Endodontic treatment treats inside of the tooth. **Endodontics** is the branch of clinical dentistry associated with the prevention, diagnosis and treatment of the pathosis of the dental pulp and peri-radicular tissue. That is, the main aim of the endodontic therapy involves to:

- i. Maintain vitality of the pulp.
- ii. Preserve and restore the tooth with damaged and necrotic pulp.
- iii. Preserve and restore the teeth which have failed to the previous endodontic therapy, to allow the tooth to remain functional in the dental arch.

### **OBJECTIVE OF ENDODONTIC TREATMENT**

The primary objective of endodontic therapy is to create a biologically acceptable environment within the root canal system which allows the healing and continued maintenance of the health of the peri-radicular tissue. This objective can be achieved by eliminating the bacteria (source of infection) from within the root canal system, and sealing the root canal and tooth to prevent re-infection. Since nothing is as good as the natural teeth, one should take care of them.

The endodontic therapy is a necessary treatment to cure a damaged or diseased tooth. Endodontics has been defined as art as well as science of clinical dentistry because in spite of all the factual scientific foundation on which the endodontics is based, to provide an ideal endodontic treatment is an art in itself.

Endodontic treatment encompasses procedures that are designed to maintain the health of all or part of the dental pulp. When the dental pulp is diseased or injured, treatment is aimed at preserving normal peri-radicular tissues. When apical periodontitis has occurred treatment is aimed at restoring the peri-radicular tissues to health: this is usually carried out by root canal treatment, occasionally in combination with surgical endodontics.

## **SCOPE OF ENDODONTICS**

Scope of endodontics includes following:

- a. Vital pulp therapy (pulp capping, pulpotomy)
- b. Diagnosis and differential diagnosis of oro-facial pain.
- c. Root canal treatment of teeth with or without periradicular pathology of pulpal origin.
- d. Surgical management of pathology resulting from pulpal pathosis.
- e. Management of avulsed teeth (replantation)
- f. Endodontic implants
- g. Root end resections, hemisections and root resections
- h. Retreatment of teeth previously treated endodontically
- i. Bleaching of discolored teeth.
- j. Coronal restorations of teeth using post and cores

## **INDICATIONS FOR ROOT CANAL TREATMENT**

Root canal treatment may be carried out on all patients where other dental procedures may be undertaken. Specific indications are

1. An irreversibly damaged or necrotic pulp with or without clinical and/or radiological findings of apical periodontitis.
2. Elective devitalization, e.g. to provide post space, prior to construction of an overdenture, doubtful pulp health prior to restorative procedures, likelihood of pulpal exposure when restoring a (misaligned) tooth and prior to root resection or hemisection.

## **CONTRAINDICATIONS FOR ROOT CANAL TREATMENT**

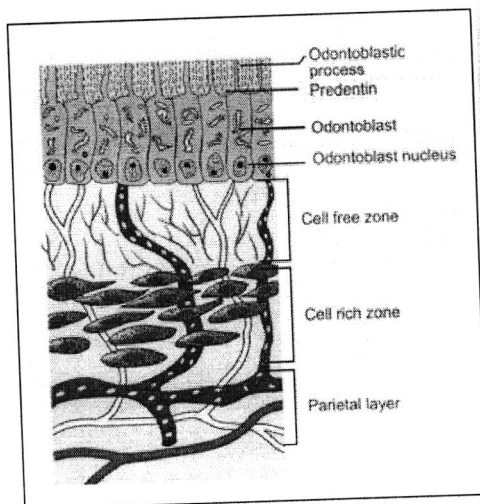
1. Teeth that cannot be made functional nor restored.
2. Teeth with insufficient periodontal support.
3. Teeth with poor prognosis, uncooperative patients or patients where dental treatment procedures cannot be undertaken.
4. Teeth of patients with poor oral condition that cannot be improved within a reasonable period.

## **HISTOLOGY OF DENTAL PULP**

The dental pulp is soft tissue of mesenchymal origin located in the centre of the tooth. It consists of specialized cells, odontoblasts arranged peripherally in direct contact with dentin matrix. This close relationship between odontoblasts and dentin is known as "pulp-dentine complex". The pulp is connective tissue system composed of cells, ground substances,

fibres, interstitial fluid, odontoblasts, fibroblasts and other cellular components. Pulp is actually a microcirculatory system consists of arterioles and venules as the largest vascular component. When pulp is examined histologically, it can be distinguished into four distinct zones from periphery to centre of the pulp as shown in Figure below. The zones are as following:

- A. Odontoblastic layer at the pulp periphery:** Odontoblasts consists of cell bodies and cytoplasmic processes.
- B. Cell free zone of Weil:** Central to odontoblasts is sub-odontoblastic layer, it contains plexuses of capillaries and small nerve fibres
- C. Cell rich zone:** It contains fibroblasts, undifferentiated cells which maintain number of odontoblasts by proliferation and differentiation
- D. Pulp core:** It contains large vessels and nerves from which branches extend to peripheral layers.



**Contents of the pulp**

- I. Cells
  - 1. Odontoblasts
  - 2. Fibroblasts
  - 3. Undifferentiated mesenchymal cells
  - 4. Defense cells - Macrophages  
Plasma cells  
Mast cells
- II. Matrix
  - 1. Collagen fibers - Type I  
Type II
  - 2. Ground Substance - Glycosaminoglycans  
Glycoproteins  
Water
- III. Blood Vessels - Arterioles, Venules, Capillaries
- IV. Lymphatics - Draining to submandibular, submental and deep cervical nodes
- V. Nerves - Subodontoblastic plexus of Raschkow  
Sensory afferent from Vth nerve and Superior cervical ganglion

Figure 1. Zones of pulp

**ANATOMY OF DENTAL PULP**

Pulp lies in the centre of tooth and shapes itself to miniature form of tooth. This space is called pulp cavity which is divided into a pulp chamber and root canal/s starting from the orifice to the apical foramen. There are also accessory and lateral canals. The roof of pulp chamber consists of dentin covering the pulp chamber occlusally. Canal orifices are openings in the floor of pulp chamber leading into the root canals. The shape of root canal varies with size, shape, number of the roots in different teeth.

## FUNCTIONS OF PULP

Pulp performs four basic functions:

1. Formation of dentine
2. Nutrition of dentine
3. Innervation of tooth
4. Defense of tooth

## ROOT CANAL CONFIGURATION

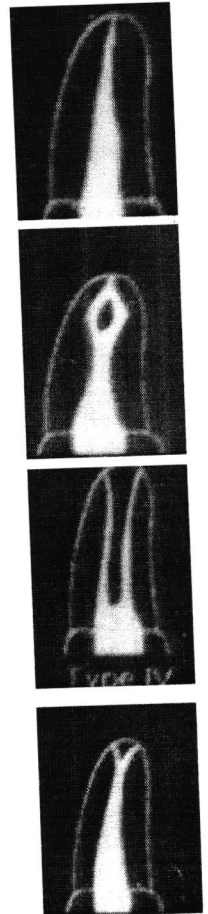
The shape of root canals is divided into four types:

**Type 1:** A single canal leaving the pulp chamber and continuing as a single canal to the root apex and opens in a single apical foramen.

**Type 2:** Two canals leave the pulp chamber then join each other at the apical third to open in a single apical foramen.

**Type 3:** Two canals leave the pulp chamber and continue as two canals to be opened in two separate apical foramina.

**Type 4:** A single canal leaving the pulp chamber, and bifurcating at the apical third into two canals and open in two apical foramina.



## BASIC PHASES OF TREATMENT

There are three basic phases of treatment:

- 1- The Diagnostic phase in which the disease to be treated is "determined" and the treatment plan developed.
- 2- The Preparatory phase in which the contents of the root canal are removed and the canal is prepared to receive a filling material.

3- The obliteration Phase in which the canal is filled or obliterated with an inert material to obtain an adequate seal as close as possible to C.D.J. (cementodentinal junction).

If there is a defect in any phase, the endodontic treatment will not be succeeded.

## **PULP AND PERI-RADICULAR PATHOLOGY**

Etiology of pulpal diseases can be broadly classified into:

### **I. Bacterial irritant**

Bacteria, usually from dental caries, are the main source of injury to the pulpal and periradicular tissues and they enter either directly or through dentine tubules.

Modes of entry for bacteria to the pulp are as follows:

- 1- Through the carious cavity.
- 2- Through the dentinal tubules as in contamination during cavity preparation, through exposed root surface, and surfaces with erosion, abrasion and attrition.
- 3- Through the apical foramen as in advanced periodontitis where microorganisms reach the apical foramen and then the pulp.
- 4- Through the blood stream (anachoresis: it is a process by which microorganisms get carried by the bloodstream from another source localize on inflamed tissue). Following trauma or inflammation to the pulp any bacteria in the blood might be attracted to the pulp causing pulpitis.
- 5- Through faulty tooth restoration.
- 6- Through extension of a periapical infection from adjacent infected tooth.

Bacteria most often recovered from infected vital pulps are:

- Streptococci
- Staphylococci
- Diphtheroids, etc.

### **II. Mechanical irritants**

Examples of mechanical irritation include trauma, operative procedures, excessive orthodontic forces, subgingival scaling and overinstrumentation using root canal instruments.

### **III. Chemical irritants**

Pulpal irritation may result from bacterial toxins or some restorative materials/conditioning agents. Peri-radicular irritation may occur from irrigating solutions, phenol-based intra-canal medicaments or extrusion of root canal filling materials.

### **IV. Radiation injury to pulp**

Radiation therapy affect pulps of fully formed teeth in patients exposed to radiation therapy. The pulp cells exposed to ionizing radiation may become necrotic, there may occur vascular damage and the interference in mitosis of cells.

### **Classification of Pulp Disease**

Diagnosis of pulp disease is usually based on patient symptoms and clinical findings. Pulpal disease may result in changes to both the soft and hard tissues.

#### **Soft tissue changes**

***Reversible pulpitis (Pulpal Hyperaemia)***:It is a transient condition that may be precipitated by any insult (ex. caries) to the pulp and characterised by increase in vascular vasodilation.

The symptoms are usually:

- Pain needs an external stimulus and it subsides immediately after removal of stimulus.
- Pain is difficult to localise (as the pulp does not contain proprioceptive fibres).
- Normal periradicular radiographic appearance.
- Teeth are not tender to percussion but sensitive to cold stimulus.

Treatment involves covering up exposed dentine, removing the stimulus or dressing the tooth.

***Irreversible pulpitis***:Irreversible pulpitis usually occurs as a result of more severe insults than in the reversible pulpitis. It may develop as a progression from a reversible state.

1) Acute pulpitis.The pulp experiences increased inflammatory process and intrapulpal pressure. The symptoms experienced are:

- Severe pain develops spontaneously or from stimuli which may last from minutes to hours.

- Heat stimulus increases pain due to expansion of blood vessels therefore increasing pressure in the pulp.

- Cold stimulus decreases pain due to contractile action on the blood vessels therefore lowering intrapulpal pressure

- Not tender to percussion and normal radiographic apical region.

- a widened periodontal ligament may be seen radiographically in the later stages.

Treatment involves either root canal therapy or extraction of the tooth.

2) Chronic pulpitis. After the acute phase the pulp might enter the chronic phase. The symptoms experienced are:

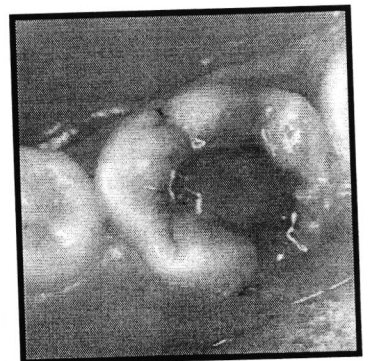- Mild to moderate intermittent pain may be tolerated by the patient for long period of time.

- Thermal tests are of little value.

- Tenderness to percussion and radiographic changes are not seen until infection reaches the periapical region.

Treatment involves either root canal therapy or extraction of the tooth.

**Hyperplastic pulpitis:** Hyperplastic pulpitis is a form of irreversible chronic pulpitis and is also known as a **pulp polyp**. It occurs as a result of proliferation of chronically inflamed young pulp tissue. Treatment involves root canal therapy or extraction.



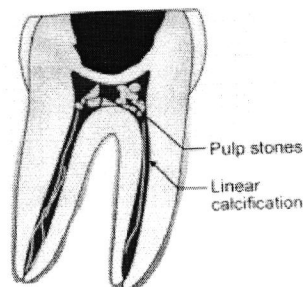
**Pulp necrosis:** Pulp necrosis occurs as the end result of irreversible pulpitis; treatment involves root canal therapy or extraction.

### Hard tissue changes

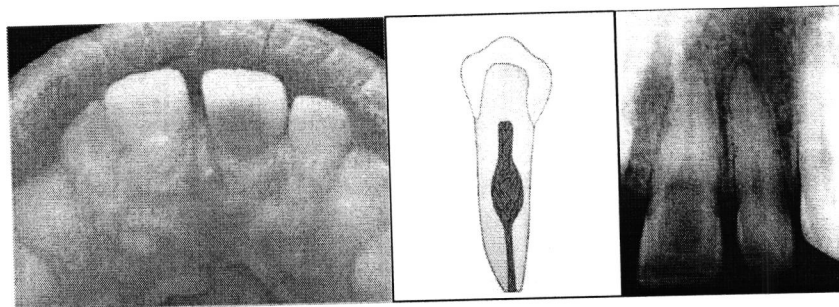
**Pulp calcification:** Physiological secondary dentine is formed after tooth eruption and the completion of root development. It is a condition in which hardening, or calcification, of pulp tissue results in hypersensitivity and extreme pain because the dental nerves become compressed. A root canal is usually necessary to clear away hardened tissue. Pulp calcification is deposited on the floor and ceiling of the pulp chamber rather than the walls and with time can result in occlusion of the pulp chamber. Pulp calcification may be composed of irregular dentine (true denticle) or due to ectopic calcification of pulp tissue (false denticle). Tertiary dentine is laid down in response to environmental stimuli as



reparative dentine where it is deposited directly beneath the path of injured dentinal tubules as a response to strong noxious stimuli. Treatment is dependent upon the pulpal symptoms.



**Internal resorption:** Internal resorption is initiated within the pulp cavity and results in loss of substance from dentinal tissue. Occasionally, pulpal inflammation may cause changes that result in dentinoclastic activity. Such changes result in resorption of dentine; clinically, a pink spot may be seen in the later stages if the lesion is in the crown. Radiographic examination reveals a radiolucency that is seen to be continuous with the rest of the pulp cavity. Root canal therapy will result in arrest of the resorptive process; however, if destruction is very advanced extraction may be required.



### **Who performs an endodontic therapy?**

Generally, all dentists receive basic education in endodontic treatment but an endodontist is preferred for endodontic therapy. General dentists often refer patients needing endodontic treatment to endodontists.

### **Why does patient Feel Pain?**

When pulp becomes infected, it causes increased blood flow and cellular activity, and pressure cannot be relieved from inside the tooth. This causes pain. Pulp can even die without causing significant pain; it may depend on pain threshold and pain reaction of the patient.

### **How can You Tell if Pulp is infected?**



When pulp gets inflamed, it may cause toothache on taking hot or cold, spontaneous pain, pain on biting or on lying down. On occasion a damaged pulp is noticed by drainage, swelling, and abscess at the root end (Fig. 2). Sometimes, however, there are no symptoms.

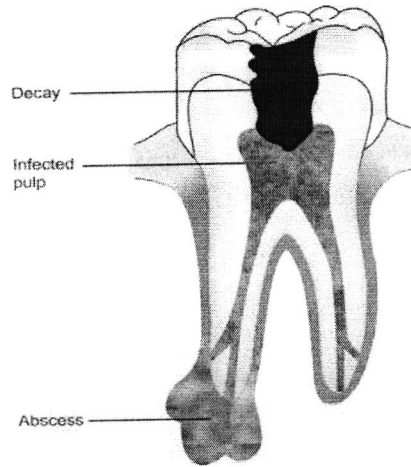


Figure 2. Tooth with infected pulp and abscess formation

### **Why does patient Need Root Canal Therapy?**

Because tooth will not heal by itself, the infection may spread around the tissues causing destruction of bone and supporting tissue. This may cause tooth to fall out. Root canal treatment is done to save the damaged pulp by thorough cleaning and shaping of the root canal system and then filling it with gutta-percha (rubber like) material to prevent recontamination of the tooth. Tooth is permanently restored with crown with or without post.

### **What are Alternatives to Root Canal Therapy?**

If tooth is seriously damaged and its support is compromised, then extraction is only alternative.

### **What is Root Canal Treatment Procedure?**

Once the endodontic therapy is recommended, your endodontist will numb the area by injecting local anesthetic. After this a rubber sheet is placed around the tooth to isolate it. Then the opening is made in the crown of the tooth and very small sized instruments are used to clean the pulp from pulp chamber and root canals (Fig. 2). After thorough cleaning and shaping of root canals (Fig. 3), they are filled with rubber like material called gutta-percha, which will prevent the bacteria from entering this space again (Figs 4 and 5). After

completion of endodontic therapy, the endodontist places the crown or other restoration so as to restore the tooth to full function (Fig. 6).

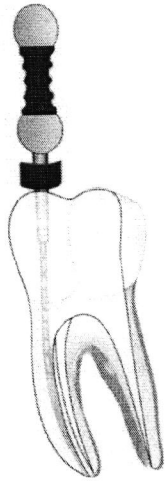


Figure 2. Cleaning and shaping of root Canal system

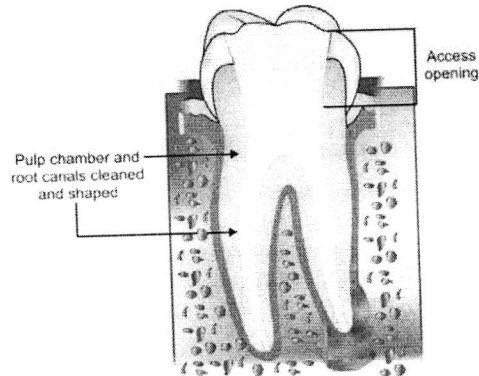


Figure 3. Cleaned and shaped tooth

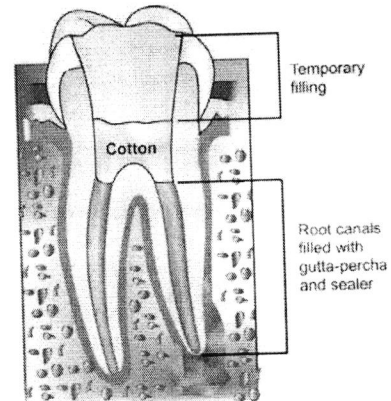


Figure 4. Obturation of root canal system

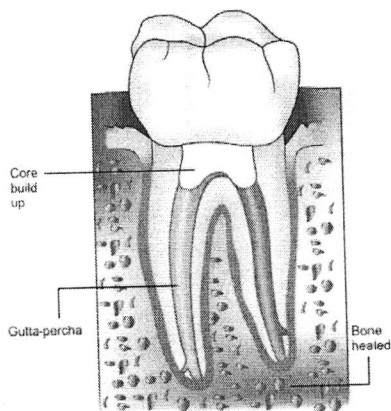


Figure 5. Complete restoration of tooth with crown placed over the restored tooth

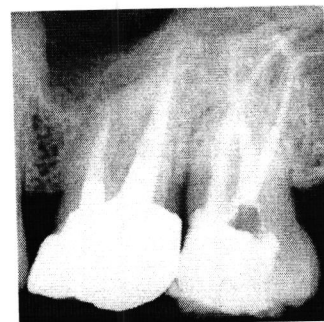


Figure 6. Complete root canal treatment

### Will the Tooth Need Any Special Care or Additional Treatment after Endodontic Treatment?

Patient should not chew or bite on the treated tooth until the patient has had a tooth restored by the dentist. The non-restored tooth is susceptible to fracture, so patient should visit the dentist for a full restoration as soon as possible not more than one month. Most endodontically treated teeth last as long as other natural teeth. In a few cases, a tooth that has undergone endodontic treatment does not heal or the pain continues. Occasionally, the tooth may become painful or diseased months or even years after successful treatment. Often when this occurs, re-treating the endodontic procedure can save.

### **Can All Teeth be Treated Endodontically?**

Most of the teeth can be treated endodontically. But sometimes when root canals are not accessible, root is severely fractured, tooth cannot be restored or tooth doesn't have sufficient bone support, it becomes difficult to treat the tooth endodontically. However, advances in endodontics are making it possible to save the teeth that even a few years ago would have been lost. Newer researches, techniques and materials have helped us to perform the endodontic therapy in better way with more efficiency. Since introduction of rotary instruments and other technologies reduce the treatment time, the concept of single visit is gaining popularity nowadays. It has been shown that success of endodontic therapy depends on the quality of root canal treatment and not the number of visits. In the modern world, single visit endodontics is becoming quite popular.