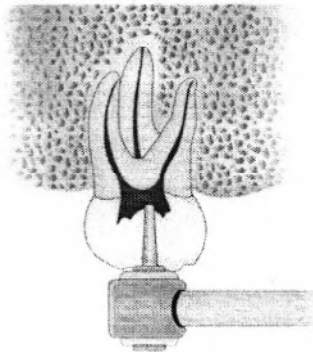


## ENDODONTICS

### Access Opening Preparation


#### Guidelines for access cavity preparation:

- 1) Study the preoperative radiograph: It gives information about the size, shape, number and curvature of the root canals and roots. One should check the depth of preparation by aligning the bur and handpiece against the radiograph.

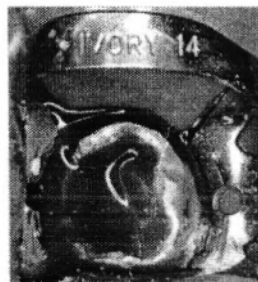

Preoperative radiograph can help to note the position and depth of pulp chamber

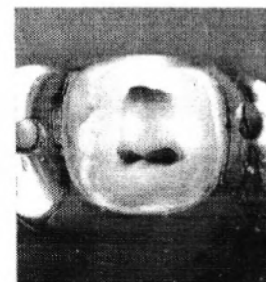
- 2) Excavate all the carious lesions: No caries should be left in the tooth, because microorganisms of the carious lesion may be introduced inside the canal and infection might occur.
- 3) Replace any defective filling: The defective filling should be replaced before beginning the access opening because it will not ensure proper seal of the tooth.
- 4) Remove unsupported tooth structure: Any weak tooth structure might fracture that causes loss of the seal of the tooth and the reference point which changes the length of the tooth.



2.40 Gross caries




2.41 Carious exposure with hyperaemic pulp




2.42 Pulp extirpated and canals prepared

### Burs used for access cavity preparation

Access opening burs: they are round burs with 16mm bur shank (3mm longer than standard burs).



Access refining burs: these are coarse flame-shaped, tapered round and diamonds for refining the walls of access cavity preparation

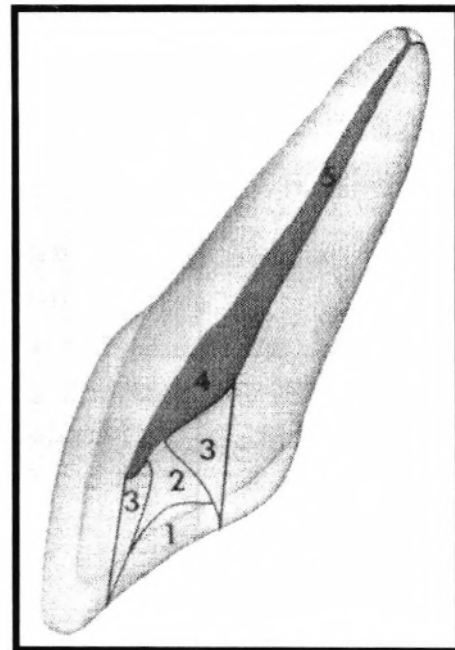


### Procedure of Access Opening for Anterior Teeth:

- 1) Entrance is always gained through the lingual surface of all anterior teeth. The initial penetration is prepared in the exact center of the tooth above the cingulum (in the center of the middle third).
- 2) The initial entry in the enamel is done by a round bur no. 4 operated at a right angle to the long axis of the tooth. The guide for enamel penetration is that only the head of the round bur no. 4 should enter the tooth.

The direction of the bur is changed to be parallel to the long axis of the tooth, and drill until the entrance to the pulp chamber. We can know that we reached the pulp chamber when we feel a fall in the resistance to the bur, i.e. the bur falls into a space which is the pulp.

- 3) Remove the roof of the pulp chamber by working from inside the chamber towards the outside of the chamber (pulling motion).
- 4) Lingual shoulder is removed by moving the bur from inside towards the outside to give a continuous smooth flaring preparation. Lingual shoulder is a convexity inside the pulp chamber.



- 5) Finishing and funneling with a fissure bur. The final shape funnels down to the orifice of the canal and flare outwards.
- 6) Extirpate the pulp by introducing an instrument called the barbed broach in the root canal and by outward movement the barbed broach will catch the pulp and remove it from the root canal.
- 7) Irrigation of the pulp chamber.

The pulp horns should be eliminated with a round bur no. 2 used laterally and incisally, because if they remain, remnants of necrotic tissue would cause discoloration to the anterior teeth.

#### **Procedure of Access Opening for Premolars:**

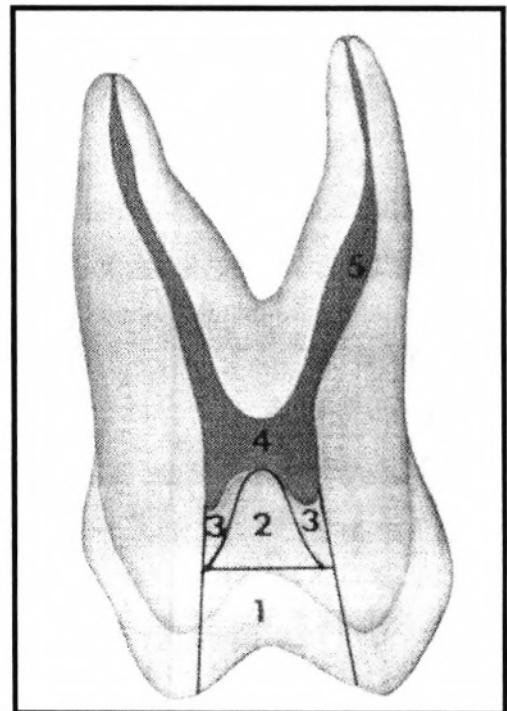
- 1) Access is always gained through occlusal surface of all posterior teeth at the center of the central groove. Initial penetration is made parallel to the long axis of the tooth into the exact center of the central groove.
- 2) A round bur no. 2 or 4 is used to open into the pulp chamber. The bur will be felt to drop if the pulp is reached.
- 4) We extend into the cavity bucco-lingually by removing the roof of the pulp chamber, working from inside the cavity to the outside (pulling motion).
- 5) Finishing the cavity walls is done with a fissure bur.

The final access opening would be ovoid in shape buccolingually which reflects the anatomy of the pulp chamber and position of the buccal and lingual canal orifices.

\* The pulp chamber of the lower premolars is buccally located rather than lingually so we start access opening and push more buccally.

\* Access for upper premolars: There are 2 canals, the buccal canal is approached palatally, and the palatal canal buccally.

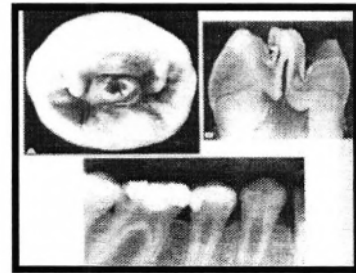
\* Floor of the pulp chamber should not be reached.



### Anomalies of pulp cavities:

We have certain anomalies which interfere with root canal treatment. ex: calcification or complete obliteration of root canal, open apices, etc ...

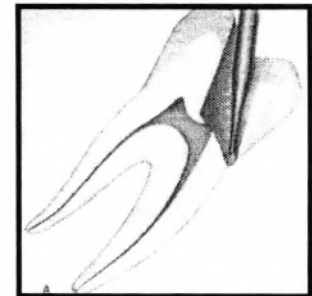
- 1- Dentinogenesis imperfecta: There is a small pulp chamber with root canal obstruction.
- 2- Hyperparathyroidism: There is a calcified pulp chamber and loss of lamina dura.
- 3- Hypofunction of pituitary gland: There is a retarded eruption of the teeth and the apices of the root will be opened.
- 4- Dentinal dysplasia: There is an obliteration of the pulp chamber and the root formation is defected.
- 5- Shell teeth: The pulp chamber is quite big with short root.
- 6- Dense invagination: There is an improper shape of root canal.



### Errors in Access Opening:

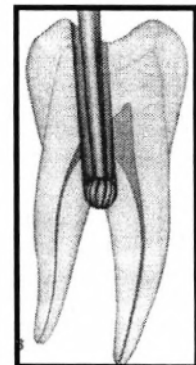
1- **Perforation**: It is common when drilling is continued apically or laterally after we reach the pulp chamber. It is mostly seen in:

- a) Old patients. It is due to pulp recession.
- b) Teeth restored by crowns, inlays or big restorations. It is difficult to know the long axis of the tooth so it is better to remove the restoration and work.
- d) Tilted teeth.
- e) Failure to complete a convenient extension.



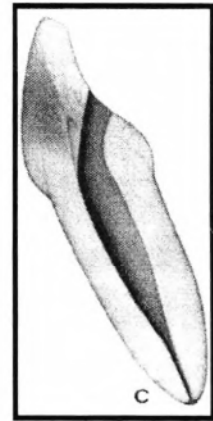
2- **Cutting more apically**: It will lead to flattening of the floor of the pulp chamber and this will weaken the tooth structure which will cause:

- a) Losing the funneling shape of the canal orifice.
- b) Perforation into the furca.
- c) Gouging: Going laterally in the access opening, so the wall of the cavity will not continue with the wall of the root canal.

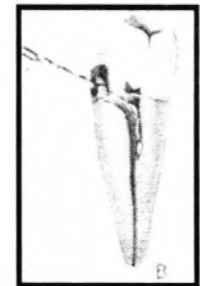


3- **Narrow access opening**. This will cause incomplete pulp extirpation and instrumentation through the pulp chamber or pulp horn. This is identified by:

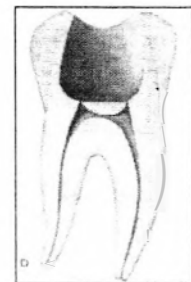
- a) Sever bleeding.
- b) Change of the colour of the floor dentin, to dark blue.
- c) Anatomical landmarks of the floor of pulp chamber, which are convex floor and presence of grooves connecting the canal orifices, are not seen clearly.
- d) If a probe is placed in the pulp chamber and pulled against the walls and it catches in the pulp chamber then there is still roof of the pulp chamber, therefore indicating presence of remnants of pulp tissue.



4) **Entrance through labial surface**. This is sometimes performed due to severe crowding or caries in labial surface, or proximal surface if the adjacent tooth is missing. This type of access opening causes incomplete pulp extirpation.



5) **Over extended access opening preparation**. This access opening causes undermining and weakening of the enamel walls.

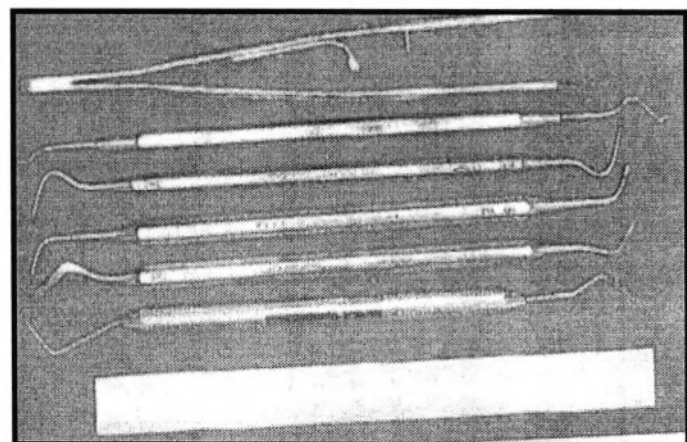


## **Endodontic Instruments:**

There are many instruments used in the different phases of endodontic treatment and they are as follows:


### **General Instruments**

- 1) Endodontic explorer: A double end instrument, one end is straight used to locate the root canal orifices after the removal of the pulp chamber, and the other end is L-shaped which aids in detecting the unremoved parts of the tooth

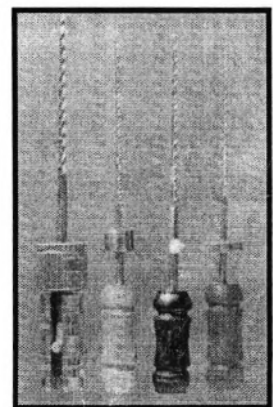


as the roof of pulp chamber.

- 2) Plastic instruments: It has two ends; the first is used to carry temporary filling material. The opposite end is used as a plugger to condense cement and base materials in the root canal.
- 3) Endodontic excavator: It is larger than a spoon excavator, used to allow excavation of the contents of the pulp chamber. It is also used in curettage of periapical lesions in surgical endodontics (apicectomy).
- 4) Endodontic locking pliers (tweezer): It has a lock that allows materials to be held without continuous finger pressure; also it has a groove which facilitates holding gutta percha and absorbing points.
- 5) Endodontic ruler: It is a metal ruler made of 0.5mm divisions. It is a convenient instrument to measure reamers, files and gutta percha.
- 6) Endodontic syringe: It is used to carry irrigating solution into the root canal. The tip of the instrument is flat to prevent penetration of the needle to the small canals; also it has a groove in its tip to permit the irrigation which might be under pressure to flow coronally rather than forcing it to the apical foramen causing post-operative pain.
- 7) Instrument organizer (endodontic kit): It is used for arrangement of reamers and files according to the size and length. The organizer provides holes for the files to be placed vertically in a sponge which is saturated with disinfectant to maintain its sterility.



- 8) Transfer sponge: It is sponge saturated with disinfectant solution. The reamers and files can be placed in it after being used.
- 9) Instrument stopper (rubber stopper): It is used to mark the length of the tooth on reamers and files; it should be perpendicular to the long axis of the reamer. It may be made of rubber or metal.




### **Intracanal Instruments:**

These instruments are used inside the root canal



### 1) Barbed broach.

This instrument is used inside the canal. It is a short handled instrument with a shaft having projections directed obliquely towards the handle. It is made of stainless steel, and used for pulp (vital pulp) extirpation, and removal of necrotic tooth debris inside the canal. It can be used to remove



cotton and paper points from the canal. It is used in straight parts of the canal and inserted freely (by using the suitable size) to the 2/3 of the pulp canal; otherwise, fracture of the instrument may occur.

**Technique of pulp extirpation (Healey, 1984)**

Penetrate the barbed broach along the canal wall towards the apex

U

As it reaches to the apical constriction, move it into the center of mass of pulp tissue

U

Rotate the broach several times in a watch winding manner to entrap the pulp which is then withdrawn from the canal


### 2) K-Reamers and K-files.

These instruments are made of stainless steel, because it is more flexible than carbon steel and don't corrode, but nowadays, a super flexible material which is nickel-titanium is used. Reamers and files are manufactured by twisting a square bar to produce flutes but they differ in the number of flutes.

(a) Reamers are mostly used in reaming action and are less effective in filing action. Reamer = 0.5-1 flute/mm.




b) Files are less flexible than reamers. It is mostly used in filing action but can be used in reaming action. K file = 1.5-2.25 flute/mm,




7.138

7.138-7.140 Kerr K-file No. 25




7.139



7.140

(c) K flex file: It is a diamond cross section bar. It is more flexible and has sharper blades with non-cutting tip (blind tip).



7.144

7.144-7.146 Kerr K Flex file No. 25




7.145



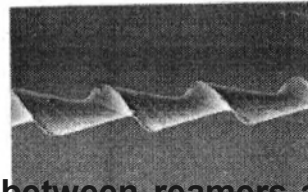
7.146

(d) Hedstrom files: They are machined instrument that are made of stainless steel bar which are triangular in shape with very sharp edges. They are very active in just pulling action while K files are effective in both pulling and pushing action. It can not be used in rotation movement.




7.157

7.157-7.159 Hedstrom No. 25



7.158



7.159

### Differences between reamers and files

Reamer	File
1- More flexible.	Less flexible.
2- Less no. of cutting flutes	More no. of cutting flutes
3- Used mainly in reaming action.	Used mainly in filing action.
4- Less effective in filing action because less no. of flutes.	Rotation Can be used in reaming action.
5- cutting motion is rotation and retraction	Push pull in filing action.
6- Cross section is Triangular	Square Can be used in reaming action.
7. Round preparation shape	Ovoid

**Note:** Triangular cross-sectioned files show superior cutting and increased flexibility than the file or reamers with square blank

Note: Triangular cross-sectioned files show superior cutting and increased flexibility than the file or reamers with square blank.

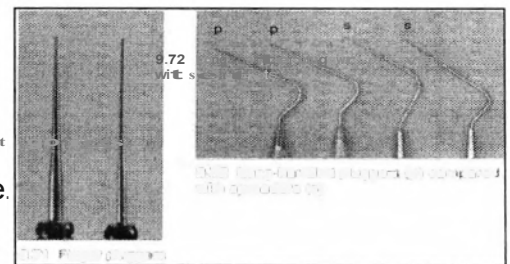



### 3) Spreader.

It is a long, tapered and pointed end instrument, which is used to compress gutta percha into the apex and periphery of the prepared canal and also towards the irregularity of canals leaving a space for insertion of auxiliary root canal filling material cones. There is also a finger spread and long handled which is smaller and shorter to be used in posterior teeth.

### 4) Plugger

It is a long and blunt flat tip blade instrument. It is necessary for vertical condensation technique and also plugging of gutta-percha at the termination of all other obturation condensation techniques. There are 2 types of pluggers, the long handled type and finger type.



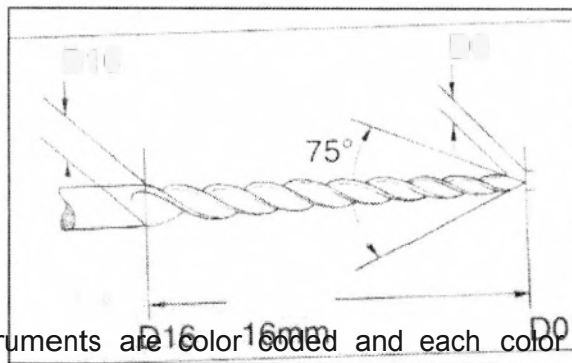
### Standardization of Intracanal Instruments:

Each instrument has a number which refers to the size of its tip. The reamer of size 30 means that  $D_o = 0.3\text{mm}$ , while size 70 reamer means that  $D_o = 0.7\text{mm}$ .

$$D_{re} = D_o + 0.32 \text{ mm}$$

So in size 50 reamer, the tip ( $D_a$ ) is 0.5 mm while  $D_{re}$  is 0.82 mm. The distance between  $D_a$  and  $D_e$  is 16mm, but the total length differs from short to medium to long for anterior teeth, and the shorter ones for posterior teeth.

$$D_{16} \qquad \qquad \qquad D_o$$



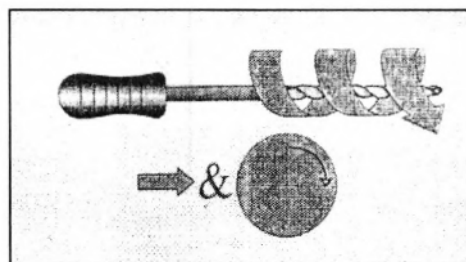
All intracanal instruments are color coded and each color represents a size. Pink= 6, Gray= 8, Purple= 10, White= 15, Yellow= 20, Red= 25, Blue= 30, Green=

All intracanal instruments are color coded and each color represents a size. Pink= 6, Gray= 8, Purple= 10, White= 15, Yellow= 20, Red= 25, Blue= 30, Green=


35, Black= 40, then the colour returns to White= 45, and so on to Blue= 60 and then the instruments increase by 10 as Green=?0, Black=80, and so onto size 140.

**Modes of action of Intracanal Instruments:**

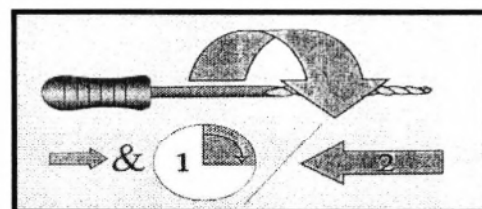
1) **Reaming action:** It is a repeated clockwise rotation of the instrument which will shave the canal walls and give a cross sectional preparation approximately round. Reamers are usually more effective for this function.



2) **Filing action:** It is a push-pull action without rotation which has a great efficiency with files than reamers. The cross sectional appearance of the prepared root canal is irregular with general oval configuration, so the canal must be filled with gutta percha.



3) **Quarter-turn filing:** This action is a combination of reaming and filing action. The instrument is inserted in the root with a quarter turn rotation (90°) then moved with dragging motion to produce an oval cross section. K-file and reamer can be used.



4) **Circumferential filing:** in this action, filing or quarter turn filing action is used with emphasis placed on the out stroke, so the file is dragged along different sides of the canal wall with each withdrawal. The resultant canal has a wide orifice with greater taper.